

## Case Report

# A case of spleen hydatid cyst

Yasser El Brahmī\*, Mohamed Anajjar, Mohammed Rebbani, Abdelkader Ehirchiou,  
Abdelmounaim Ait Ali

Department of Visceral surgery II, Military Hospital Mohammed V Rabat, Rabat, Morocco

**Received:** 06 July 2020

**Revised:** 07 August 2020

**Accepted:** 14 August 2020

**\*Correspondence:**

Yasser El Brahmī,

E-mail: [yasserelbrahmi@gmail.com](mailto:yasserelbrahmi@gmail.com)

**Copyright:** © the author(s), publisher and licensee Medip Academy. This is an open-access article distributed under the terms of the Creative Commons Attribution Non-Commercial License, which permits unrestricted non-commercial use, distribution, and reproduction in any medium, provided the original work is properly cited.

### ABSTRACT

The hydatid cyst of the spleen results from the development of the hydatid worm *Echinococcus granulosus*, in the splenic parenchyma. Humans are the accidental intermediate host in the development cycle of hydatid disease. Splenic involvement is the third most common location after the liver and lung. Echography and sometimes tomography are needed to confirm the diagnosis. In the absence of truly effective medical treatment, splenic hydatidosis often leads to surgery. Resection of the protruding dome is the treatment of choice due to low morbidity and absence of mortality. We report the case of 27 years old, with no particular medico-surgical history, referred to our hospital for the treatment of a splenic hydatid cyst discovered fortuitously during a radiological assessment. The patient was operated by laparoscopy. The treatment consisted of sterilization of the contents of the cyst with hydrogen peroxide, removal of the contents and resection of the salient dome, the results were unremarkable.

**Keywords:** Hydatid cyst, Spleen, Conservative treatment

### INTRODUCTION

Hydatid cyst is an endemic condition, particularly in mediterranean countries, including Morocco. The most frequent localizations are the liver and the lung. Splenic localization represented approximately 4% of the abdominal localizations for hydatidosis.<sup>1</sup> It makes a diagnostic and therapeutic challenge.

Surgery is the treatment of choice, often conservative, and sometimes associated with albendazole, but some authors defend the total splenectomy.

The choice between radical or conservative surgery remains difficult given the constraints of each and the diversity of clinical situations.

We report a case of the splenic hydatid cyst, that we operated laparoscopically adopting a conservative attitude.

### CASE REPORT

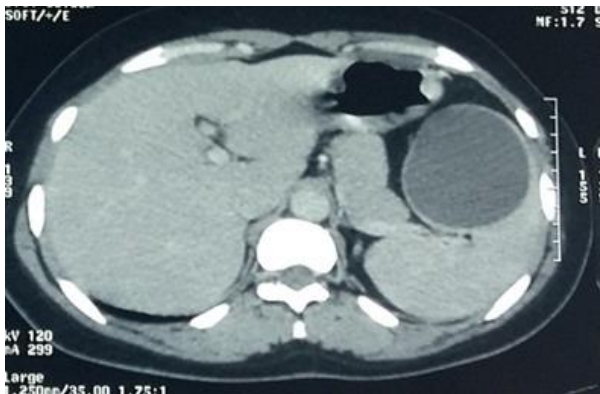
A 27 years old male, with no particular medico-surgical history, referred to our hospital for the treatment of a splenic hydatid cyst discovered fortuitously during a radiological assessment.

The abdominal ultrasound and the abdominal-pelvic computed tomography retained the diagnosis of a hydatid cyst of spleen, staged stage 1 of Gharbi classification, measured 61×72 mm (Figure 1).

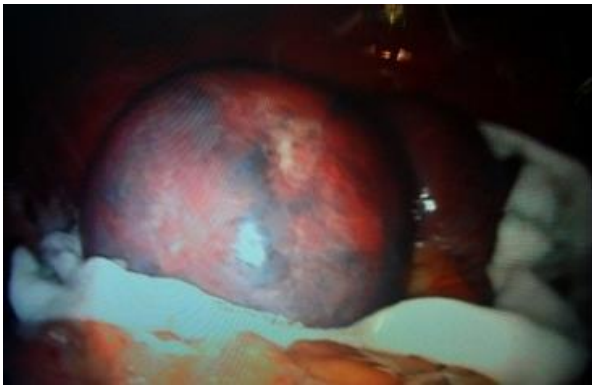The hydatid serology was negative. On examination, general condition was preserved. Abdominal examination found a flexible belly without a palpable mass.

Expected a high level of platelets calculated at 473,000/mm<sup>3</sup>. The blood investigations showed no anomaly.

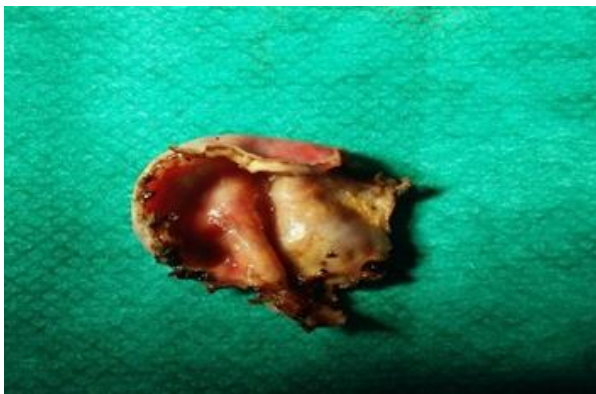
The patient was operated by laparoscopy. The treatment consisted of sterilization of the contents of the cyst with hydrogen peroxide, removal of the contents and resection of the salient dome (Figure 2 and 3).



**Figure 1: The abdominal-pelvic computed tomography.**



**Figure 2: Intra-operative image.**



**Figure 3: The salient dome.**

After resection of the protruding dome and verification of the cavity vacuum, hemostasis of the cyst is performed and a drain is placed in the residual cavity.

The operative suites were unremarkable. The patient was put on albendazole 400 mg. No problems were reported after one year of follow-up.

## DISCUSSION

The hydatid cyst (HC) of the spleen results from the development of the larva *Echinococcus granulosus* in the splenic parenchyma. All the locations of this hydatidosis have been described HC is thus localized most often in the liver and then in the lungs. Splenic localization comes in third.<sup>1</sup> The ways of splenic involvement are diverse, The embryo then crosses the intestinal wall, reaches the liver, by portal to locate it or to reach the lungs by the cave, then any other organ via of systemic circulation. Other pathways have been discussed: contiguous involvement, the lymphatic route and the retrograde portosplenic venous route.<sup>1,2</sup>

Many other parasites can cause splenic damage, most often causing splenomegaly (amoebiasis, bilharziasis, leishmaniasis, trypanosomiasis). The most frequent manifestations are abdominal pain, the discovery of a mass in the left hypochondrium and the incidental discovery as for our patient.<sup>3</sup> Ultrasound (USG), computed tomography (CT) and magnetic resonance imaging (MRI) of the abdomen are the most useful examinations for the diagnosis of the hydatid cyst of the spleen. Combined with hydatid serology, these imaging examinations allow diagnostic confirmation of the hydatid cyst splenic. They also allow the diagnosis of asymptomatic and multi-visceral forms.<sup>4</sup>

Surgery is the cornerstone for the treatment of the hydatid cyst of the spleen. And who must obey the immunological imperatives by trying to conserve the spleen and the parasitic imperatives by treating the cyst. The most appreciated conservative treatment by different surgeons is the evacuation, sterilization and resection of the protruding dome. There are other conservative techniques like partial splenectomy, but it is very hemorrhagic due to the lack of vascular control.

Other authors defend total splenectomy, which has the advantage of removing the parasitic organ, avoiding recurrences and complications related to the residual cavity, but this technique seems less legitimate especially for a benign pathology. This should lead to reserving this attitude for multiple cysts, those sitting on a pathological spleen, central hilar and intra-parenchymal cysts, and in case of multiple cysto-visceral adhesions.<sup>5,6</sup>

The approach depends on the location of the splenic hydatid cyst, and on association with other cystic locations. The laparoscopic approach is feasible for almost all cases allowing a marked reduction in therapeutic morbidity.<sup>7</sup> Albendazole medical treatment is used for multi-visceral forms and as an adjunct to surgical treatment.

Hydatidosis can only disappear thanks to strict prophylactic measures based on the health education of the populations, the veterinary control of the slaughter of cattle, systematic euthanasia of stray dogs, and the

treatment of domestic dogs, Vaccination of domestic intermediate hosts with a vaccine (EG-95 vaccine) obtained by genetic engineering is being evaluated.

## CONCLUSION

In the absence of truly effective medical treatment, splenic hydatidosis often leads to surgery. Resection of the protruding dome is the treatment of choice due to low morbidity and absence of mortality. The use of splenectomy should only be done in special situations. Laparoscopy would be another step towards reducing therapeutic morbidity.

*Funding: No funding sources*

*Conflict of interest: None declared*

*Ethical approval: Not required*

## REFERENCES

1. Abi F, El Fares F, Khaiz D, Bouzidi A. Les localisations inhabituelles du kyste hydatique: à propos de 40 cas. J Chir. 1989;126:307-12.
2. Morgenstern L. Non parasitic splenic cysts: pathogenesis, classification and treatment. J Am Coll Surg. 2002;194:306-14.
3. Aportas D, Polymeneas G. Two cases of primary splenic hydatid cyst in Greece. Korean J Parasitol. 2012;50(2):147-50.
4. Schmutz G, Fournier L, Hue S, Salame E, Chiche L. Imagerie de la rate normale et pathologique. In: Encycl Méd Chir (Elsevier, Paris), Radiodiagnostic-Appareil digestif. 1999;33:605(A):10.
5. Fingerhut A, Etienne JC. Chirurgie conservatrice de la rate. Encycl. Méd. Chir. (Elsevier, Paris), Techniques chirurgicales-Appareil digestif. 1995;40(751):10.
6. Quandalle P, Rousseau B, Mascout A, Wurtz A. La splénectomie partielle dans les lésions bénignes non traumatiques de la rate. J Chir. 1987;124:326-30.
7. Gharaibeh KI. Laparoscopic excision of splenic hydatid cyst. Postgrad Med J. 2001;77(905):195-6.

**Cite this article as:** El Brahmi Y, Anajjar M, Rebbani M, Ehirchiou A, Ali AA. A case of spleen hydatid cyst. Int Surg J 2020;7(9):3146-8.