

Case Report

Urachal fistula in a 22 year male: a case report

Vipul Kumar Srivastava*, Shilpi Roy, Ram Niwas Meena, Rahul Khanna

Department of General Surgery, Institute of Medical Sciences, BHU, Varanasi, India

Received: 29 June 2020

Accepted: 06 August 2020

***Correspondence:**

Dr. Vipul Kumar Srivastava,

E-mail: vipulsrivastava1992@gmail.com

Copyright: © the author(s), publisher and licensee Medip Academy. This is an open-access article distributed under the terms of the Creative Commons Attribution Non-Commercial License, which permits unrestricted non-commercial use, distribution, and reproduction in any medium, provided the original work is properly cited.

ABSTRACT

A patent urachus is one of the spectrums of congenital urachal anomalies. It has been termed as "urachal fistula" when the lumen of intra-embryonic portion of allantois persist abnormally. Persisting urachal fistula is a rare condition mostly diagnosed during childhood or in autopsies. Here we report a very rare case of urachal fistula of a young male. We present a case of 22 years male with intermittent periumbilical pain and sero-purulent discharge from umbilicus since birth. On examination sero-purulent discharging umbilical sinus with granuloma was present. Surgical excision of whole of the urachal fistulous tract was done with repair of bladder. Patient did well during post-operative period. Persisting urachal fistula in adult is rare entity and difficult to diagnose because of low incidence and non-specific symptoms. So a high index of suspicion is required in order to make the early diagnosis of urachal anomalies.

Keywords: Urachus, Urachal Fistula, Allantois, Umbilical sinus

INTRODUCTION

The urachus is a fibrous cord arising from the early fetal anterior bladder wall to the allantois, extending cranially to the umbilicus. It undergoes many developmental changes during embryonic life and finally descends along with the bladder in pelvis. This descent stretches the urachus leading to the obliteration of its lumen and the formation of a fibrous band known as the median umbilical ligament.¹ Failure of obliteration of this leads into formation of various urachal abnormalities.

Congenital urachal remnants can be further subdivided into five groups: patent urachus, umbilical-urachal sinus, vesicourachal diverticulum, urachal cyst, and alternating sinus.² Mostly these anomalies remain asymptomatic except for the patent urachus also known as urachal fistula which is a rare condition to find. Even if they are found then they are usually seen in newborns or often on autopsies.

So we present this extremely rare case of a symptomatic urachal fistula in a 22 year male.

CASE REPORT

A 22 year male presented to General Surgery OPD of Sir Sunderlal Hospital, Institute of Medical Sciences, Banaras Hindu University, Varanasi, Uttar Pradesh, India, with intermittent peri umbilical pain and discharge from umbilicus since birth. The pain was mild grade, dull aching in nature not associated with any postural variation. On examination a sero-purulent discharging sinus was found in the umbilicus and induration was extending 2 cm below umbilicus in midline. There was a 0.5×0.5 cm granuloma protruding out from umbilicus below which sinus opening was situated. The patient was given oral antibiotic (amoxicillin and clavulanic acid) for seven days along with anti-inflammatory drugs. After 1 week we planned for surgical excision of granuloma and sinus.

Surgical excision under local anaesthesia was started and during the surgery it was found to have communication to the deeper plane. Since patient was complaining of pain so spinal anaesthesia was given and procedure was restarted. Layers of anterior abdominal wall were opened gradually along the sinus tract and sheath was opened to expose the

peritoneum. Upon exploration of peritoneum and extra peritoneal tissue it was found that this sinus was attached to urinary bladder (Figure 1a and b). By now it was evident to be a case of urachal fistula so to confirm that we did methylene blue dye test. A Foley's catheter was placed per urethrally and methylene blue dye was injected into the sinus opening at umbilicus. After sometime the dye was seen in the catheter confirming the patent urachus. Now distal part of fistulous tract attached to bladder was excised and bladder rent was repaired in two layers. Specimen was taken out and abdomen was closed. Catheter was left for 2 weeks. Patient did well during postoperative period. Histopathology of the specimen did not show any malignant pathology.

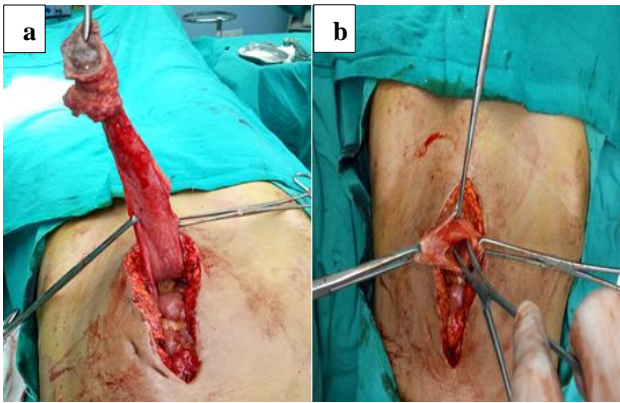


Figure 1: (a) and (b) Intraoperative photograph of patient showing tubular structure connecting umbilicus and urinary bladder-urachal fistula.

DISCUSSION

The persistence of the urachus was first described and treated in 1550 by Cabrolus as mentioned by Begg.³ The urachus is an embryological remnant situated in lower midline of the abdomen within the retro pubic space of retzius. It connects the anterior dome of the bladder to the umbilicus but normally it is obliterated to form median umbilical ligament. Collectively, the urachus is formed by remnants of the cloaca and the allantois and so their remnants are formed due to incomplete regression of the intra-embryonic connection between them.^{4,5} Urachal anomalies can be due to either congenital or acquired causes. Congenital causes can be further subdivided into: patent urachus, umbilical-urachal sinus, vesicourachal diverticulum, urachal cyst, and alternating sinus.² While acquired urachal remnant diseases are classified into two groups: infections and neoplasms.⁶ Among the congenital urachal anomalies except patent urachus the remaining four anomalies may close at birth but can reopen after pathological conditions and therefore may be classified as acquired urachal remnant diseases. The patent urachus is purely congenital. It is frequently symptomatic pre- and post natally.⁷ Most of the patients have urinary leakage from the umbilicus.

The incidence of patent urachus is 3 in 1,000,000 live births and is even rare in adults.⁸ Also patent urachus are seen more commonly in men. In our case the patient had presented in his adulthood which may be due to small lumen of urachus which was patent.⁹ Mostly the patient presents with umbilical discharge and its complications like infection, urinary tract infection, umbilical cellulitis, intraperitoneal rupture, bowel fistulae, bleeding and most severe the neoplastic lesions due to chronic inflammation. So any case of patent urachus or urachal fistula must be taken care of as otherwise may lead to formation of malignant tumors. Due to the low incidence and heterogeneous presentation most often they are misdiagnosed as appendicitis, Meckel's diverticulitis, urinary tract infection, pelvic inflammatory disease, and bladder carcinoma.¹⁰ Computed tomography scan remains the investigation of choice for suspected cases while longitudinal ultrasound, indigocarmine dye discharge test or fistulography are other means to diagnose the disease.¹¹

In our case also the diagnosis was uncertain and we operated the patient thinking that it was an infected umbilical sinus but during the course of operation we came to realize that it was a case of patent urachus. The standard care of treatment in these disease must include removal of whole of the tissue. This is due to the fact that inner layer of urachal fistula or sinus contains transitional epithelium which on prolonged inflammation has high chance of transforming into adenocarcinoma.¹²

CONCLUSION

The congenital patent urachus is rare in adults. Further, clinical diagnosis is delayed or ambiguous in these patients due to low incidence and non-specific symptoms. So a high index of suspicion is required in order to make the diagnosis and to prevent subsequent complications. Early detection of urachal anomalies can help optimize an appropriate surgical approach if required and reduce the risk of subsequent development of malignancy.

Funding: No funding sources

Conflict of interest: None declared

Ethical approval: Not required

REFERENCES

1. M. Fode, G.L. Pedersen, N. Azawi. Symptomatic urachal remnants: case series with results of a robot-assisted laparoscopic approach with primary umbilicoplasty. *Scand J Urol.* 2016;50(6):463-7.
2. C.R. Severson. Enhancing nurse practitioner understanding of urachal anomalies. *J Am Acad Nurse Pract.* 2011;23(1):2-7.
3. Ueno T, Hashimoto H, Yokoyama H, Ito M, Kouda K, Kanamaru H. Urachal anomalies: ultrasonography and management. *J Pediatr Surg.* 2003;38:1203-7.
4. Blichert-Toft M, Nielsen OV. Congenital patent urachus and acquired variants. *Diagnosis and*

- treatment: review of the literature and report of five cases. *Acta Chir Scand.* 1971;137:807-14.
5. O. Renard, Robert G, Guillot P, Pasticier G, Roche JB, Benhard JC, et al. Benign urachus abnormalities: embryology, diagnosis and treatments. *Prog Urol.* 2008;18(10):634-41.
 6. Ashley RA, Inman BA, Routh JC, Rohlinger AL, Husmann DA, Kramer SA. Urachal anomalies: a longitudinal study of urachal remnants in children and adults. *J Urol.* 2007;178(4):1615-8.
 7. Arlen AM, Smith EA. Disorders of the bladder and cloacal anomaly. *Clin Perinatol.* 2014;41(3):695-707.
 8. Sherman JM, Rocker J, Rakovchik E. Her belly button is leaking: a case of patent urachus. *Pediatr Emerg Care.* 2015;31(3):202-4.
 9. Villavicencio CP, Adam SZ, Nikolaidis P, Yaghmai V, Miller FH. Imaging of the urachus: anomalies, complications, and mimics. *Radiographics.* 2016;36(7):2049-63.
 10. Mrad DK, Ben RS, Zaghbib S, Oueslati A, Gharbi M, Nounira Y. Infected urachal cyst in an adult: a case report. *Urology Case Reports.* 2019;26.
 11. Bertozzi M, Recchia N, Di Cara G, Riccioni S, Rinaldi VE, Esposito S, Appignani A. Ultrasonographic diagnosis and minimally invasive treatment of a patent urachus associated with a patent omphalomesenteric duct in a newborn: a case report. *Medicine (Baltim.)* 2017;96(30):7087.
 12. Musko N, Dobruch J, Piotrowicz S, Szostek P, and Borowka A. Infected urachal cyst in a young adult. *Cent Eur J Urol.* 2014;67(2):199-201.

Cite this article as: Srivastava VK, Roy S, Meena RN, Khanna R. Urachal fistula in a 22 year male: a case report. *Int Surg J.* 2020;7(9):3102-4.