

Case Report

Primary renal lymphoma: a rare cause of renal mass in pediatric age group: case report and review of literature

Karishma Thakur¹, Sonam Wadhvani¹, Meha Ghodawat¹, Advait Prakash^{2*}, Abhinav Khare¹, Aditya khaitan¹, Sangram Singh², Anuj Malhotra³

¹Department of General Surgery, Sri Aurobindo Medical College and Post graduate Institute, Indore, India

²Department of Paediatric Surgery, Sri Aurobindo Medical College and Post graduate Institute, Indore, India

³Department of Pediatric, Sri Aurobindo Medical College and Post graduate Institute, Indore, India

Received: 16 June 2020

Revised: 20 July 2020

Accepted: 30 June 2020

***Correspondence:**

Dr. Advait Prakash,

E-mail: drprakashadvait@rediffmail.com

Copyright: © the author(s), publisher and licensee Medip Academy. This is an open-access article distributed under the terms of the Creative Commons Attribution Non-Commercial License, which permits unrestricted non-commercial use, distribution, and reproduction in any medium, provided the original work is properly cited.

ABSTRACT

The secondary renal involvement of non-Hodgkin lymphoma is frequently encountered but primary renal lymphoma is extremely rare in children. We hereby present a rare case of primary renal diffuse lymphoma in a 3-year-old girl child who presented with bilateral renal masses. The tumour was initially diagnosed as bilateral Wilms' tumour but on biopsy, it turned out to be non-Hodgkin's lymphoma. Primary renal lymphoma is an aggressive tumour with guarded prognosis. There are a variety of diseases which present as renal masses in children amongst which primary renal lymphoma is extremely rare. This article describes the clinical features and diagnostic features of primary renal lymphoma. Our report highlights the importance of keeping this neoplastic condition under consideration while evaluating children with renal mass. In order to distinguish primary renal lymphoma from other renal tumours, the authors have also described the clinical, imaging and pathological features of various other renal tumours prevalent in children.

Keywords: Renal lymphoma, Haematuria, Bilateral, Renal mass, Paediatric, Renal tumour

INTRODUCTION

Pediatric lymphomas are the third most common childhood malignancy.¹ Non-Hodgkin lymphomas (NHL) which constitute 8–10% of all childhood malignancies is a heterogeneous group of diseases, as malignant clonal proliferation may occur at any stage during lymphocyte proliferation.² NHL constitutes a spectrum of lymphoid malignancies with diverse clinico-pathological and biological characteristics.³ NHL in children mostly presents as extra nodal disease and poses significant challenge in diagnosis, not only clinically but pathologically as well.^{4,5} Unlike secondary involvement of kidneys in lymphoma which is commonly observed; the

primary involvement is extremely rare in paediatric age group.⁶ Primary renal lymphoma (PRL) is a rare entity and constitutes only 0.7% of extra nodal lymphomas.⁷ PRL in paediatric age groups manifests as bilateral renal involvement, renal failure and anemia but unfortunately there is no standard treatment approach of PRL in children.⁸⁻¹⁰

We are hereby presenting a rare case of primary renal lymphoma in a child with review of pertinent literature. The scarcity of data available in the literature on the behaviour of NHL prompted us to report this case with the aim of describing the clinical and epidemiological characteristics of renal lymphoma. We have also

contrasted primary renal lymphoma with other common paediatric renal tumours in order to facilitate the distinction between various diseases presenting as renal masses in paediatric age group.

CASE REPORT

A 3 year old female was admitted in paediatric department of our institution with complaints of low grade and intermittent fever since 1 month along with facial puffiness and pedal edema since two weeks. There were no other systemic or urinary complaints. There was no history of fever with chills, pain, nausea, vomiting, chronic infections or features suggestive of gastrointestinal or urinary involvement.

The clinical examination revealed pallor, peri-orbital puffiness and non-pitting pedal edema. There was no fever, facial dysmorphism or lymphadenopathy. The patient had abdominal distension and large palpable lump in bilateral flanks which were non-ballotable, firm to hard in consistency with smooth margins. The blood pressure at the time of presentation was >99th centile. Rest of the systemic examination was normal.

Her laboratory evaluation showed leucocytosis 21,300 per mm³ with 68% lymphocytes. Urine microscopy, renal function tests, complement levels and anti-nucleic acid antigen (ANA) were normal. C- reactive protein (CRP) and viral markers were also negative. On radiological imaging, the ultrasound of abdomen revealed enlarged bilateral kidneys (right kidney measuring 10.5 × 5.6 cm and left kidney measuring 11.7 × 5.3 cm) with thickened renal parenchyma echo-texture. Further evaluation by contrast enhanced CT scan of thorax and abdomen was suggestive of grossly enlarged bilateral kidneys with loss of cortico-medullary differentiation. Multiple poorly marginated mildly enhancing, cortical based low attenuation lesions along with few areas of heterogeneous enhancement were also noticed (Figure 1a and 1b). There were no calcific foci and the renal artery was encased by the mass while the renal vein was patent. The collecting system was stretched rather than displaced with few discrete lymph nodes seen in pre-aortic, para-aortic and aorto-caval region. There were no metastasis to the lung field or mediastinum.

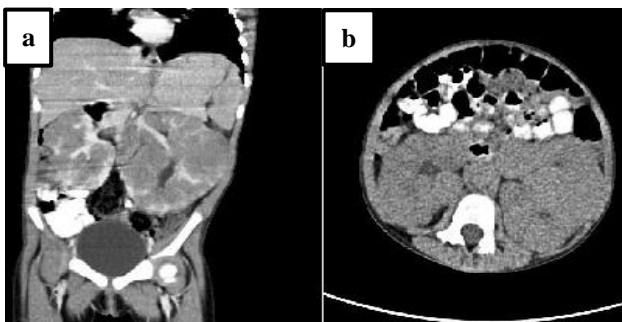


Figure 1: (a) and (b) CECT abdomen depicting bilateral renal masses.

A provisional diagnosis of bilateral Wilms tumour was made and by corroborating the history, clinical examination and imaging findings a bilateral renal biopsy was planned. Bilateral renal biopsy was performed by laparotomy. The histopathological evaluation described marked destruction of tubules and only few glomeruli with normal morphology. Diffuse infiltration by monomorphic lymphoid cells having high nucleo-cytoplasmic ratio (N:C), hyperchromatic nuclei and scanty cytoplasm was reported (Figure 2). The final impression was bilateral renal infiltration by diffuse non-Hodgkin's lymphoma.

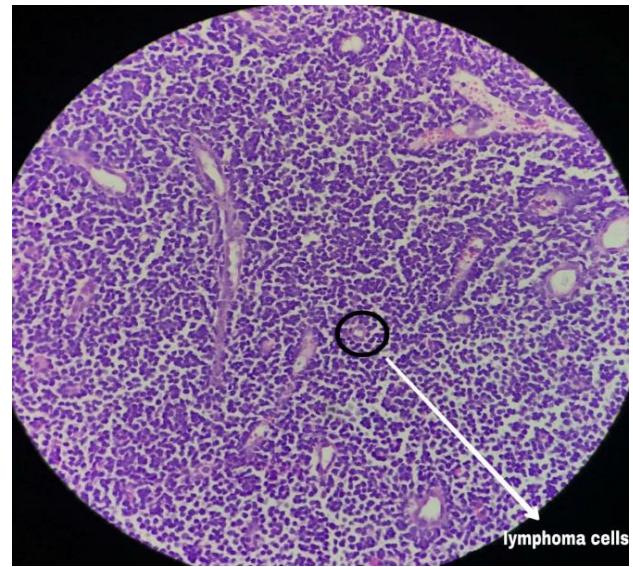


Figure 2: Histopathological examination showing lymphoma cells.

Subsequently, bone marrow examination was performed. Bone marrow smear showed markedly suppressed erythroid, myeloid & megakaryocytic series. Scattered cells were observed which comprised of mixed (small & large sized) lymphoblast-like cells (80%) with nuclear indentation. The features were suggestive of acute lymphoblastic leukaemia/ lymphoma.

Bone marrow biopsy also depicted hypercellular marrow space for age with altered distribution pattern. Here also the erythroid, myeloid and megakaryocytic series was suppressed and replaced by diffuse sheets of blast cells (>90%) having high N: C ratio, hyperchromatic nuclei and scanty cytoplasm. The findings were suggestive of acute lymphoblastic leukaemia/ lymphoma. Cerebrospinal fluid evaluation was also performed but it depicted no infiltration by tumour cells.

The patient was staged as bilateral renal diffuse non-Hodgkin's lymphoma stage IV on correlating tissue biopsy and bone marrow biopsy. The patient was managed with steroids along with vincristine, doxorubicin and asparaginase. The patient had only partial response and had a rapid downhill course after the first cycle of chemotherapy itself. Despite all aggressive treatment,

patient succumbed to the disease within 3 weeks of admission.

DISCUSSION

Renal masses are a common presentation in paediatric age group. The benign enlargement of kidneys among children can be attributed to many diseases viz. hydronephrosis, polycystic kidney disease, mesoblastic nephroma, multilocular cystic nephroma, multicystic dysplastic kidneys, renal abscess, mesoblastic nephroma, and medullary cystic disease complex. The most common malignant renal tumour in children include Wilms' tumour while the less common ones are anaplastic tumour, clear cell sarcoma and rhabdoid tumour of kidney.¹¹

There are significant variations worldwide in the incidence of childhood malignancies, among which lymphomas are the dominant type.⁹ Secondary involvement of kidneys in lymphoma is of common occurrence but primary involvement of kidney is quite rare.⁶ Primary renal lymphoma (PRL) is an uncommon renal tumour and constitutes only 0.7% of extra nodal lymphomas.⁷ Bilateral PRL is an extremely rare diagnosis in paediatric age group.

Since the renal parenchyma does not contain lymphatic vessels, the existence of primary lymphoma in the kidney is unlikely. However, rare cases of isolated renal lymphoma have been reported, and this topic remains controversial but biopsy has proven existence of primary renal lymphoma beyond doubt.

Four NHL subtypes comprise 90% of the NHL cases in children, namely Burkitt's lymphoma (BL), diffuse large B-cell lymphoma (DLBCL), lymphoblastic lymphoma (precursor T- and precursor B-cell lymphoma) and anaplastic large-cell lymphoma (ALCL). The remaining 10% include marginal zone, cutaneous, follicular and peripheral T-cell lymphomas, which are the NHL subtypes common in the adult population.³

Even though most of the children present with de novo NHL, some of these cases may be secondary to other etiologies such as: inherited or acquired immune deficiencies, viruses, or are included in the spectrum of genetic syndromes.¹² The possibility of an infectious etiology, principally associated with Epstein-Barr virus (EBV), being involved in the pathogenesis of NHL may be a partial explanation of the emergence of this disease in younger patients in our region, as populations of lower socioeconomic status are presumably exposed to infectious agents earlier in life.³ The incidence of childhood NHL reported general pattern of male predominance exhibited by lymphoid malignancies. The majority of lymphomas in adults are of low or intermediate grade, however, more than 90% of childhood NHLs are of high grade and mostly belong to one of four main categories as afore mentioned.¹³

The clinical appearance of NHL in children depends on sites of involvement and the pathologic subtype. Therefore, lymphoblastic lymphoma presents most commonly as an intra-thoracic or mediastinal mass and has a predilection for metastasizing in the bone marrow or central nervous system. Like-wise BL usually manifests as an abdominal mass in case of sporadic type, or head and neck mass in case of endemic type.¹² On the other hand, DLBCL rarely metastasizes to the bone marrow or central nervous system, but it can manifest as both abdominal or mediastinal mass. Anaplastic large cell lymphoma can present as a primary cutaneous tumour or a systemic disease. It usually spreads to liver, lungs, spleen, and mediastinum but rarely to bone marrow or central nervous system.¹² NHL in children is generally considered to be widely disseminated from the outset, even when apparently localized.³

PRL in paediatric age groups manifests as bilateral renal involvement, renal failure, and anemia.^{8,9} On the basis of their study in adults, Malbrain et al suggested the following criteria for diagnosis of renal lymphoma: renal failure as the initial presentation, bilateral enlargement of the kidneys without obstruction and other organ or nodal involvement, diagnosis only made by renal biopsy, absence of other causes of renal failure, and rapid improvement of renal function after radiotherapy or systemic chemotherapy.¹⁴

Despite bilateral renal involvement is the most common manifestation, acute renal failure, anaemia, haematuria, fatigue and musculoskeletal pain and extremely rare unilateral involvement has also been reported in children suffering from PRL.^{8,9} Both T-cell and B-cell renal lymphoma have also been reported.⁸

Results for lymphoma on abdominal CT, MRI and other imaging modalities are often similar to those of localized renal cell cancer and Wilms' tumours, making differentiation difficult.¹⁵ Involvement of kidneys in NHL is common and presents as hypodense nodular lesions on imaging or autopsies.

Metabolic and immunological derangements associated with lymphoma can lead to renal dysfunction. Hypercalcemia and uric acid nephropathy have been reported with renal lymphoma. In PRL, renal failure is the result of bilateral lymphomatous infiltration of the kidney.¹⁶

Aggressive lymphomas fall into the differential diagnosis of small blue round cells tumours and may be confused with other round cells tumour like neuroblastoma or blastemal component of WT, where immunohistochemistry (IHC) is of great help.¹⁶ The differential diagnoses of the renal mass in children with common radiological findings, specific characteristics and IHC markers is presented in Table 1.

Table 1: Various renal tumours presenting as renal masses in children

Tumour	Age group (peak age)	Imaging findings	IHC marker	Remark
Wilms' tumour Unilateral Bilateral	1-11 yrs (3.5 yrs) 2 months- 2 yrs (15 months)	Intrarenal solid mass with pseudocapsule with heterogeneous enhancement +/- calcification +/- regional LN +/- vascular invasion/thrombus +/- liver or lung metastasis	Blastemal- CD56, CD57 Epithelial- CK22, CK18, CK8, EMA Stromal - SMA, actin WT-1	Triphasic appearance consisting of stromal, epithelial, and blastemal elements. May be biphasic and monophasic
Mesoblastic nephroma	0-1 yr (1-3 months)	Large solid intrarenal lesion moderately enhancing- involves the renal sinus +/- necrosis, hemorrhage, cysts +/- perinephric extension similar to uterine leiomyoma or infantile fibrosarcoma	Common translocation: t(12;15) (p13;q25), involving the <i>ETV6</i> and <i>NTRK3</i> genes	Low grade spindle cell tumours Recur locally Rarely metastasize
Clear cell sarcoma	1-4 yrs (2 yrs)	Solid intrarenal demarcated mass+ necrosis +/- bone metastasis without vascular invasion	Vimentin and CD-99	Bone metastasizing renal tumor of childhood
Rhabdoid tumor	0.5-9 yrs (6-12 months)	Centrally located lobulated solid mass with indistinct borders involving the renal hilum with subcapsular fluid collections, lobules separated with necrosis, calcification and hemorrhage vascular invasion +/- lung, brain metastasis	Loss of INI1 expression in malignant cells	Hypercalcemia Widespread lymphogenous and hematogenous metastasis
Renal cell carcinoma (Von Hippel Lindau syndrome)	0.5-60 yrs (10-20 yrs)	Relatively small infiltrative solid mass, hyperintense+necrosis, hemorrhage, Calcification +/- cystic degeneration +/- retroperitoneal LN +/- lung, bone, liver Brain	Vimentin, AE1/AE3 keratins, CD10, RCC marker, and carbonic anhydrase IX	Similar to Wilms' tumor but significantly smaller in size usually adenocarcinoma
Neuroblastoma (adjacent organ)	0-5 yrs (40% < 1 yr and 90% < 5 yrs)	Heterogeneous mass + highly vascular + necrosis + calcification + displacing other organs + encasing aorta	CD56, chromogranin A, and synaptophysin	
Nephroblastomatosis	Any age (6-18 months)	Nephromegaly with multiple bilateral subcapsular lesions - loss of corticomedullary differentiation	Similar to blastemal cells	foci of persistent embryonal renal tissue, considered a precursor lesion for Wilms tumor
Renal medullary carcinoma	10-39 yrs (20 yrs)	Intrarenal heterogeneous mass with loss of corticomedullary differentiation+hydronephrosis +/- bone metastasis. Associated with sickle cell trait	CK7, CK19, CAM 5.2, EMA, Vimentin, AE1/AE3	Highly aggressive tumor in sickle cell trait

Continued.

Tumour	Age group (peak age)	Imaging findings	IHC marker	Remark
Primary renal lymphoma	Any age child (<10 yrs)	Homogeneous, hypoattenuated multiple nodules or masses indistinct margins associated lymphadenopathy	LCA, B-cell - CD20 and CD79a, T-cell - CD3 and CD5	
Angiomyolipoma	6-41 yrs (10 yrs)	multiple fat attenuated foci in B/L kidneys, heterogeneous enhancing Syndromic association (TS, VHL, NF)	HMG 45, Melan A	Associated with tuberous sclerosis complex.

There is increasing evidence that a renal mass in a doubtful situation can be subjected to 18FDG PET scan especially before contemplating nephrectomy. 18FDG PET may be useful in differentiating lymphomas from other renal tumours as they have more avid uptake.¹⁷

There is no standard treatment approach in case of PRL in children.⁸ In most cases, paediatric renal lymphomas are treated as in adults with six cycles of chemotherapy ± rituximab with varied outcome.^{8,10}

There has been a significant improvement in the overall survival (OS) of children and adolescents with NHL in last few decades. The reported disease-free survival for paediatric NHL, independent of subtype, is currently ~80%. The most significant prognostic determinants are type of treatment and the extent of the disease, as determined by pre-treatment staging. Paediatric DLBCL is considered to be biologically different from its adult counterpart and is associated with an excellent prognosis.³ Despite this patient of NHL with primary renal involvement i.e. primary renal lymphoma have grave prognosis and they rarely survive more than 1 year.¹⁶

PRL can manifest initially with an asymptomatic renal mass and can relapse later with systemic disease. Better radiological, nuclear imaging and comprehensive pathology can help in establishing an earlier and accurate diagnosis. Paediatric renal lymphomas are an aggressive form of lymphoma with guarded prognosis.

CONCLUSION

Primary renal lymphoma is very rarely observed as a paediatric NHL, and proper diagnosis upon discovery of a renal tumour may therefore be difficult. PRL can manifest initially with an asymptomatic renal mass and can relapse later with systemic disease. Better radiological, nuclear imaging and comprehensive pathology could have established an earlier and accurate diagnosis. In majority of cases of primary renal lymphoma in children, the disease progresses rapidly, renal function declines quickly, and there is rapid downhill course. Consideration of the possibility of malignant lymphoma as a differential diagnosis for renal tumour is therefore warranted in children. Paediatric renal lymphomas are an aggressive form of lymphoma with guarded prognosis.

Funding: No funding sources

Conflict of interest: None declared

Ethical approval: Not required

REFERENCES

1. Arora RS, Eden TO, Kapoor G. Epidemiology of childhood cancer in India. *Indian J Cancer*. 2009;46(4):264-5.
2. Sandlund JT, Downing JR and Crist WM: Non-Hodgkin's lymphoma in childhood. *N Engl J Med*. 1996;334:1238-48.
3. Sherief LM, Elsafy UR, Abdelkhalek ER, Kamal NM, Youssef DM, Elbehedy R. Disease patterns of paediatric non-Hodgkin lymphoma: a study from a developing area in Egypt. *Mol Clin Oncology*. 2015;3(1):139-44.
4. Murphy SB: Classification, staging and end results of treatment of childhood non-Hodgkin's lymphomas: dissimilarities from lymphomas in adults. *Semin Oncol*. 1980;7:332-9.
5. Pinkerton CR. The continuing challenge of treatment for non-Hodgkin's lymphoma in children. *Br J Haematol*. 1999;107:220-34.
6. Freeman C, Berg JW, Cutler SJ. Occurrence and prognosis of extranodal lymphomas. *Cancer*. 1972;29:252-60.
7. Tefekli A, Baykal M, Binbay M, Barut M, Muslumanoglu AY. Lymphoma of the kidney: primary or initial manifestation of rapidly progressive systemic disease?. *Int Urol Nephrol*. 2006;38:775-8.
8. Dhull VS, Mukherjee A, Karunanithi S, Durgapal P, Bal C, Kumar R et al. Bilateral primary renal lymphoma in a paediatric patient: staging and response evaluation with 18F-FDG PET/CT. *Rev Esp Med Nucl Imagen Mol*. 2015;34:49-52.
9. Dash SC, Purohit K, Mohanty SK, Dinda AK. An unusual case of bilateral renal enlargement due to primary renal lymphoma. *Indian J Nephrol*. 2011;21:56-8.
10. Lee SM, Son IC, Kim JJ, Lee T, Yoon SM, Kim SG. Primary renal lymphoma in a child. *Korean J Urol*. 2001;42:1220-3.
11. Lowe LH, Isuani BH, Heller RM, Stein SM, Johnson JE, Navarro OM et al. Pediatric renal masses: Wilms tumour and beyond. *Radiographics*. 2000;20:1585-603.

12. Hochbeg J, Giulino-Roth L, Cairo MS. In Kliegman RM, Stanton BF, St Geme JW III, Schor NF, Behrman RE. *Lymphoma. Nelson Textbook of Pediatrics.* New York. Elsevier. 2016: 2445–52.
13. Harris NL, Jaffe ES, Diebold J, Flandrin G, Muller-Hermelink HK, Vardiman J et al. World Health Organization classification of neoplastic disease of the hematopoietic and lymphoid tissues: report of the Clinical Advisory Committee meeting-Airlie House, Virginia. *J Clin Oncol.* 1997;17:3835-49.
14. Malbrain ML, Lambrecht GL, Daelemans R, Lins RL, Hermans P, Zachée P et al. Acute renal failure due to bilateral lymphomatous infiltrates. Primary extranodal non-Hodgkin's lymphoma (p-EN-NHL) of the kidneys: does it really exist? *Clin Nephrol.* 1994;42:163-9.
15. Hayakawa A, Shimotake N, Kubokawa I, Mitsuda Y, Mori T, Yanai T et al. Primary pediatric stage III renal diffuse large B-cell lymphoma. *Am J Case Rep.* 2013;14:34–7.
16. Coca P, Linga V, Gundeti S, Tandon A. Renal lymphoma: primary or first manifestation of aggressive paediatric B-cell lymphoma. *Ind J Med and Paediatr Oncology.* 2017;38(4):538-41.
17. Ye XH, Chen LH, Wu HB, Feng J, Zhou WL, Yang RM, et al. 18F-FDG PET/CT evaluation of lymphoma with renal involvement: comparison with renal carcinoma. *South Med J.* 2010;103:642-9.

Cite this article as: Thakur K, Wadhvani S, Ghodawat M, Prakash A, Khare A, Khaitan A, Singh S, Malhotra A. Primary renal lymphoma: a rare cause of renal mass in pediatric age group: case report and review of literature. *Int Surg J.* 2020;7(9):3127-32.