

## Original Research Article

# Hydatid disease in children: a single centre study with analysis of treatment protocol

Atul Mishra\*, Kalpesh Patel

Department of Surgery, Geetanjali Medical College and Hospital, Udaipur, Rajasthan, India

**Received:** 02 June 2020

**Revised:** 16 June 2020

**Accepted:** 17 June 2020

### \*Correspondence:

Dr. Atul Mishra,

E-mail: [dratulkumarmishra@yahoo.co.in](mailto:dratulkumarmishra@yahoo.co.in)

**Copyright:** © the author(s), publisher and licensee Medip Academy. This is an open-access article distributed under the terms of the Creative Commons Attribution Non-Commercial License, which permits unrestricted non-commercial use, distribution, and reproduction in any medium, provided the original work is properly cited.

### ABSTRACT

**Background:** Hydatid disease or hydatidosis is a zoonosis which is still an important health hazard in the world. This disease is a parasitic infestation which is endemic in many sheep and cattle raising areas of the world including India. The aim of this study was to evaluate the clinical features, diagnosis, and treatment of hydatid cyst in pediatric population.

**Methods:** This prospective study evaluated 32 pediatric patients with hydatid cyst who were treated at Geetanjali Hospital, Udaipur from 2016-2018. Medical records of these patients were studied and analyzed.

**Results:** 32 cases were in the age group of 7 to 14 years and were from rural background/ farming community and of low socioeconomic status. Male children, lungs were predominantly involved. Cattle rearing were common to the households of all patients. Ultrasonography and computed tomography scan were done in all patients and was the main diagnostic modality. All cases were managed surgically along with albendazole therapy and had complete recovery with no recurrence till date in any of our patients.

**Conclusions:** Hydatid disease is not rare in the pediatric age group. The liver and lung are commonly involved, but it may also present as primary disease in unusual sites like the spleen and brain. Careful surgery to avoid spillage with full course of drug therapy with albendazole can ensure permanent cure. A 28 day post-operative course was sufficient in majority of the cases. The disease can be prevented by proper community based measures like availability of clean water, sanitation and drug prophylaxis.

**Keywords:** Albendazole, Capittonage, Hydatid cyst, PAIR

### INTRODUCTION

Hydatid disease is a public health hazard in India particularly in Andhra Pradesh, Tamil Nadu, Jammu and Kashmir, central India and also parts of Rajasthan.<sup>1,2</sup> It is caused by parasite- cestode *Echinococcus granulosus* (dog tapeworm). It is common in rural areas where dogs and cattle are kept. The primary hosts for the tapeworm are dogs and other canines. They produce eggs in the intestine that pass in the stool. Eggs are ingested by intermediate hosts such as sheep and cows. Human become accidental hosts by eating tapeworm eggs.

Hydatid disease usually presents in adults (19-64 years) and is relatively uncommon in children.<sup>3-5</sup> In the adult population, it is characterized by cystic lesions, most commonly the liver (55-70%) and lungs (18-35%), though it can involve any organ of the body, except for hair, nails and teeth.<sup>2,6,7</sup> This proportion is different in children. Unusual sites of involvement include muscle (2-5%), bones (3%), kidneys (2%), heart (1%), pancreas (1%), central nervous system (1%), and spleen (1%).<sup>2,7-10</sup> The peritoneal cavity, thyroid, breast, gallbladder, thigh, supraclavicular region, soft tissue of the face, pericardium, diaphragm, mediastinum and pleural cavity are rarely involved. In about 5-13% of cases, two organs

are affected simultaneously. The cyst is identified by ultrasonography (USG) and confirmed with better delineation by computed tomography (CT) scan.<sup>11-14</sup> Immunodiagnosis makes the distinction of echinococcal cysts from benign cysts or malignant neoplasms possible.<sup>11,12</sup>

The structure of the cyst and nomenclature is differently described. Hence to avoid confusion, we describe it in brief as it will be used to describe surgical procedures. A hydatid cyst consists of three layers: 1) the outer pericyst, also known as pseudocyst, consists of fibrosed host tissue, 2) the middle laminated membrane called the ectocyst, secreted and formed by the parasite; 3) the inner germinal layer containing the actual scolices, called the endocyst.<sup>15</sup>

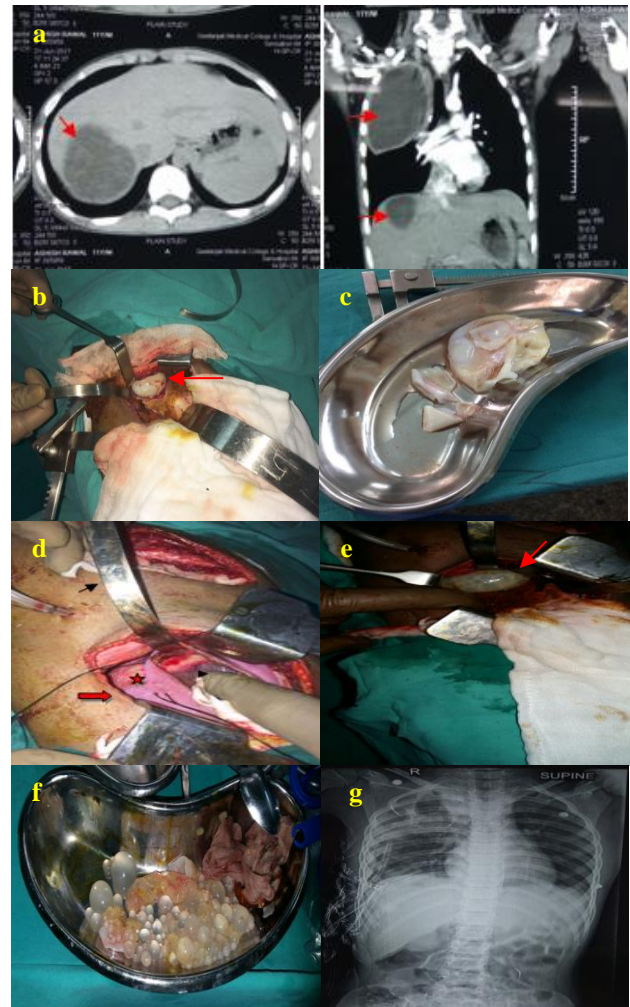
Here, we present a series of pediatric cases from a single centre in India in an effort to raise awareness among surgeons of this entity in children. Our aims were to study the presentation of hydatid disease in children, evaluate the risk factors, and derive appropriate management recommendations for prevention of recurrence and disease control.

## METHODS

This prospective study was conducted in hospitalized patients operated for liver hydatid cysts in Geetanjali Hospital, Udaipur from August 2016 to October 2018 after the ethical clearance from the institutional ethical committee. Data was collected from the patients admitted with diagnosis of hydatid disease from HIS software and from patient data file.

A total of 32 patients were included in this study based on pathological findings (detection of *Echinococcus granulosus* in biopsy specimen). Data was analyzed in terms of age, gender, clinical features, diagnostic investigations, operative technique, post-operative complications, mortality and duration of hospital stay. All patients were managed surgically. Cystotomy of pericyst (fibrous capsule) and complete excision of ectocyst and endocyst (both parts of the actual parasite) was done. The procedure was termed as cystectomy. Pericystectomy which means excision of cyst in-toto including outer pseudo/pericyst was not done in any case. Posterolateral thoracotomy and cyst excision were carried out for those with hydatid lung disease. Capittomage was done wherever feasible. All cavities were irrigated with scolicidal agent. 5% betadine was used for all lung cysts. The case with both liver and lung involvement was dealt with a double thoracotomy instead of a laparotomy as liver involvement was in the 7<sup>th</sup> lobe and access would have been very difficult. Liver was approached trans-diaphragmatically. After meticulous removal of each and every daughter cyst, the cyst cavity was irrigated with 3% hypertonic saline. The diaphragm was meticulously repaired after placing a drainage tube in the liver cyst cavity, also through the phrenotomy opening. Tube

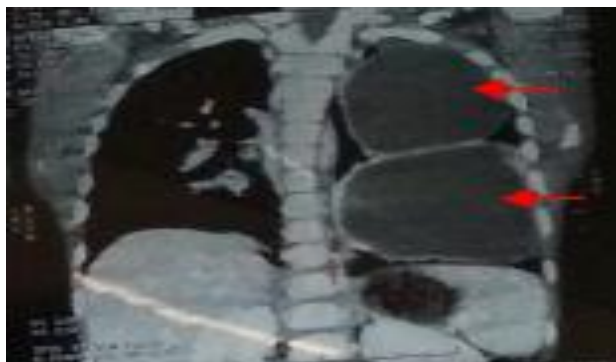
drainage was done in all patients with multiple tubes if required. None of our patients were suitable for percutaneous-aspiration-injection-reaspiration (PAIR) technique or medical therapy alone.



**Figure 1: (a) CT scan showing simultaneous right lung and liver cyst (small arrows); (b) right lung cyst approached by thoracotomy incision (small arrow); (c) excised lung cyst; (d) liver cyst approached via second thoracotomy incision and phrenotomy- small arrow (1<sup>st</sup> incision), broad arrow (2<sup>nd</sup> incision); arrow head (liver cyst), star (diaphragm); (e) liver cyst (in situ rupture) showing multiple daughter cysts inside (arrow); (f) excised multiple daughter cysts; (g) post-operative X-ray with 2 chest tubes in place showing satisfactory recovery.**

All patients received amoxicillin and potassium clavulanate combination (50-100 mg/kg/day in 3 divided doses), and amikacin (15 mg/kg/day in 2 divided doses) for 7 days. Amoxyclav was continued till chest drain was in situ. All patients were given albendazole 400 mg daily for 1 week pre-operatively. Albendazole (400 mg OD) was continued postoperatively for 4 weeks. A second course of 4 weeks was given after a gap of 7 days in two patients, one with simultaneous lung and liver cyst and another with double left lung cyst. All cysts were larger

than 5 cm in diameter; hence scolicidal agent (like hypertonic saline or 5% betadine) was injected in cyst cavity after aspiration of cyst component and then completely resected except in the liver cyst case in which excision and post-excision irrigation was done. In all cases, cavity was also irrigated by the same solution after excision. All resected cysts were sent for histopathological examination. All patients were followed up for 2-4 years and recurrence of the cyst was evaluated. No co-morbidity was seen in our study group. All patient identifying information remained confidential.



**Figure 2: Another case with ipsilateral large double cyst in left lung (small arrows).**

## RESULTS

There were 32 cases of hydatid disease in children, whose mean age was 11.2 years (range 7-14 years). The male to female ratio was 3:1. All patients were from a rural background or a farming community and of low socioeconomic status. Cattle rearing were common to the household of all the patients. All 32 patients had lung involvement. Right lung was predominantly involved (25 patients). Only one patient had liver cyst, that too with simultaneous lung involvement (Figure 1a). All the lung cysts were solitary except one female patient who had double ipsilateral left lung cysts (Figure 2). All the cysts were large (7 to 10 cm diameter). The patient with liver disease had multiple daughter cysts indicative of disintegration of ectocyst (Figure 1e). The duration of illness in our series ranged from 6 to 12 months. 3 more patients came to the OPD with solitary liver cysts but refused admission/intervention and hence could not be included in the study.

**Table 1: Clinical symptoms and signs in lung cyst (n=14).**

Sign and symptoms	Number of children	Percentage
Cough	32	100
Chest pain	15	46.8
Dyspnea	7	21.8
Fever	20	62.4
Hemoptysis	0	0

The most common presentation was recurrent cough, chest pain and dyspnoea on exertion in patients with lung disease. Pain in right hypochondrium was present in patient with both liver and lung involvement. Fever was present in 7 (21.8%) patients indicating secondary lung infection. Air entry was reduced on the side of lung involvement and the patient with liver disease had mild hepatomegaly (Table 1).

**Table 2: Hematological investigation (n=32).**

Hematological investigation	Number of children	Percentage
Raised WBC count	7	21.8
Anemia	21	65.62
Raised eosinophil count	9	28.1
ESR	11	34.37

Routine blood investigations were done in all patients and included CBC, LFT, KFT, and ESR (Table 2). Anemia (Hb <11.5 gm%) was present in 21 (65.6%) patients. Pre-operative blood transfusion was needed in 9 patients due to severe anemia (Hb <7 gm%). 2 patients received intra-operative transfusion. WBC counts were marginally raised in 7 (21.8%) patients with fever (>15,000/mm<sup>3</sup>). Eosinophil count was raised in 9 patients (28.1%). 2 patients had mild monocytosis. ESR was raised (more than 30) in 11 patients (34.37%). LFT and alkaline phosphatase was within normal range in all patients. We do not have immunological test facility at our institute.

USG was the main initial radiological diagnostic test. CECT chest (and abdomen if required) was done in all patients with accuracy rate of 100%. Chest X-ray, though done in all patients, showed non-specific findings indicative of some underlying disease. It was more important post-operatively to confirm lung expansion and complete recovery.

**Table 3: Organ involvement (n=32).**

Organs	Number of children	Percentage
Right lung	25	78.13
Left lung	6	18.75
Lungs and liver	1	3.13
Isolated liver	0	0

**Table 4: Clinical features in liver cyst (n=1).**

Clinical features	Number of children	Percentage
Abdominal pain	1	100
Loss of Appetite	1	100
Hepatomegaly	1	100
Jaundice	0	0
Ascitis	0	0

Thirty one (96.88%) patients had isolated involvement of the lung only. Right lung and left lung was predominantly

involved in 25 (78.13%) and 6 (18.75%) patients respectively. Only 1 (3.13%) patient had liver cyst, that too with simultaneous lung involvement (Figure 1a). All the lung cysts were solitary except one female patient who had double ipsilateral lung cysts (Figure 2). All the cysts except one were large (7 to 10 cm diameter). The patient with liver disease had multiple daughter cysts indicative of disintegration of ectocyst (Figure 1e). The duration of illness in our series ranged from 6 to 12 months (Table 3).

There was only 1 case of liver cyst and in that abdominal pain, Loss of appetite and hepatomegaly was present and jaundice and ascitis was not present (Table 4).

**Table 5: Operative modality (n=32).**

Operative modality	Number of children	Percentage
<b>Cystectomy</b>	32	100
<b>Capittonage</b>	17	53.13

Cystectomy was done in all 32 (100%) cases and capittonage was done in 17 (53.13%) cases whereas other operative modality such as segmental excision, lobectomy and pericystectomy was not required in any of the cases (Table 5).

Histopathologic examination confirmed hydatid cyst in all (100%) patients which showed scoliosis of *E. granulosus*. There was no case of *E. multilocularis*.

**Table 6: Intra-operative complications (n=32).**

Intra-operative complications	Number of children	Percentage
<b>Spillage and anaphylaxis</b>	0	0
<b>Mortality</b>	0	0

Regarding intra-operative complications, there was no case with spillage, anaphylaxis and mortality (Table 6).

**Table 7: Post-operative complications (n=32).**

Post-operative complications	Number of children	Percentage
<b>Superficial wound infection</b>	7	21.8
<b>Prolonged air leak</b>	8	25
<b>Broncho pleural fistula</b>	0	0
<b>Recurrence</b>	0	0

Prolonged air leak was seen in 8 (25%) patients which was managed conservatively by aggressive chest physiotherapy and continuing with chest tube drainage. 7

(21.8%) patients had superficial wound infection (Table 7).

Average stay in the hospital was 10 days. Partial lung expansion was noticed without symptoms in 11 patients but follow up X-ray after 1 month showed complete expansion. No case had anaphylactic shock. With a 2 to 4 year follow up, there has been no recurrence in our series, owing to the preoperative planning and meticulous per operative precautions to prevent spillage and ensuring complete resection of cyst.

## DISCUSSION

Hydatid disease is not rare in the pediatric age group. The liver and lungs are commonly involved, but hydatidosis may also present as primary disease in unusual sites such as the spleen and brain. In children lungs are most commonly involved, followed by liver. This is different from adults who have predominantly liver disease. Having a high index of suspicion is important. Symptoms depend on the size and site of the disease. The age of the child may be as low as 7 years. The risk factors we found was rural background, low socioeconomic status, cattle rearing, farming community, poor education, lack of a potable water supply and male sex. For diagnosis, high index of suspicion is required considering history including residence, family occupation etc. of the patient. Blood investigations reveal high eosinophil count.<sup>16</sup>

In our study it was in 28.5% cases. Other routine laboratory tests are not specific as in our study. Immunodiagnostic techniques include tests for screening (ELISA) and confirmatory tests (immuno-electrophoresis).<sup>11</sup> But both these have high false negative rate, may be >50%.<sup>14</sup> Other older tests like Casoni's intradermal tests are now redundant. USG and CT scan are the investigations of choice, with CT scan being the best imaging modality. It is also helpful in planning surgery.<sup>11-13</sup> The same was found in our study.

Complete surgical excision with appropriate drug therapy (albendazole) remains the treatment of choice.<sup>1,2,6,13,14,17</sup>

In case of liver cysts, newer technique of USG/CT guided PAIR (percutaneous, aspiration, instillation of hypertonic saline or other scolicidal agents, reaspiration) has emerged as minimal access therapy. It is a promising technique with low mortality but has limited indications. It is usually used in simple accessible cysts surrounded by tissue.<sup>13,14</sup> In suitable cases results of PAIR with albendazole are comparable to surgical excision with lower morbidity.<sup>14</sup>

None of our case was suitable for this treatment. The scolicidal agents used are hypertonic saline (15-20%), sodium hypochlorite (0.5%), betadine (1%, some use 5% or 10%), and ethanol (75-95%).<sup>13</sup>

In our cases, 3% hypertonic saline was used as it was available. PAIR is contraindicated in pregnancy and bile stained cysts to avoid damage to biliary tree. We used betadine 5% solution for large lung cysts and saline for the liver cyst to irrigate after surgical excision. Radical total or partial pericystectomy with omentoplasty or hepatic segmentectomy are other options.<sup>13</sup> For pulmonary disease, segmentectomy and occasionally pneumonectomy are radical procedures rarely required. Laparoscopic approach is being used with success at some centres.

Overall the indications for surgery are presence of large liver cysts with multiple daughter cysts, single superficially situated liver cysts that may rupture spontaneously, infected cysts, cyst communicating with biliary tree and/or exerting pressure on adjacent vital organs and cysts in lung, brain, kidney or bones, though many cases of brain involvement respond to medical therapy.<sup>13,14</sup> Simultaneous drug therapy is very important. Usual protocol is to start albendazole treatment 1 week prior to surgery or PAIR technique and continued for 1 month thereafter.<sup>14</sup> For conventional surgery, the inner cyst wall (ectocyst and endocyst) are of parasitic origin and should be removed completely. After incising the outer fibrous layer (pericyst or pseudocyst), the inner wall peels off easily. Some studies suggest removal of whole capsule (entire cyst including pericyst) has better outcome, but we feel that this is more morbid and risky procedure.<sup>18,19</sup>

Extreme care should be taken to avoid spillage. Prophylactic steroid therapy with hydrocortisone is usually administered at the time of incision to avoid anaphylaxis. For all patients with lung disease, we followed the standard protocol of preserving maximum viable lung tissue with cyst excision after incising the outer fibrous layer (pseudocyst) and capitonnage (suturing together the walls), wherever possible.

We used the same standard protocol in all our cases. None of our patients were suitable for PAIR technique as all had large lung cysts. The case with liver disease had multiple daughter cysts in an inaccessible area of liver. All cases received 28 day course of albendazole (2 cases received an extra 1 month course). We used standard pediatric dose of 400mg (all cases above 2 years). Drug therapy showed a wide variation in literature.

Nelson prescribes one month course post procedure.<sup>14</sup> Others have advised three courses of 1 month each with a gap of 14 days while one study has advised drug therapy for 3-6 months.<sup>2,17</sup> Another adult case study prescribes 10-15 mg/kg/day albendazole for 6 weeks pre-operatively and same dose for 6 week post operatively.<sup>2</sup> Potential side effects are gastro-intestinal disturbances, alopecia, leukopenia and elevated transaminases on prolonged use.<sup>14</sup> In all our cases, the drug was well tolerated.

We found a 28 day course of albendazole sufficient in our patients with an extra 1 month course in cases like multiple cysts or local intracapsular rupture with daughter cysts. In high risk cases of complete rupture into pleural/peritoneal cavity, we think a 6 month course is still the best.

Anthelmintic treatment in isolation is indicated for inoperable cases because of poor general condition, diffuse disease affecting both lungs, and recurrent or ruptured cysts.<sup>13</sup>

Some studies have emphasized that small cysts (<5 cm) can be treated by medical treatment alone under close observation.<sup>19,20</sup> Though this study is limited regarding number of cases, it succeeds in emphasizing optimum drug therapy, clinical features and surgical treatment of hydatid disease particularly in lungs which are predominantly involved in pediatric patients.

## CONCLUSION

Hydatid disease is not rare in the pediatric age group. The liver and lung are commonly involved, but it may also present as primary disease in unusual sites like the spleen and brain. Careful surgery to avoid spillage with full course of drug therapy with albendazole can ensure permanent cure. A 28 day post-operative course was sufficient in majority of the cases. The disease can be prevented by proper community based measures like availability of clean water, sanitation and drug prophylaxis.

Proper sanitation, control of dog population and regular treatment/prophylaxis with praziquantel of pet dogs, proper disposal of waste particularly carcasses and meat inspection, thorough hand washing after contact with dogs or their feces are recommended for disease prevention and control.

*Funding: No funding sources*

*Conflict of interest: None declared*

*Ethical approval: The study was approved by the Institutional Ethics Committee*

## REFERENCES

1. Nandu VV, Pothare AN, Deshpande AV. Hydatid disease in lung. Int Surg J. 2016;3:1570-3.
2. Illuri HR, Souza CD, Dias EAI, Das PP. Hydatid disease: a two year retrospective study in a tertiary care centre in South India. Int Surg J. 2018;5:602-7.
3. Montazeri V, Sokuti M, Rashidi HR. Comparison of pulmonary hydatid disease between children and adult. Tanaffos. 2007;6(1):13-8.
4. Talaiezhadeh A, Maraghi SH. Hydatid disease in Children: A different pattern than adults. Pak J Med Sci. 2006;22(3):329-32.
5. Rattan KN, Sharma A. Hydatid disease in children. Indian J Chest Dis Allied Sci. 1998;40(1):73-7.

6. Tantawy IM. Hydatid cysts in children. *Ann Pediatr Surg.* 2010;6(2):98-104.
7. Kamble MA, Thawait AP, Kamble AT. Hydatid cyst in the past and the present. *J Evol Med Dent Sci.* 2014;3(18):4886-902.
8. Venukumar R. Clinical presentation of hydatid cyst of liver: descriptive study. *Int Surg J.* 2017;4(1):214-6.
9. Duman K, Girgin M, Hamcan S. Uncomplicated hydatid cysts of the liver: clinical presentation, diagnosis and treatment. *J Gastrointest Dig Syst.* 2016;6(430):2.
10. Gole S, Gole G, Stayanaratana V. Unusual presentation of hydatid cyst: A case series with review of literature. *Internet J Parasit Dis.* 2013;6(1).
11. Sayek I, Tirnaksiz B, Dogan R. Cystic hydatid disease: current trends in diagnosis and management. *Surg Today.* 2004;34:987-96.
12. Safioleas M, Misiakos E, Manti C, Katsikas D, Skalkeas G. Diagnostic evaluation and surgical management of hydatid disease of the liver. *World J Surg.* 1994;18:859-65.
13. Williams N, O'Connell PR, McCaskie A. Bailey and Love, *Short Practice of surgery.* 26th edn. CRC Press; 2013:74-78.
14. Kliegman RM, Stanton BMD, St. Geme J, Schor NF, Behrman RE. *Nelson Textbook of Pediatrics.* 19th edn. Elsevier Saunders; 2011: 1234-1239.
15. Golzari SEJ, Sokouti M. Pericyst: the outermost layer of hydatid cyst. *World J Gastroenterol.* 2014;20(5):1377-8.
16. Fahimzad A, Karimi A, Tabatabaei SR, Armin S, Ghanaei RM, Fallah F, et al. Overview of hydatid disease in Iranian children. *Arch Pediatr Infect Dis.* 2015;3(3):e30084.
17. Mirshemirani A, Khaleghnejad A, Kouranloo J, Sadeghian N, Rouzrokh M, Yeganeh SH. Liver hydatid cyst in Children. *Iran J Pediatr.* 2011;21(3):385-9.
18. Kir A, Baran E. Simultaneous operation for hydatid cyst of right lung and liver. *Thorac Cardiovasc Surg.* 1995;43:62-4.
19. Sarkar M, Pathania R, Jhobta A, Thakur BR, Chopra R. Cystic pulmonary hydatidosis. *Lung India.* 2016;33(2):179.
20. Oral A, Yigiter M, Yildiz A, Yalcin O, Dikmen T, Eren S, et al. Diagnosis and management of hydatid liver disease in children: a report of 156 patients with hydatid disease. *J Pediatr Surg.* 2012;47(3):528-34.

**Cite this article as:** Mishra A, Patel K. Hydatid disease in children: a single centre study with analysis of treatment protocol. *Int Surg J* 2020;7:2141-6.