

## Case Report

### Perforation of a Meckel's diverticulum secondary to chronic NSAID use: case report and review of the literature

Francisco Terrazas Espitia<sup>1\*</sup>, David Molina Davila<sup>1</sup>, Luis Villalobos Ramirez<sup>2</sup>, Bruno Salazar Trujillo<sup>1</sup>, Lucio Santos Moyron<sup>1</sup>, Ariadna Mondragon Salgado<sup>1</sup>

<sup>1</sup>Department of Digestive surgery, Hospital Espanol de Mexico

<sup>2</sup>Department of Radiology, Hospital Espanol de Mexico

**Received:** 05 June 2020

**Revised:** 15 July 2020

**Accepted:** 27 July 2020

#### \*Correspondence:

Dr. Francisco Terrazas Espitia,

E-mail: franciscoter6@hotmail.com

**Copyright:** © the author(s), publisher and licensee Medip Academy. This is an open-access article distributed under the terms of the Creative Commons Attribution Non-Commercial License, which permits unrestricted non-commercial use, distribution, and reproduction in any medium, provided the original work is properly cited.

#### ABSTRACT

Meckel's diverticulum is an abnormality in the development of the gastrointestinal system, its origin and clinical significance was first described by Johan Friedrich Meckel in 1809. It is a remnant of the omphalomesenteric duct which is usually observed following the rule of 2's, located 2 feet proximal to the ileocecal valve, before 2 years of age in approximately 2% of the population, and is twice as common in male population. It is considered a true diverticulum because it presents all the histopathological layers of the bowel; 6% of the cases present with heterotopic tissue, mainly pancreatic, gastric, colonic or jejunal. We present the case of a 37-year-old patient who presented with acute onset epigastric pain which migrated to the right iliac fossa, he had a history of chronic non-steroidal anti-inflammatory drugs (NSAIDs) usage for articular pain. He underwent abdominal contrast tomography (CT) scan with double iodine contrast enhancement, which revealed the presence of a perforated Meckel's diverticulum in the antimesenteric portion of the terminal ileum. The patient underwent laparoscopic diverticulectomy with no complications and was discharged 72 hours after the procedure. Histopathological confirmation of a perforated meckel's diverticulum with heterotopic gastric mucosa confirmed the clinical suspicion of perforation secondary to chronic NSAIDs usage.

**Keywords:** Meckel's Diverticulum, Laparoscopy, Advanced laparoscopy, Diverticulum, Gastrosurgery, Laparoscopic intestinal resection, Acute abdomen

#### INTRODUCTION

Meckel's diverticulum is the most common congenital abnormality of the gastrointestinal system, with a reported incidence of 0.6-4% on different series. It derives from an incomplete obliteration of the omphalomesenteric canal which results in the creation of a true diverticulum.<sup>1</sup> Even though it had previously been described, Johan Friedrich Meckel interpreted the significance and origin of Meckel's diverticulum in 1809, and demonstrated conclusively that this abnormality represents an intestinal remnant of the omphalomesenteric duct.<sup>2</sup> Meckel's diverticulum often

presents with the following clinical characteristics: it is usually located 2 feet proximal to the ileocecal valve, it usually presents before the age of 2 years, is twice as common in men than it is in women, and it can be found approximately in 2% of the general population (these clinical characteristics are referred to as "The rule of 2's").<sup>3</sup> Heterotopic tissue has been observed in up to 6% of asymptomatic Meckel diverticulum, mainly pancreatic, gastric, colonic and jejunal tissue. Charles W. Mayo stated that "Meckel's diverticulum is frequently suspected, often looked for, and seldom found", and even though symptoms are more frequent in the pediatric population, it can manifest in any age group. The most

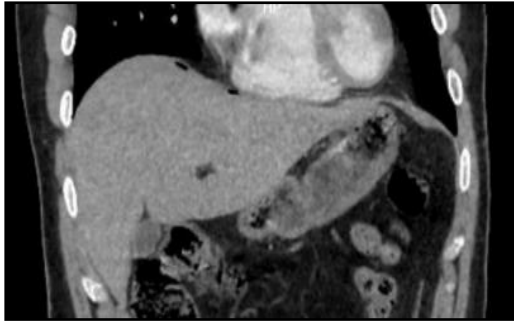
frequently observed symptoms are: intestinal obstruction (due to volvulus of the small gut around a diverticulum, incarceration of the diverticulum in a hernia (also known as Littre's Hernia) and formation of enteroliths within the diverticulum), gastrointestinal bleeding (most common cause of painless GI bleeding in children less than 2 years of age), acute inflammation (also referred to as Meckel's diverticulitis), there are also cases of benign tumors such as angioma lipoma, neurofibroma and leiomyoma, or malignant tumors such as leiomyosarcoma and carcinoid, related to Meckel's diverticulum.<sup>4</sup> Preoperative diagnosis in patients without where Meckel's diverticulum is not suspected is rare, and it is commonly diagnosed in the scenario of its complication; x-ray have no diagnostic value, but very rarely an enterolith may be observed incidentally on an x-ray film, barium studies may demonstrate a mucosal triangular plateau or a triradiate fold pattern which arises away from the axis of the root of the mesentery. Contrast tomography (CT) scan may detect a tubular image which arises from the antimesenteric border of the terminal ileum, but it is usually mistaken for a normal bowel loop. Scintigraphy with 99 mTc-pertechnetate may be effective in detecting ectopic gastric mucosa, and while it has been reported to have an 85-90% sensitivity in pediatric population, it can only detect up to 60% of adult patients with Meckel's diverticulum with ectopic gastric mucosa.<sup>5</sup> The age adjusted incidence for men has been reported in the ranges of 124 cases per 100,000 person-years, whilst in women these cases amount to 50-100,000 person-years; an accurate incidence is hard to report given that, though it is generally believed to occur in up to 2% of the population, this entity is rarely diagnosed pre-operatively, and is mostly revealed when facing the complications that may arise from it.<sup>6</sup>

## CASE REPORT

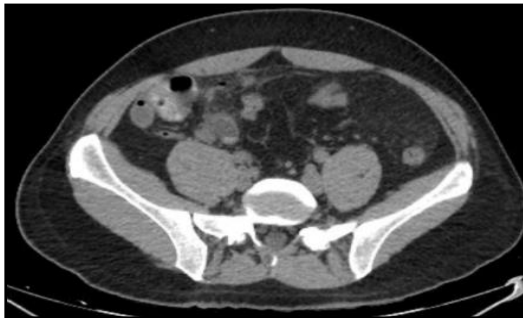We present the case of a 37 year old male, who presented to the emergency department with a 24-hour history of colicky abdominal pain, which he referred began in the epigastrium with posterior irradiation to the right iliac fossa and ipsilateral inguinal region accompanied by anorexia without nausea or vomiting. The patient had no significant previous medical history except for a chronic ingestion of NSAIDs (diclofenac 100 mg/po/daily) related to a knee injury sustained 4 months prior to consultation, the patient did not refer ingestion of proton pump inhibitors for gastric mucosal protection. Physical examination revealed abdominal hyperesthesia with localized pain in the right iliac fossa related to deep and superficial palpation, there was also rebound tenderness and Blumberg's sign was present. Laboratory data showed an elevation of inflammatory markers mainly leucocytosis with a neutrophilic tendency without any other alterations. An abdominal CT scan was performed with iodinated intravenous contrast revealing pneumoperitoneum in an epigastric and sub diaphragmatic location accompanied by inflammation of the pericecal fatty tissue. Given the CT scan findings and

the history of chronic NSAID usage, suspicion arose regarding the presence of a probable gastric or duodenal ulcer perforation; a new CT scan was performed this complementing with oral contrast which allowed gastric and duodenal wall visualization, which did not appear thickened or with surrounding fat stranding or other signs of perforation, in contrast, the radiology department reported free gas adjacent to the terminal ileum with stranding of the pericecal fatty tissue, the appendix didn't present any signs of perforation or inflammation, and upon closer look, the radiologist described the presence of a saccular image adjacent to the small intestine, which appeared to arise from the antimesenteric portion of the terminal ileum and was suggestive of a Meckel's diverticulum. The patient was taken to the O.R. for surgical management. Initially, optic trocar was placed using the open Hasson's Technique. Upon diagnostic laparoscopy we encountered an inflammatory mass surrounding the terminal ileum and cecum. A 10 mm trocar was placed in the left iliac fossa and a 5 mm trocar was placed in the suprapubic space, 5 cm away from the umbilicus. We performed atraumatic dissection of the stranded fat, encountering scarce biliary/intestinal fluid surrounding the terminal ileum as well as a Meckel's diverticulum which presented a perforated ulcer at its lower third portion; we followed the loop of terminal ileum proximally and distally and found no other sources of inflammation or other lesions, once this manoeuvre was performed, we assessed the base of the diverticulum, observing a long diverticulum, with a wide "mouth", and a perforated ulcer in its lower third portion. We introduced a Maryland dissector through the ulcer to assess caudal and cephalad lumen of the terminal ileum. Upon examination of the anatomical characteristics of the diverticulum, we decided to proceed with laparoscopic diverticulectomy. Mechanical resection of the diverticulum was performed at the base with an Ethicon Endopath© 45 mm laparoscopic linear stapler. Adequate passage of fluid was assessed by compressing the bowel proximal to the stapler line and observing passage of gas and liquid from the proximal to the distal end without any resistance or leakage. We reinforced the stapler line with fibrin sealant, which was applied over the stapler line in the resection site. Once the specimen was extracted with endobag, we opened it to confirm adequate resection margins and observed ectopic gastric mucosa lining the lumen of the diverticulum, the diverticulum was afterwards sent to definitive pathologic analysis. The patient underwent a normal postoperative period and was started on a clear liquid diet the next day after passing gas and a complete bland diet regime 48 hrs after the procedure, he passed stool later that day. The patient was discharged 3 days after the procedure.

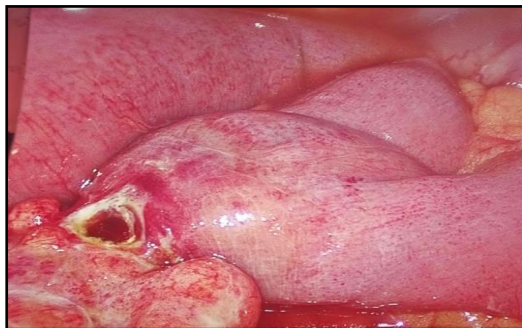Definitive histopathological examination reported an ileum segment and a perforated Meckel's diverticulum with ectopic gastric tissue presenting chronic follicular gastritis and ulceration of its lumen, which was consistent with clinical suspicion of ulcerated gastric ectopic tissue due to the chronic use of NSAIDs.



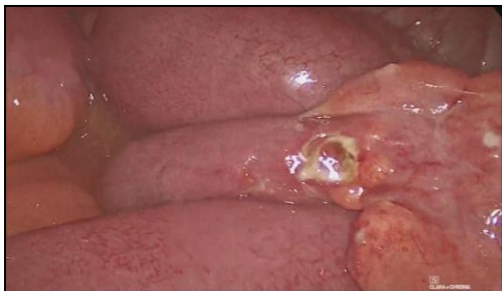**Figure 1: Iodinated intravenous contrast -abdominal CT scan which reveals sub diaphragmatic free gas.**



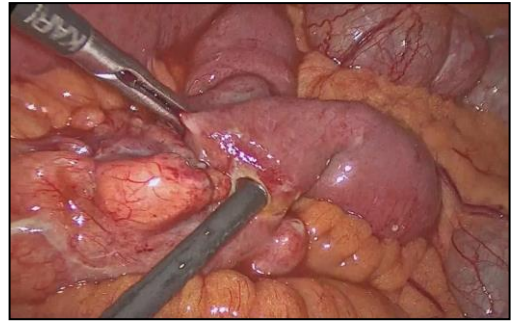
**Figure 2: Double contrast (oral and iv) abdominal and pelvic CT scan which reveals the presence of a sacular image which arises from the antimesenteric portion of the terminal ileum, suggestive of a Meckel's diverticulum.**



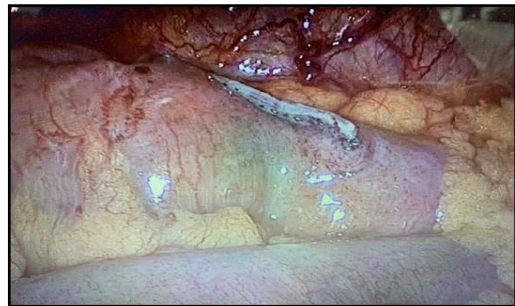**Figure 3: Meckel's diverticulum in the antimesenteric portion of the terminal ileum with a perforated ulcer on its lower third portion.**



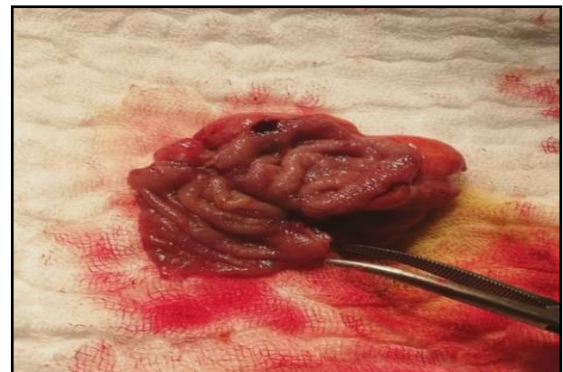**Figure 4: Perforated Meckel's diverticulum in the antimesenteric portion of the lower third of the terminal ileum.**



**Figure 5: Introduction of a Maryland dissector through the ulcer to assess caudal and cephalad lumen of the terminal ileum.**



**Figure 6: Adequate lumen with passage of liquid and gas through stapler line; reinforcement of the stapling line with fibrin sealant,**



**Figure 7: Meckel's diverticulum with ectopic gastric mucosa lining its lumen. Adequate resection margins were observed.**

## DISCUSSION

Meckel's diverticulum is a true intestinal diverticulum which contains all the histological layers of the intestine, it is the most common intestinal malformation and has been reported to occur in up to 2% of the population; though symptomatic Meckel's diverticulum is uncommon in the general population (only 2-4% of patients will present with complications) when these arise, they can be life threatening.<sup>7</sup> Ulceration and subsequent perforation of Meckel's diverticulum has been hypothesized to be more frequent in male adult population due to a higher



level of gastrin production and therefore a higher level of gastric acid production.<sup>8</sup> It has been generally accepted that Meckel's diverticulum most frequently presents following the next pattern: 2% of the population, 2 feet from the ileocecal valve, 3 inches long and having 2 types of ectopic tissue (gastric and pancreatic) (commonly referred to as the rule of 2's).

NSAIDs act by inhibiting prostanoid biosynthesis, and present gastric and renal toxicity by means of cyclooxygenase-1 (COX-1) isoform inhibition. When COX-1 is inhibited in the gastrointestinal tract, there is a reduction in prostaglandin secretion which in result diminishes its cytoprotective effects and increases susceptibility to mucosal injury.<sup>9</sup> The presence of perforated heterotopic gastric mucosa observed with histopathologic study as well as having a previous history of chronic NSAIDs use confirms clinical suspicion of a direct relationship between ulcer development and eventual perforation and the use of this medication, thought there are very few cases reported to have such correlation. Meckel's diverticulum is usually diagnosed trans-operatively or due to its complications, which are most frequently related to gastrointestinal hemorrhage (which manifests as melena or hematochezia, in up to 30% of symptomatic cases), obstruction and rarely diverticulitis or perforation; preoperative image diagnosis is very rare, and in this case was obtained with a double contrast enhanced CT scan of the abdomen; most frequently CT scan findings describe a blind-ending structure which presents with gas or liquid, and is in continuity with small bowel, in other cases bowel obstruction, presence of enteroliths or intussusception may be reported adjacent to the diverticulum.<sup>10</sup>

The patient presented with a very good post-operative evolution, passing gas and starting de-ambulation on the first 6 hours postoperatively, which allowed for fast track protocol implementation, starting oral intake of liquids the same night of the procedure, and bland diet the next morning, accounting for a short hospital stay with no complications after discharge.

## CONCLUSION

Meckel's diverticulum although uncommon still presents itself as a challenging diagnosis, it's important for surgeons to have it in mind as a differential diagnosis for it may have important complications leading to high morbidity and mortality if misdiagnosed. Laparoscopic approach and use of enhanced recovery after surgery protocols allows for a more expedite recovery in our patients and better overall results.

*Funding: No funding sources*

*Conflict of interest: None declared*

*Ethical approval: Not required*

## REFERENCES

1. Kuru S. Meckel's diverticulum: clinical features, diagnosis and management. *Rev Esp Enferm Dig.* 2018;110(10):726-32.
2. Opitz, Schultka JM, Gobbel R, Lumitina. Meckel on developmental pathology. *American Jour of Med Gen.* 2006;140A:115-28.
3. Uppal K, Shane Tubbs R, Matusz P, Shaffer K, Loukas M. Meckel's diverticulum: A review. *Clinical Anat.* 2011; 24(4):416-22.
4. Malik AA, Shams-ul-Bari KA, Khaja AR. Meckel's diverticulum-Revisited. *Saudi Jour Of Gastro.* 2010;16(1):3-7.
5. Kotha VK, Khandelwal A, Saboo SS, Shanbhogue AK, Virmani V, Marginean EC, Menias CO. Radiologist's perspective for the Meckel's diverticulum and its complications. *Br J Radiol.* 2014;87(1037):20130743.
6. Cullen JJ, Kelly KA, Moir CR, Hodge DO, Zinsmeister AR, Melton 3rd LJ. Surgical management of Meckel's diverticulum: an epidemiologic, population-based study. *Ann of surg* 1994;220(4):564-9.
7. Dias de Castro, Magalhaes. J, Moreira. M, Cotter. J, Ulcerated Meckel's diverticulum. *Gastro Y Hep.* 2014;37(2):69-71.
8. Çelebi S. Male predominance in Meckel's diverticulum: a hyperacidity hypotheses. *Med Hyp.* 2017;104:54-7.
9. Drini M. Peptic ulcer disease and non-steroidal anti-inflammatory drugs. *Australian prescriber.* 2017;40(3):91-3.
10. Elsayes K, Menias C, Harvin H, Francis I. Imaging manifestations of Meckel's diverticulum *Ame Jour Roent.* 2007;(189):81-8.

**Cite this article as:** Espitia FT, Davila DM, Ramirez VL, Trujillo SB, Moyron SL, Salgado MA. Perforation of a Meckel's diverticulum secondary to chronic NSAID use: case report and review of the literature *Int Surg J* 2020;7:3082-5.