

## Original Research Article

# Role of laparoscopic appendicectomy in management of early appendicular mass

Kota Ramesh\*, Khyati Kiran Janapareddy

Department of General Surgery, Gandhi Medical College, Secunderabad, Telangana, India

**Received:** 01 June 2020

**Revised:** 13 June 2020

**Accepted:** 16 June 2020

**\*Correspondence:**

Dr. Kota Ramesh,

E-mail: kotaramesh26@gmail.com

**Copyright:** © the author(s), publisher and licensee Medip Academy. This is an open-access article distributed under the terms of the Creative Commons Attribution Non-Commercial License, which permits unrestricted non-commercial use, distribution, and reproduction in any medium, provided the original work is properly cited.

### ABSTRACT

**Background:** Appendicular mass consists of matted loops of bowel and omentum adherent to the adjacent inflamed appendix. Laparoscopic approach adds diagnostic value and allows visualization of entire abdominal viscera facilitating better and safer dissection.

**Methods:** This is an observational prospective study done in patients presenting to Gandhi Hospital's surgical department with incidentally detected appendicular mass on laparoscopy from August 2016 to August 2018.

**Results:** Maximum cases belong to adolescent age group (13 out of 30). Majority of cases are male patients (24 out of 30). Each surgery took around 1 hour. No intraoperative complications occurred in 23 patients. Difficult adhesiolysis experienced in 5 patients. Serosal bowel injury occurred in 1 patient. Orals were delayed where intraoperative dissection was prolonged or difficult. Majority of patients were discharged after 3 days.

**Conclusions:** With immediate operative management of appendicular mass presenting in early stages of inflammation, dissection can be safely proceeded with and appendicectomy can be safely performed eliminating the need for second hospitalization and risk of recurrence. The incidence of intra-operative and post-operative complications is low making laparoscopic appendicectomy in early appendicular mass a safe and feasible treatment option.

**Keywords:** Early appendicular mass, Laparoscopic appendicectomy, Treatment

### INTRODUCTION

Appendicular mass consists of matted loops of bowel and omentum adherent to the adjacent inflamed appendix. Sometimes fallopian tubes and ovaries may form a part of the appendicular mass in female patients. Early surgical intervention has been known to be an effective alternative to conservative therapy for a long time, as it considerably reduces the total hospital stay and obviates the need for a second admission.<sup>1</sup> Moreover, in 10-20% of the cases, conservative management fails and the patients need an emergency operation due to peritonitis, which is comparatively more difficult and carries more morbidity and mortality.<sup>2,3</sup> The treatment for

appendicular mass with appendicectomy poses the risk of inadvertent bleeding and complications like ileal or caecal perforation during dissection. Laparoscopic approach adds diagnostic value and allows visualization of entire abdominal viscera facilitating better and safer dissection. There are limited studies claiming laparoscopic appendicectomy's feasibility in early appendicular mass.

This study aims to determine the feasibility, safety and complications arising from laparoscopic appendicectomy in patients presenting with incidentally detected appendicular mass on laparoscopy.

Aim of the study was to evaluate the feasibility and complications of laparoscopic appendicectomy in early appendicular mass.

**METHODS**

It was an observational prospective study done in 30 patients presenting to Gandhi Hospital’s surgical department with incidentally detected appendicular mass on laparoscopy from August 2016 to August 2018. A total of 571 patients were treated for appendicitis the patients underwent laparoscopic appendicectomy. A retrospective review of the patients’ records, while they were in the hospital, demonstrated that 30 patients (5.2%) had an appendicular mass when they were admitted to the hospital. Institutional ethical clearance was obtained.

**Inclusion criteria**

Both genders, all age groups with clinical features of acute appendicitis with incidentally detected appendicular mass on laparoscopy were included.

**Exclusion criteria**

Clinically and sonographically diagnosed cases of appendicular mass, patients with appendicular mass with complications like abscess and peritonitis, patients who test positive for HIV, HBsAg were excluded.

All the operations were performed using the three-trocar technique. Endoscopic pre-tied loops were used for ligation of the base of the appendix. Injection-cefotaxime 50 mg/kg six hourly, amikacin 2.5 mg/kg eight hourly and metronizadole 7.5 mg/kg eight hourly were given intravenously, for five days. All areas of the intra-abdominal collection were aspirated and the peritoneal cavity was rinsed with normal saline. An abdominal drain was kept in 13 patients. Ten patients were discharged on sixth post-operative day, with oral antibiotics (cefixime+metronidazole) for another five days; and nine patients stayed for more than seven days. Data pertaining to sex, age, duration of symptoms, port placement and duration of surgery, drain insertion, orals taken and hospital stay were reviewed.

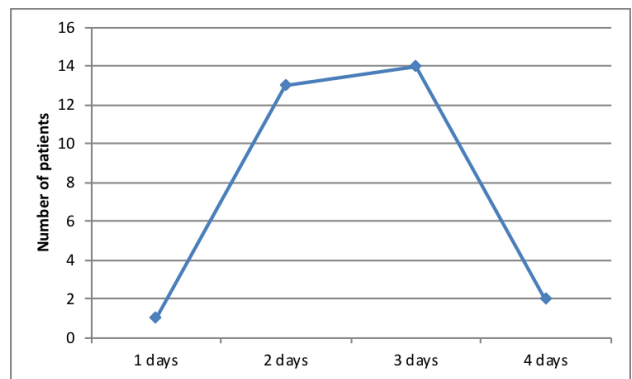
Data entry was done using Microsoft Excel and it was statistically analysed using statistical package for social sciences (SPSS Version 20) for Microsoft Windows. Descriptive statistical analysis was carried out to explore the distribution of several categorical and quantitative variables. Categorical variables were summarized with n (%), while quantitative variables were summarized by mean±S.D. All results were also presented in tabular form and are also shown graphically using bar diagram or pie diagram as appropriate.

**RESULTS**

Maximum cases belong to adolescent age group of 11-20 yrs with 42%. Majority of cases were male patients with 53%.

**Table 1: Demographic distribution in present study (n=30).**

Demographic characteristics	Number of cases	Percentage
<b>Age distribution (in years)</b>		
1-10	4	13.33
11-20	13	43.33
21-30	8	26.66
31-40	4	13.33
41-50	1	3.33
<b>Gender</b>		
Female	16	53
Male	14	47



**Figure 1: Duration of pain in days in patients with appendicitis.**

Most of the cases presented to the hospital on day 2 and 3 of symptoms.

**Table 2: Port placement in different patients (n=30).**

Ports	Number of cases	Percentage
Umbilical, right iliac fossa, left iliac fossa	1	3.33
Umbilical, left iliac fossa, suprapubic	28	93.33
Umbilical, left iliac fossa, suprapubic, right iliac fossa, left lumbar	1	3.33

Left iliac, suprapubic and umbilical ports provided best access to the appendix about 93% of have access.

For majority of the patients surgical procedure took 60 (47%) mins. More complicated dissections took around 1 and half hour. Out of 30 case 27 cases (90%) drain was inserted.

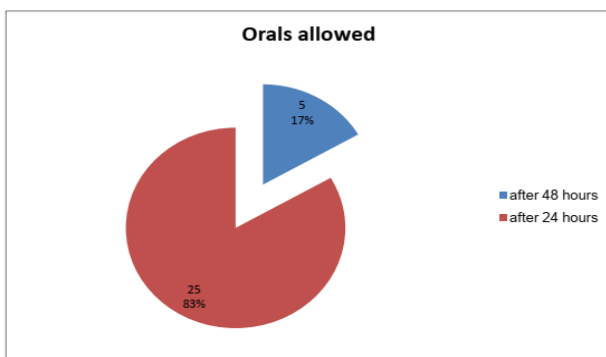
**Table 3: Duration of surgery and drain insertion in present study (n=30).**

Variables	Number of cases	Percentage
<b>Duration of surgery (minutes)</b>		
40	2	6.66
45	4	13.33
50	2	6.66
55	2	6.66
60	14	46.66
70	1	3.33
80	1	3.33
90	4	13.33
<b>Drain</b>		
Not inserted	3	10
Inserted	27	90

**Table 4: Intraoperative and post operative complications (n=30).**

Complications	Number of cases	Percentage
<b>Intra-operative</b>		
Bowel injury ileal serosal tear	1	3.33
Difficult adhesiolysis	5	16.66
Difficult adhesiolysis converted to open	1	3.33
None	23	76.66
<b>Post operative</b>		
None	28	93.33
Port site infection	2	6.66

Intraoperatively out of 30 patients 23 cases (76.7%) have no complications. Post operatively 28 cases have no complications (93%).

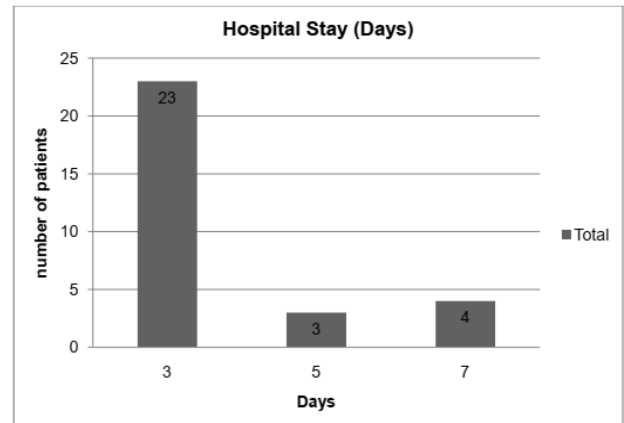


**Figure 2: Resumption of oral diet after surgery.**

Orals were delayed where intraoperative dissection was prolonged or difficult. 25 cases (83%) have orals after 24

hours and 5 cases (17%) were allowed to have after 48 hrs.

Majority of patients were discharged after 3 days i.e. 23 case (76.7%).



**Figure 3: Duration of hospital stay in present study.**

**DISCUSSION**

The 30 cases studied were found to have an appendicular mass on laparoscopy for which Appendicectomy could be safely and successfully proceeded with. Appendicular mass when intervened early, i.e. during the early stage of inflammation, adhesions of appendix with adjacent structures are flimsy and can be brought down easily and safely. This makes appendicectomy at first admission a feasible option, eliminating the need for future hospitalization for recurrence or interval appendicectomy.

The image is transmitted to a 2D video screen by laparoscopy and the laparoscope magnifies the image as much as 16 times its normal size.<sup>4</sup> With laparoscopy, comes the advantage of better visualization and magnification which aids in establishing the diagnosis as well as fine dissection.

Laparoscopy also facilitates finer dissection with fine instruments aiding in safe dissection in complicated presentations of appendicitis. Suction irrigator plays an important role in atraumatic adhesiolysis. The laparoscopic approach has lot of advantages in cases with complicated appendicitis. It allows the surgeon to have a panoramic view of the abdominal cavity, easy accessibility, and feasibility to give a thorough peritoneal lavage in comparison with the open cases where atypical localization of the appendix may require an extension of the incision. Furthermore, laparoscopic approach allows the patient early mobility, less pain and less hospital stay compare to open cases.<sup>5</sup>

Immediate appendectomy has the advantages of being safe, cost effective, eliminates the risk of recurrent appendicitis and thereby the need of the second admission for the interval appendectomy.<sup>6</sup>

Sathyakrishna et al suggest laparoscopic approach as a safe and feasible approach as in their study they could successfully carry out laparoscopic appendectomy in 11 out of 14 cases.<sup>6</sup>

Vishwanath et al believe early operation has an edge of being curative in the index admission and ensures early return- to-work and higher compliance.<sup>7</sup> Agarwal et al advocate operative initial appendectomy and report the advantages of immediately excluding other masquerading conditions, as well as providing a definitive treatment at the initial admission.<sup>8</sup>

Patients of all ages were included in the study. The age at presentation ranged from 6-50 years. Majority of the patients were adolescents belonging to the age group of 11-20 years. A total of 13 adolescents present with early appendicular mass. 8 patients belonged to 21-30 years age group. There is an equal distribution of 4 patients in 1-10 year and 31-40 years age groups. The oldest patient was 50 years old.

In this study of 30 patients, 6 were female and 24 were male. Male to female ratio was being 4:1.

The study by Bahram, also reflects similar age and sex distribution. In this study, 46 patients were included (31 male and 15 female), their ages ranged from 12 to 48 years with the mean age was  $24 \pm 8.76$  years. The incidence of appendicular mass is significantly higher in males than females ( $p < 0.005$ ).<sup>6</sup>

The study, laparoscopic management of appendicular mass by Shindholimath et al also had similar incidence in its study population.<sup>7</sup> During the study period 19 laparoscopic appendectomies were performed for appendicular mass. There were thirteen male and six female patients in this series; the male-to-female ratio was 2:1. The patients ranged in age from 12 to 45 years.<sup>4</sup>

In the study by Sathyakrishna et al, early surgical management of appendicular mass: a retrospective analysis, 14 patients had appendicular mass in which 11 cases were managed laparoscopically and 3 were converted to open. The ages of the patient were in the range of 12-67 years, 9 patients were male and 5 patients were female.<sup>6</sup>

In Agrawal et al study, 52 patients were diagnosed with appendicular mass, of whom 4 had had misdiagnosis.<sup>8</sup> The remaining 48 patients were confirmed to have appendicular mass intraoperatively and were included in the analysis. There were 30 males and 18 females, with ages ranging 7-13 years (mean age was 9 years).

In this study 29 patients were treated with insertion of 3 ports. 28 of them had ports inserted in the umbilical region, left iliac fossa and suprapubic region. 1 patient had a working port located in the right iliac fossa instead of suprapubic region. Camera was accommodated in the

Umbilical port through a 5 or 10 mm port. 1 patient needed 5 ports, the additional ports being in the right iliac fossa and left lumbar region to facilitate difficult adhesiolysis.

Sathyakrishna et al used standard three-port technique.<sup>6</sup> Open technique was used to put in the first (umbilical) port. Harmonic scalpel was the energy source used in all the cases. Catgut endoloops were used to ligate the base of the appendix. After appendectomy, the abdominal collection is aspirated, and the peritoneal cavity is thoroughly washed with normal saline. An abdominal drain was kept in all the cases.

In this study majority of the surgeries i.e. 14 cases, took 60 minutes for completion. Average duration of surgery being 60.667 minutes. Minimum time taken was observed to be 40 minutes while appendicular masses requiring extensive adhesiolysis took 90 minutes.

It can be observed that successful appendectomy can be performed in cases of appendicular mass within an hour as per this study, delay expected proportionate to the extent of adhesions. Agarwal et al reported duration of procedure 72 min.<sup>8</sup> The average operative time was 95 minutes (range 45-140 minutes) in Vishwanath et al study.<sup>4</sup> The average operative time 1 hr 40 min in Sathyakrishna et al study.<sup>6</sup> Senapathi et al observed an operating time of 45 (36-60) minutes in their study.<sup>9</sup>

#### ***Intra operative complications***

Majority of the cases did not have intra-operative complications (77%). In 7 cases, surgeons experienced difficulty during surgery. Hence, in this study, the intra-operative complication rate was 23%.

6 of the cases had extensive and thicker adhesions which mandated more precise and careful dissection. Irrigation with saline helped in separating adhesions in most of the cases. Others require precise dissection with laparoscopic instruments and use of bipolar electrocautery. In 1 case with extensive adhesions, laparoscopic adhesiolysis was not possible and hence the case was converted to open surgery.

In 1 case, during adhesiolysis, the adjacent Ileum suffered a serosal tear which was repaired Laparoscopically with endosutures. Intraoperative and post-operative course of this patient was uneventful. In Bahram study, there was difficulty with adhesiolysis and localization of the appendix in 10% (4) of patients.<sup>10</sup>

In the Vikesh et al's study, post-operative complications were found in 4 (8.33%) patients; among these, major complication was observed in only 1 patient (2.08%) in the form of pelvic abscess and adhesive obstruction, which was managed non-operatively.<sup>8</sup>

In 83% cases orals were allowed on post operative day 1. For 5 cases sips of clear fluids were allowed on post operative day 3. These 5 cases (17%) had extensive adhesions intraoperatively and oral diet was delayed and so was drain removal. This finding is consistent with Vikesh et al study.<sup>8</sup> The average time to resumption of diet 2 (range 1-3) days in Vikesh et al study.<sup>8</sup>

Patients were discharged after resumption of orals and passage of stools following which drains were removed. Most of the patients 23 (76.67%) were discharged on day 3 postoperatively.

3 cases were discharged on post op day 5 and 7 were discharged on postop day 7. The delay is attributed to delay in return of satisfactory bowel movements due to post operative ileus which was managed conservatively with serum potassium monitoring and supplementation when needed. 1 case which was discharged on the 5<sup>th</sup> day developed superficial port site infection which was managed with oral antibiotics.

These findings are similar to the following studies' observations. The average length of hospital stay in conservative approach is a little more compared to one time early surgical approach, with a further second admission required for interval appendectomy. The length of hospital stay in our study was 6-8 days.<sup>2</sup> The mean hospital stay was 3±0.25 day in Bahram study.<sup>10</sup> Duration of stay was 3 days in Vikesh et al study.<sup>8</sup> Senapati et al discharged the patients who underwent laparoscopic appendectomy for appendicular mass in 1-2 days, median of 2 days.<sup>9</sup>

Superficial port site infection was observed in 2 (6.6%) patients at the umbilical port site. 1 was diagnosed during index admission and 1 during follow up on day 7 for suture removal. Both the cases were managed with oral antibiotics. The infection was probably due to contamination of port site during appendix specimen retrieval.

Superficial wound infection had occurred in 8 (17%) while deep wound infection had occurred in 4 (9%) patients. No major complications had occurred in Bahram study.<sup>10</sup>

In Vishwanath et al study three patients (15.7%) had post-operative complications. Two patients developed wound infections and one patient was re-admitted with pain and a lump below the umbilical port.<sup>7</sup> No wound infections and post operative complications were reported by Senapati et al study.<sup>9</sup>

The findings of this study are similar to other studies which support laparoscopic appendectomy in appendicular mass with safe dissection of inflamed appendix mass, successful removal of appendix, early return to home and normal activity in most of the cases

and with low incidence of intra-op and post-op complications. Hence, laparoscopic appendectomy in early appendicular mass is a safe and feasible treatment option.

## CONCLUSION

With immediate operative management of appendicular mass presenting in early stages of inflammation, dissection can be safely proceeded with and appendectomy can be safely performed eliminating the need for second hospitalization and risk of recurrence.

The incidence of intra-operative and post-operative complications is low making laparoscopic appendectomy in early appendicular mass a safe and feasible treatment option.

*Funding: No funding sources*

*Conflict of interest: None declared*

*Ethical approval: The study was approved by the Institutional Ethics Committee*

## REFERENCES

1. De U, Ghosh S. Acute appendectomy for appendicular mass: A study of 87 patients. Ceylon Med J. 2002;47:117-8.
2. Janik JS, Ein SH, Shandling B, Simpson JS, Stephens CA. Nonsurgical management of appendiceal mass in late presenting children. J Paediatr Surg. 1980;15:574-6.
3. Garg P, Dass BK, Bansal AR, Chitkara N. Comparative evaluation of conservative management versus early surgical intervention in appendicular mass: A clinical study. J Indian Med Assoc. 1997;95:179-80.
4. Williams GR. Presidential Address: A History of Appendicitis. Ann Surg. 1983;197(5):495-506.
5. Philipose KJ. Laparoscopic Surgery. Med J Armed Forces India. 1994;50(2):137-43.
6. Sathyakrishna BR. Early Surgical Management of Appendicular Mass: A Retrospective Analysis. Int J Scientific Study. 2016;4(8):91-4.
7. Vishwanath V Shindholimath: Laparoscopic management of appendicular mass. J Minim Access Surg. 2011;7(2):136-40.
8. Agrawal V. Early laparoscopic management of appendicular mass in children: Still a taboo, or time for a change in surgical philosophy? J Minimal Access Surg. 2016;12(2):98-101.
9. Senapati PSP. Early laparoscopic appendectomy for appendicular mass. Surgical Endoscopy Other Interventional Techniques. 2002;16(12):1783-5.
10. Bahram MA. Evaluation of early surgical management of complicated appendicitis by appendicular mass. Int J Surg. 2011;9(1):101-3.

**Cite this article as:** Ramesh K, Janapareddy KK. Role of laparoscopic appendectomy in management of early appendicular mass. Int Surg J 2020;7:2337-41.