

Case Report

Stuttering priapism post C-spine schwannoma excision: case report

Ngwobia Peter Agwu^{1*}, Ali Lasseini²

¹Urology Unit, Department of Surgery, ²Department of Neurosurgery, Usmanu Danfodiyo University Teaching Hospital, Sokoto, Nigeria

Received: 01 June 2020

Revised: 30 July 2020

Accepted: 10 August 2020

*Correspondence:

Dr. Ngwobia Peter Agwu,
E-mail: npagwu@gmail.com

Copyright: © the author(s), publisher and licensee Medip Academy. This is an open-access article distributed under the terms of the Creative Commons Attribution Non-Commercial License, which permits unrestricted non-commercial use, distribution, and reproduction in any medium, provided the original work is properly cited.

ABSTRACT

Priapism is prolonged penile erection that persists beyond or is unrelated to sexual stimulation and this is associated with significant psychological, socioeconomic and physical morbidity. It is a urologic emergency as delayed intervention may result in penile fibrosis and consequent erectile dysfunction. The aim of this paper is to present our experience in the management of the rare occurrence of stuttering priapism in a 32 years old man following surgical excision of cervical schwannoma during the early postoperative period and review relevant literature on management of this urologic entity. Stuttering priapism may complicate cervical spine tumor excision but may demonstrate complete patient recovery.

Keywords: Abnormal erectile physiology, Cervical spine trauma, Prevention, Pharmacologic therapy

INTRODUCTION

Priapism which is prolonged penile erection that persists beyond or is unrelated to sexual stimulation is associated with significant psychological, socioeconomic and physical morbidity.¹ It is a urologic emergency as delayed intervention may result in penile fibrosis and consequent erectile dysfunction. Stuttering priapism is a variant of ischaemic type and is characterized by episodes of painful erections lasting less than four hours. It has commonly been reported in patients with sickle cell disease.² Priapism though a predominantly a male affliction has been rarely reported in females.³

We present our experience in the management of a 32 years old man who developed stuttering priapism in our practice following surgical excision of cervical spine schwannoma that occurred during the early postoperative period and to review the relevant literature on the aetiology, pathogenesis and management of stuttering priapism.

CASE REPORT

We are presenting the clinical case of Mr. MM, a 32 years old male patient who was seen and evaluated at the neurosurgery clinic with complaints of gradual and progressive weakness of all the limbs associated with paraesthesia for over 14 months. He had no previous history of trauma to the neck and no other complaints. He had no history of hypertension, diabetes, mellitus, bronchial asthma or previous surgery and had no history of symptoms suggestive of sickle cell disease. He did not smoke cigarettes or consume alcoholic beverages. There was no documented history of drug allergies.

Clinical examination revealed a young male patient, wheel chair-bound, not in any obvious distress, blood pressure was 120/80 mmHg, pulse rate of 88 beat per minute. The chest was clinically clear. The abdomen and pelvis were normal. Neurologic examination revealed power of 2/5 in all the limbs, global hypertonia and sustained provoked knee and ankle clonus bilaterally. He had normal muscle bulk and normal skin.

Basic investigations that included urinalysis, full blood count, electrolyte, urea and creatinine, clotting profile, chest X-ray and abdominal ultrasound and all these tests were all normal.

Cervical spine magnetic resonance imaging (MRI) showed an intra-dural, extramedullary lesion spanning from C3 to C6. The lesion was isointense on T1, hyperintense on T2 and had homogeneous enhancement on contrast injection. He had cervical laminectomy under general anaesthesia with complete tumour excision.

He was admitted into the intensive care unit (ICU) and on the day 2nd post-operative he started having recurrent penile erections up to a total of 4 episodes at intervals of time varying from 1 to 3 hours. The urologist was invited and who made a diagnosis of stuttering priapism. In addition to the continuation post-operative intravenous fluids, he had aspiration of the corpora cavernosa with the resultant penile detumescence. There were no more episodes of penile erections. He underwent post-operative physiotherapy for the quadriplegia for which he showed full recovery of power in all the limbs nine months post operatively. Patient during subsequent had normal erectile function. Histology of the surgical specimen concluded it to be that of schwannoma.

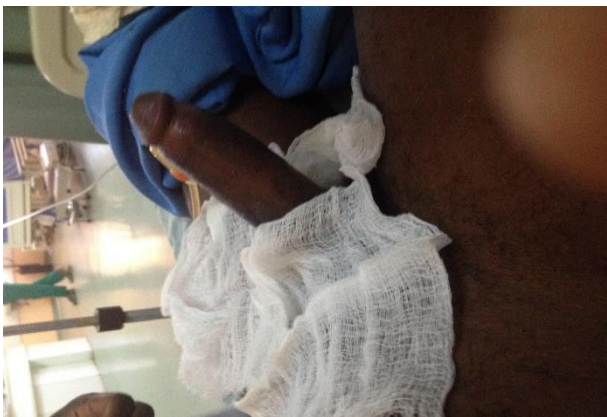

Figure 1: Stuttering priapism with erect penis.

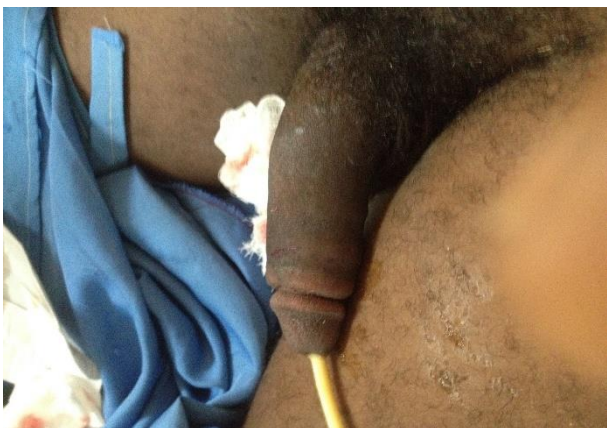


Figure 2: Penile detumescence after corporal aspiration.

DISCUSSION

Normal penile erection is due to complex physiologic processes that result from inter-play of vascular, neural, endothelial, humoral, hormonal and smooth muscle events arising from auditory, visual, olfactory as well as penile stimulation.⁴ Penile erection is initiated by activation of the parasympathetic nerves upon sexual stimulation which causes vasodilatation of the cavernous helicine arteries and relaxation of the trabecular smooth muscles.⁵ Research in this century has led to identification of key neurotransmitters and signalling pathways such, as nitric oxide, adenosine, melanotropic peptides, and endogenous urotensin II.⁶⁻⁹ Priapism represents an abnormality of the normal penile erection and results from a combination of disturbances involving the regulatory mechanisms that control penile tumescence, detumescence and the maintenance of penile flaccidity state and may be due to excess release of contractile neurotransmitters, malfunction of the intrinsic detumescence mechanism, obstruction of draining venules or prolonged relaxation of intra-cavernous smooth muscles.¹ Stuttering priapism which may also be termed recurrent or intermittent type is characterized by recurrent/repetitive episodes of unwanted, persistent, painful penile erections with intervening periods of detumescence with each episode lasting less than four hours.¹⁰ The recurrent episodes of stuttering priapism in the patient sometimes may increase in frequency and duration and thus progress to major episodes of ischaemic events with the resultant penile fibrosis and erectile dysfunction and therefore the need for emergent treatment.

Stuttering priapism is an erectile disorder that occurs mainly in the male as was found in our index patient, however, this disorder has been rarely reported in females and manifests as prolonged erection of the clitoris leading to clitoral engorgement, swelling of the clitoris and vulval pain.³ Stuttering priapism has been reported mainly in association with haematologic diseases such as sickle cell disease, glucose-6-phosphate dehydrogenase deficiency, hereditary spherocytosis and the use of psychoactive drugs.¹¹⁻¹³ Priapism resulting from acute spinal cord injury have been reported to be of the non-ischaemic variety and may be managed conservatively.^{14,15} However, priapism due to neurosyphilis, sickle cell disease, leukaemia are usually of the ischaemic type.⁶⁻¹⁹

In our index patient, there was no clinical evidence of sickle cell trait or the disease and the episodes of stuttering priapism occurred only after excision of the cervical spinal tumor. Neurological diseases such as trauma and infection have been implicated as probable causes of stuttering priapism in some reports.²⁰ Gottsch et al in their series found that the second most common comorbid condition that manifests as priapism was neurologic injury as a result of acute central nervous system injury.²¹ Priapism in this setting results from the

pathologic stimuli of the cervical spinal cord from acute injury or surgery as was present in our index patient.²² However, several patients presenting with priapism have been found not to have any distinct aetiology leading these referred to as idiopathic priapism.²³

Management of stuttering priapism has been a therapeutic challenge to the urologists as most treatment modalities have not demonstrated consistent efficacy. The goal of the management of a patient with stuttering priapism is the prevention of future episodes, while the management of each episode should follow the specific treatment recommendations for acute ischaemic priapism. The management of the patient can be achieved by surgical intervention, hormonal manipulation, and pharmacotherapy by increasing corpus cavernosum smooth muscle tone.²⁴

Management of the patient with ischaemic priapism that is as a result of worsening of the stuttering state is similar to that of ischaemic priapism which comprises of a step-wise algorithm of corporal aspiration, irrigation combined with intra-cavernous alpha adrenergic agonists and the creation of distal to proximal shunts.¹¹ Our index patient only had corporal aspiration which resulted in penile detumescence and there was non-recurrence of the priapic state. However, in patients in whom initial corporeal aspiration and intra-cavernous alpha-adrenergic agonists irrigation fail, creation of distal cavernosal shunts becomes necessary to preserve penile structural and functional integrity.²⁵

A modified technique of treatment of recurrent priapism that involves combined creation of a Winter's shunt and continuous cavernosal saline irrigation without the addition of alpha receptor agonist has been described.²⁶

Use of oral systemic pharmacologic agents in the management of stuttering priapism aim at preventing additional episodes that may progress to major events through hormonal manipulations and increasing the tone of the smooth muscle of the corpus cavernosum.²⁴

The primary goal of hormonal therapies for stuttering priapism is suppression of serum testosterone which has been known to have central or peripheral action in controlling the priapic state.²⁷ These hormonal agents include oestrogens in form of stilbesterol, gonadotropin releasing hormone agonists (GnRH), alpha reductase inhibitors, anti-androgens, and ketoconazole.²⁸⁻³² Antiandrogens including flutamide and bicalutamide bring suppress testosterone action by direct suppression of androgen receptors.³¹ Dutasteride and finasteride, both of which are 5 alpha reductase inhibitors inhibit the conversion of testosterone to the more metabolically active dihydrotestosterone and these molecules have been utilized in the long-term prevention of stuttering priapism.³⁰

Ketoconazole, an anti-fungal agent, due its inhibition of testicular and adrenal androgens synthesis has been used singly or in combination with prednisone in a reported case series of patients with recurrent ischaemic priapism.³²

The draw-back to the long-time use of hormonal agents in the management of stuttering priapism is the occurrence of substantial adverse effects such as erectile dysfunction, loss of libido, gynaecomastia, metabolic and cardiovascular complications.³³

Other pharmacological therapies which act by increasing corpus cavernosum smooth muscle tone have been investigated and applied in treating and preventing the occurrence of stuttering priapism. Phosphodiesterase type (PDE-5) inhibitors have been administered at low doses to control occurrence of recurrent ischaemic priapism in sickle cell disease patients.³⁴ A double-blind placebo controlled study that involved administration of 50 mg of sildenafil to sickle cell disease subjects with recurrent ischaemic priapism demonstrated a four-fold reduction in priapism in those subjects who had adhered to their drug treatment though the result of the study did not demonstrate a statistically significant difference with the placebo group.³⁵

Digoxin, is a cardiac glycoside that acts to inhibit smooth muscle sodium-potassium ATPase thus preventing efflux of calcium from the cell thus increases the intracellular calcium level with the resultant smooth muscle contraction and penile tumescence.³⁶ Digoxin impairs nitric oxide mediated smooth relaxation of the human corpus cavernosum. However, its side effects profile and the need for regular blood level monitoring may preclude it from being of first-line use in patients with prolonged recurrent episodes of stuttering priapism.³⁷

Terbutaline is a beta-2 agonist that causes relaxation of vasculature smooth muscles. In the sickle disease patient, it promotes oxygenated arterial blood flow in the cavernosa thus washing out stagnant sickle cells.²⁷ Oral terbutaline has been used in the treatment of stuttering priapism either of the idiopathic or pharmacologically induced varieties.³⁸

Certain patients may present with recurrent priapism that is refractory to the usual pharmacologic agents mentioned above. In such patients, baclofen, a centrally acting gamma amino butyric acid B agonist usually administered in the treatment of spasticity in patients with upper neurone syndromes becomes useful in such cases.³⁹

Gabapentin, an anticonvulsant, antinociceptive and anxiolytic agent that has been reported used in the treatment of recurrent refractory idiopathic priapism as it was administered in titrated doses beginning from 400 mg six hourly to a total of 2400 mg daily with complete resolution of the priapism.⁴⁰

CONCLUSION

Stuttering priapism mainly result from haematological disorders but rarely from neurological trauma to the cervical spine. Conservative management and corporal aspiration and irrigation may suffice for some patients. However, for treatment of refractory cases and in the prevention of future episodes of priapism, an array of hormonal and pharmacological therapies is available.

Funding: No funding sources

Conflict of interest: None declared

Ethical approval: Not required

REFERENCES

- Levey HR, Segel RL, Bivalacqua TJ. Management of priapism: an update for clinicians. *Adv Urol.* 2004;6:230-44.
- Kato GJ. Priapism in Sickle cell disease: a haematologist's perspective. *J Sex Med.* 2012;9:70-8.
- Medina CA. Clitoral priapism: A rare condition presenting as a case of vulvar pain. *Obstet Gynecol.* 2002;100:1089-91.
- Driel VMF. Physiology of penile erection- a brief history of scientific understanding up till eighties of the 20th century. *Sex Med.* 2015;3:349-57.
- Prieto D. Physiological regulation of penile arteries and veins. *Int J Impotence Res.* 2008;20:17-29.
- Garthwaite J. Concepts of neural nitric oxide-mediated transmission. *European J Neurosci.* 2008;27:2783-802.
- Phatarpekar PV, Wen J, Xia Y. Role of Adenosine signalling in Penile Erectile Disorders. *J Sex Med.* 2010;7:3553-64.
- King SH, Mayorov AV, Srinivasar BP, Hruba VJ, Vanderah TW, Wessels H. Melanocortin Receptors, Melanotropic Peptides and Penile Erection. *Curr Top Med Chem.* 2007;7:1098-106.
- D'Emmanuele DVBR, Mitidieri E, Fusco F, D'Aiuto E, Griew P. Endogenous Urotensin II selectively Modulates Erectile Function through eNos. *PLOS ONE.* 2012;7:e31019.
- Basset J, Rajfar J. Diagnostic and Therapeutic Options for the management if ischaemic and non-ischaemic priapism. *Reviews Urology.* 2010;12:56-63.
- Burnett AL, Bivalacqua TJ. Glucose-6-Phosphate Dehydrogenase Deficiency: An Etiology for Idiopathic Priapism? *J Sex Med.* 2008;5:237-40.
- Prabhakaran K, Jacobs BL, Smaldone MC, Franks ME. Stuttering priapism associated with hereditary spherocytosis. *Can J Urol.* 2007;14:3702-4.
- Baytunca MB, Kose S, Ozbaran B, Erermis S. Risperidone, quetiapine and chlorpromazine may have induced priapism in an adolescent. *Pediatr Int.* 2016;58(1):61-3.
- Todd NV. Priapism in acute spinal cord injury. *Spinal Cord.* 2011;4:1033-5.
- Gordon SA, Stage KH, Tansey KEC, Lotan Y. Conservative management of priapism in acute spinal cord injury. *Urology.* 2005;65:1195-7.
- Kim DW, Chae JY, Kim JW, Yoon CY, Oh MM, Kim JJ, et al. Stuttering Priapism in a patient with Neurosyphilis. *World J Men Health.* 2013;31:76-8.
- Akinbani A, Uche E, Dosunmu A. Priapism in sickle cell disease: Emergency room intervention. *Ann Trop Path.* 2017;8:5-10.
- Nerli RB, Magduma PV, Hiremath SC, Patil AY, Pai SV, Handigund RS, et al. Priapism: A Rare Presentation in Chronic Myeloid Leukemia: Case Report. *Urology Case Reports.* 2016;4:8-10.
- Musa AU, Ndakotsu MA, Abubakar SB, Agwu PN. Chronic myeloid leukemia with an initial presentation as ischemic priapism: a case report and review of literature. *Arch Int Surg.* 2017;7:68-72.
- Ravindran M. Cauda equine compression presenting as spontaneous priapism. *J Neurology Neurosurg Psychiatry.* 1979;42:280-2.
- Gottsch HP, Berger RE, Yang CC. Priapism: Comorbid Factors and Treatment Outcomes in a Contemporary Series. Hindawi Publishing Corporation *Advances Urology.* 2012;21:518-22.
- Tscholl R. Priapism pathogenesis and therapy. *Schweiz Med Wochenschr.* 1975;105(17):517-21.
- Pohl J, Pott B, Kleinhans G. Priapism: A Three-phase Concept of Management According to Aetiology and Prognosis. *British J Urology.* 1986;58:113-8.
- Kheirandish P, Chingewundoh F, Kulkarni S. Treating stuttering priapism. *BJU Int.* 2011;108:1068-72.
- Raslan M, Hiew K, Hoyle A, Ross DG, Betts CD, Madidineni SB. Durgical management of stuttering ischaemic priapism: a case report and concise clinical review. *Urology Case Reports.* 2016;5:22-4.
- Chen W, Sun SB, Sun LA, Guo JM, Wang GM. Modified technique in treating recurrent priapism: a technique report. *Asian J Andrology.* 2015;17:329-31
- Kousournas G, Muneer A, Ralph D, Zacharakis E. Contemporary best practice in the evaluation and management of stuttering priapism. *Ther Adv Urolo.* 2017;9(10):227-38.
- Serjeant GR, Ceulaer DK, Maude GH. Stilboestrol and Stuttering Priapism in Homozygous Sickle-Cell Disease. *Lancet.* 1985;2(8467):1274-6.
- Yi Y, Malaeb B. Case: Temporary chemical castration in the management of recurrent priapism. *Can Urol Assoc J.* 2018;12(5):265-6.
- Levine LA, Guss SP. Gonadotropin- releasing hormone analogues in the treatment of sickle cell anemia-associated priapism. *J Urol.* 1993;150:475-7.
- Baker RC, Bergeson RL, Yi YA, Ward EE, Morey AF. Dutasteride in the long-term management of stuttering priapism. *Transl Androl Urol.* 2020;9(1):87-92.

32. Dahm P, Rao DS, Donatucci CF. Antiandrogens in the treatment of priapism. *Urology.* 2002;59:138.
33. Hoeh MP, Levine LA. Prevention of recurrent ischemic priapism with ketoconazole: Evolution of a treatment protocol and patient outcomes. *J Sex Med.* 2014;11:197-204.
34. Morrison B, Biurnett AL. Stuttering priapism: Insights into pathogenesis and management. *Curr Urol Rep.* 2012;13:268-76.
35. Burnett AL, Bivalacqua TJ, Champion HC, Musicki B. feasibility of the use of phosphodiesterase-5 inhibitors in a pharmacologic prevention program for recurrent priapism. *J Sex Med.* 2006;3:1077-84.
36. Burnett AL, Anele UA, Ain T, Strouse JJ, Casella JF. Randomized controlled trial of sildenafil for preventing recurrent ischaemic priapism I sickle cell disease. *Am J Med.* 2014;127(7):664-8.
37. Gupta S, Salimpour P, De'Tejada IS, Daller M, Kraze RJ, Trash AM, et al. A possible mechanism for alteration of human erectile function by digoxin: Inhibition of corpus cavernosum Na-K ATPase activity. *J Urol.* 1998;159:1529-36.
38. Priyadarshi S. Oral terbutaline in the management of pharmacologically induced prolonged erection. *Int J Impotence Res.* 2004;16:424-6.
39. Vaidyanathan S, Watt JWH, Singh G, Hughes PL, Selmi F, Oo T, et al. Management of recurrent priapism in a cervical spinal cord injury patient with oral baclofen therapy. *Spinal Cord.* 2004;42:134-5.
40. Perimenis P, Athanosopoulos A, Barbalias G. Gabapentin in the management of recurrent refractory idiopathic priapism. *Int J Impotence Res.* 2004;16:84-5.

Cite this article as: Agwu NP, Lasseini A. Stuttering priapism post C-spine schwannoma excision: case report. *Int Surg J* 2020;7:3077-81.