

Original Research Article

A study of incidence of inguinodynia in inguinal hernias repair at a tertiary center

Dinesh Prasad, Yash Patel*

Department of General Surgery, SMIMER, Surat, Gujarat, India

Received: 31 May 2020

Revised: 12 July 2020

Accepted: 15 July 2020

***Correspondence:**

Dr. Yash Patel,

E-mail: yashpatel55555@gmail.com

Copyright: © the author(s), publisher and licensee Medip Academy. This is an open-access article distributed under the terms of the Creative Commons Attribution Non-Commercial License, which permits unrestricted non-commercial use, distribution, and reproduction in any medium, provided the original work is properly cited.

ABSTRACT

Background: Chronic groin pain (inguinodynia) following inguinal hernia repair is a significant, though under-reported problem. Mild pain lasting for a few days is common following mesh inguinal hernia repair. However, moderate to severe pain persisting more than 3 months after inguinal herniorrhaphy should be considered as pathological. The main aim of this study was to assess the incidence of inguinodynia in inguinal hernia repair patients at a tertiary centre.

Methods: This non-randomized retrospective study was undertaken in the department of general surgery, SMIMER Hospital, Surat, Gujarat, India from August 2016 to July 2019. Total 940 patients were operated for inguinal hernia repair during this period. Out of these 940 patients, only 460 patients could be traced for clinical evaluation as Surat is an industrial city with very high percentage of migrant population and so only, they were included in the study.

Results: In this study, total 460 patients were included, in which 310 patients were operated for open inguinal hernia repair and 150 patients were operated for laparoscopic hernia repair. Total 102 (22.17%) patients has developed inguinodynia out of 460 patients evaluated in this series. Incidence of inguinodynia is more in open inguinal hernia repair than laparoscopic inguinal hernia repair i.e., 24.83% versus 16.67%. Incidence of testicular complication in inguinodynia patients is more in open inguinal hernia repair and non in laparoscopic repair.

Conclusions: Authors conclude that overall incidence of inguinodynia is 22.17% and incidence of inguinodynia is higher in open hernia repair in comparison to laparoscopic hernia repair (24.83% versus 16.67%). The incidence of mild inguinodynia is approximately eight times more common than severe inguinodynia.

Keywords: Inguinodynia, Laparoscopic transabdominal preperitoneal, Laparoscopic totally extraperitoneal, Lichtenstein's inguinal hernia mesh repair

INTRODUCTION

Chronic groin pain (inguinodynia) following inguinal hernia repair is a significant, though under-reported problem. Mild pain lasting for a few days is common following mesh inguinal hernia repair. However, moderate to severe pain persisting more than 3 months after inguinal herniorrhaphy should be considered as pathological. The major reasons for chronic groin pain have been identified as neuropathic cause due to inguinal

nerve(s) damage or non-neuropathic cause due to mesh or other related factors. The symptom complex of chronic groin pain varies from a dull ache to sharp shooting pain along the distribution of inguinal nerves. Thorough history and meticulous clinical examination should be performed to identify the exact cause of chronic groin pain, as there is no single test to confirm the etiology behind the pain or to point out the exact nerve involved. Various studies have been performed to look at the difference in chronic groin pain rates with the use of mesh versus non-mesh repair, use of heavy-weight versus

lightweight mesh and mesh fixation with sutures versus glue. Though there is no convincing evidence favoring one over the other, lightweight meshes are generally preferred because of their lesser foreign body reaction and better tolerance by the patients. Identification of all three nerves has been shown to be an important factor in reducing chronic groin pain, though there are no well conducted randomized studies to recommend the benefits of nerve excision versus preservation. Both nonsurgical and surgical options have been tried for chronic groin pain, with their consequent risks of analgesic side effects, recurrent pain, recurrent hernia and significant sensory loss. By far the best treatment for chronic groin pain is to avoid bestowing this on the patient by careful intra-operative handling of inguinal structures and better patient counselling pre- and post-herniorrhaphy.

The main aim of this study was to assess the incidence of inguinodynia in inguinal hernia repair patients at a tertiary centre.

METHODS

It was a retrospective randomized controlled trial study (CONSORT). This study was undertaken in the department of General Surgery, SMIMER Hospital, Surat, Gujarat, India from August 2016 to July 2019. Total 940 patients were operated for inguinal hernia repair during this period. Out of these 940 patients, only 460 patients could be traced for clinical evaluation as Surat is an industrial city with very high percentage of migrant population and so only, they were included in the study. All 460 patients in the study were interviewed thoroughly on telephone regarding symptoms of inguinodynia and physically examined as when required. All these patients have undergone standard Lichtenstein mesh hernioplasty under SA or laparoscopic hernia repair under GA for inguinal hernia. Post-operative inguinodynia within 3 year was observed. In all patient's poly-propylene heavy had been used. Types of mesh used were heavy weight or light weight depending on supply in the institute. Patients received injection ceftriaxone antibiotic preoperatively and (amoxicillin + clavulanic acid) continued for 5-6 days post-operatively. Patients were specially enquired about symptoms at 6 month and changes in symptoms at 1 year and 3 years.

Inclusion criteria

Inclusion criteria of this study were patients with age >12 years and all patients of reducible inguinal hernia.

Exclusion criteria

All patients of irreducible inguinal hernia were excluded.

Assessment tools used for diagnosing inguinodynia

The symptom complex of chronic groin pain varies from a dull ache to sharp shooting pain along the distribution of inguinal nerves. Walking, twisting or hyperextension

of the hip often triggers the symptoms. They can be relieved by bed rest, sedentary life style or flexion of the thigh. The complex nature of chronic groin pain has led researchers to use diverse measurement tools, thereby leading to difficulty in comparison of the studies. The most frequently used self-rating pain tools the visual analogue scale (VAS). The most commonly used simple assessment tool has been VAS and this uses a scale 10 cm in length, with no pain at 0 to severe pain at 10.

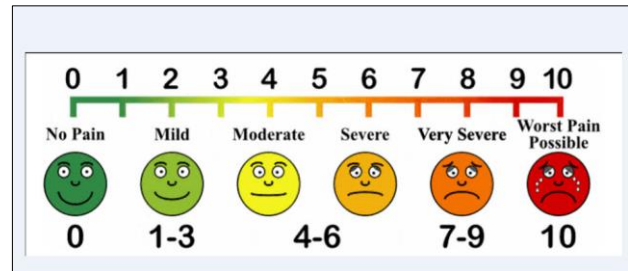


Figure 1: Vas scale of pain.

Neuropathic pain can be reproduced by tapping the skin medial to the antero-superior iliac spine or over an area of tenderness. It is extremely difficult to identify the exact nerve involved in causing the pain because of the overlapping nature of their sensory innervations and peripheral communication between the nerves. All three nerves arise from T12-L1 nerve roots. One, two or all three of them can be involved in the etiology of chronic groin pain, thus making it difficult to pinpoint the entrapped nerve. Clinicians have tried peripheral nerve block or paravertebral block to differentiate the neuropathic pain.

RESULTS

In this study, Total 460 patients were included, in which 310 patients were operated for open inguinal hernia repair and 150 patients were operated for laparoscopic hernia repair. Total 102 (22.17%) patients have developed inguinodynia out of 460 patients evaluated in this series Figure 2 and 3.

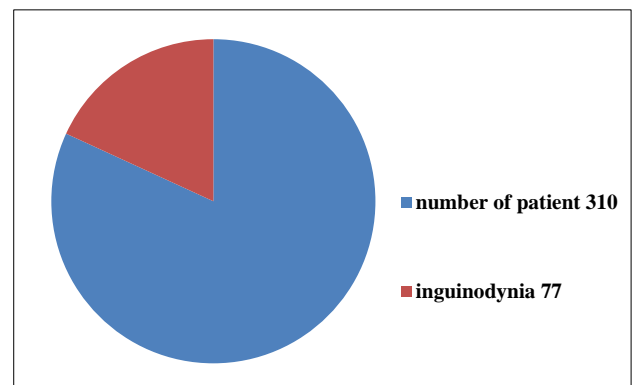


Figure 2: Open hernia repair and development inguinodynia.

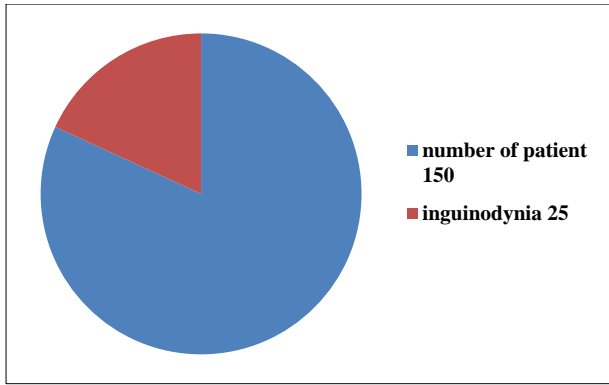


Figure 3: Laparoscopic inguinal hernia repair and incidence of inguinodynia.

In this study, incidence of inguinodynia is more in open inguinal hernia repair (n=77) than laparoscopic inguinal hernia repair (n=25) i.e., 24.83% versus 16.67%.

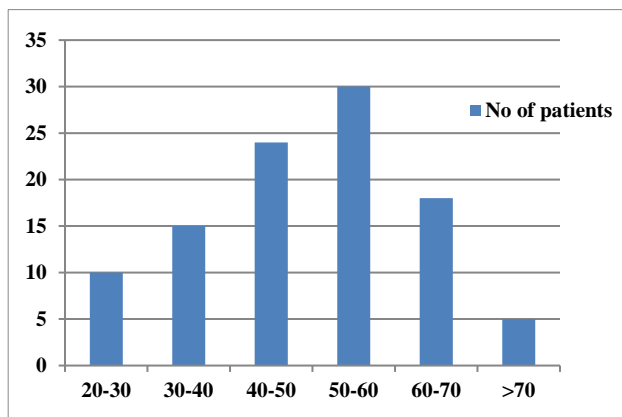


Figure 4: Incidence of inguinodynia in different age group.

In this study, incidence of inguinodynia was highest in 50-60 years age group of patients followed by 40-50 years age group patients. More than 50% patients of inguinodynia fall in the age bracket of 40 years to 60 years Figure 4.

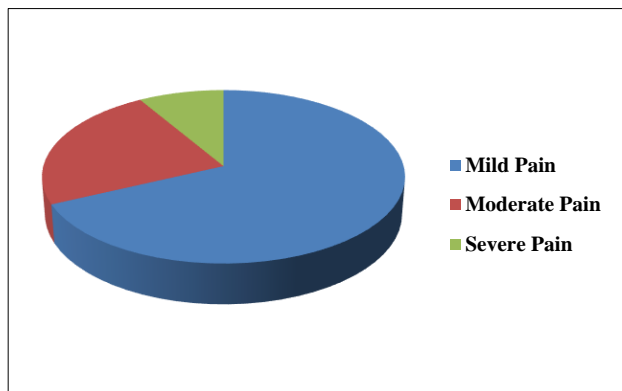


Figure 5: Incidence of severity of pain in patients of inguinodynia.

In this study, 50 out of 102 patients require analgesics on/off. Only 9 out of 102 patients require regular analgesics while 17 out of 102 require analgesics >3 times in a week. None this study patients were willing for surgical correction of inguinodynia.

Table 1: Patients requiring treatment for inguinodynia.

Requirement of analgesics	No. of patients (%)
Daily	9 (09)
>3 times in a week	17 (17)
a<3 times in a week	26 (25)
On/off	50 (49)
Surgery	Nil

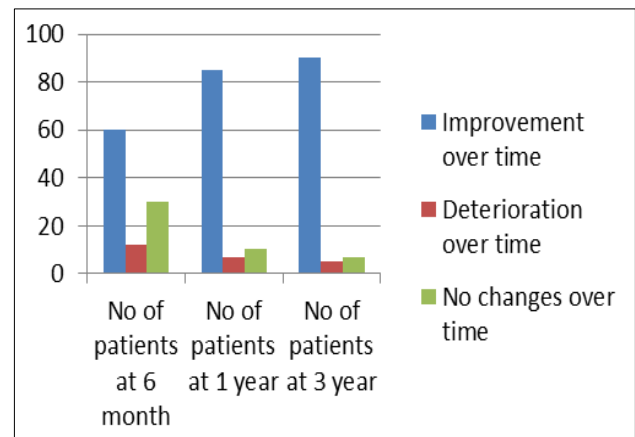


Figure 6: Incidence of pain improvement/deterioration.

In this study, most of patients have improvement of pain over a period of 6 month to 1 year and 1 year to 3-year follow-up Figure 6. None of this study patients have complained of deterioration of pain over follow-up period of 6 month to 3 year. Most of this study patients have shown improvement of inguinodynia over 6 months to 3 years period of follow-up.

In this study, incidence of wound infection in inguinodynia patients is more in open hernia repair (12.98%) than laparoscopic hernia repair (4%).

In this study, incidence of testicular complication in inguinodynia patients is more in open inguinal hernia repair (4.9%) and non in laparoscopic repair.

DISCUSSION

Inguinal hernias comprise 70% to 75% of all abdominal wall hernias and are more common in men, whereas femoral hernias account for less than 5% and are more common in women. Overall, 96% of groin hernias are inguinal and 4% are femoral. These hernias are more common in men. The lifetime risk of developing a groin hernia is 25% in men, but less than 5% in women. Men

are also 20-fold more likely to need a hernia repair. Inguinodynia or post herniorrhaphy pain syndrome is pain or discomfort lasting greater than 3 months after surgery of inguinal hernia. Nerve injuries are an infrequent and underrecognized complication of inguinal hernia repair. Injury can occur from traction, electrocautery, transection, and entrapment. Transient neuralgias involving sensory nerves can occur and are usually self-limited and resolve within a few weeks after surgery. Persistent neuralgias usually result in pain and hyperesthesia in the area of distribution.

In this study, total 460 patients were included, in which 310 patients were operated for open inguinal hernia repair and 150 patients were operated for laparoscopic hernia repair. Total 102 (22.17%) patients were developed inguinodynia from 460 patients.

Normal inguinal nerves anatomy during open inguinal hernia repair

Iliohypogastric nerve arises from the anterior division of L1 nerve runs away from lateral margin of psoas major muscle in front of quadratus lumborum behind kidney and colon to pierce transversus abdominis just above the iliac crest; runs between transversus abdominis and internal oblique; pierces the internal oblique 2.5 cm above the anterior superior iliac spine, run between internal oblique and external oblique to reach 2.5 cm above the superficial inguinal ring where it pierces the external oblique aponeurosis to supply skin around the area.

Ilioinguinal nerve also arises from anterior division of L1 nerve runs over the quadratus lumborum, iliac crest pierces the transversus abdominis 3.5 cm medial to anterior superior iliac spine; runs between transversus abdominis and internal oblique for a short distance to pierce internal oblique just below and medial to iliohypogastric nerve lateral to deep inguinal ring; runs in inguinal canal outside the cord in males or round ligament (in females), passes through superficial inguinal ring; runs in front of the scrotum to supply anterior part of the scrotum.

The genitofemoral nerve arises from ventral divisions of L1, L2 nerves; passes through the medial part of the psoas major muscle running below in front of the muscle; just above the deep ring it divides into medial genital and lateral femoral branches. Genital branch after piercing the psoas sheath runs in front of the external iliac artery and passes through deep ring to enter the inguinal canal within the spermatic cord in males or round ligament in females. It supplies cremaster muscle, runs in the cord to reach anterolateral aspect of the scrotum and supplies that part. In females it gives sensory branches to round ligament and labia majora. Femoral branch passes along with the femoral artery to supply skin over the femoral triangle.

Normal inguinal nerves anatomy during laparoscopic inguinal hernia repair

Triangle of doom should be identified and care should be taken while dissecting in this area. Laterally dissection is done up to anterior superior iliac spine adequately along the iliopsoas to create needed space to place large mesh. Triangle of pain should be kept in mind as not to injure lateral femoral cutaneous nerve and femoral branch of genitofemoral nerve.

Chronic groin pain (inguinodynia) is a potential complication following inguinal hernia mesh repair and has significant impact on the quality of life.¹ The incidence varies among studies, ranging between 0% and 62.9%, with 10% of patients fitting in the moderate to severe pain group.²⁻⁶ However, only 2%-4% of the patients are adversely affected by chronic groin pain in their everyday life. This is significant, considering the volume of the operations performed worldwide.⁷ Management of chronic groin pain constitutes challenging issues for the clinician. Additionally, it has an impact on the health system and economy. In this review, we highlight various aspects of chronic groin pain (inguinodynia) following inguinal hernia repairs.

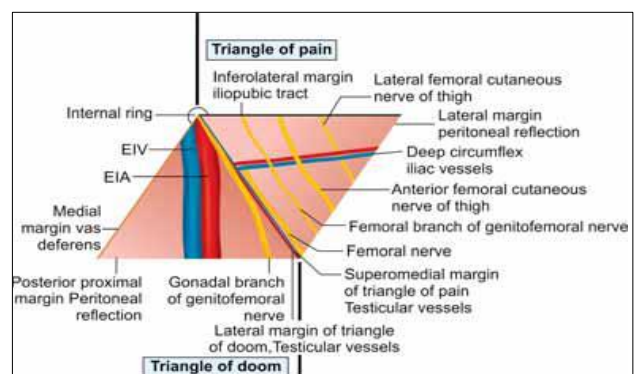


Figure 7: Triangle of pain and doom during laparoscopic inguinal hernia repair.

Lichtenstein's inguinal hernia mesh repair

After cleaning and draping, line of skin incision is marked using marking pen at 1.25 cm above and parallel to the medial 2/3rd of inguinal ligament. Two layers of superficial fascia, outer Camper and inner Scarpa's fascia are incised. Often these superficial epigastric, superficial circumflex, superficial external pudendal veins are ligated. External oblique aponeurosis is identified by its shining fibers. It is exposed above, below up to inguinal ligament and medially up to pubic tubercle and midline. External oblique aponeurosis is incised. Aponeurosis is incised medially and laterally along the line of the incision. Medially it is extended often up to the external ring to open it. Two leaves of the aponeurosis are elevated above to visualize the conjoint tendon and below to visualize the shining inguinal ligament (Poupart's). Iliohypogastric nerve is identified above and

medially which after piercing the internal oblique enters the external oblique. Ilioinguinal nerve is in the inguinal canal outside the cord which enters the canal through a gap between external and internal oblique muscles, passes through superficial inguinal ring. Genital branch of genitofemoral nerve passes through the cord structures. Hernial sac is identified. Sac is pearly white in colour which is anterolateral in position with respect to cord in case of indirect sac, being lateral to inferior epigastric vessels and by presence of extraperitoneal pad of fat. Sac is transfixated high above the internal ring. In direct hernia, sac is medial to inferior epigastric vessels and is usually not opened unless there is obstruction. Cord is kept away below. Polypropylene mesh is used. Mesh is sutured below to the inguinal ligament; medial most sutures are taken from a point very close to the pubic tubercle. Mesh should be sutured with relaxation to bear the forward protrusion pressure of the transversalis fascia during standing. External oblique is sutured using absorbable sutures. Subcutaneous interrupted sutures are placed. Skin is closed.

Laparoscopic transabdominal preperitoneal inguinal hernia repair (TAPP)

An infra-umbilical incision is used to access the peritoneal cavity and a 10-12 mm trocar placed. An angled scope (30 degrees or more) is ideal and is used to place two 5 mm ports either in the midline below the umbilicus or in the midclavicular line bilaterally. The hernia is visualized, and the peritoneum overlying it incised sharply 3-4 cm from the medial umbilical ligament to the anterior superior iliac spine. Blunt dissection can be used to peel the peritoneal flaps inferiorly, exposing the inferior epigastric vessels, the pubic symphysis and the Cooper's ligament, and the iliopubic tract. A direct hernia should be reduced if seen, and an indirect dissected from the cord structures. Femoral and obturator hernias can also be visualized and reduced. Care is taken to avoid the "triangle of doom" containing the external iliac vessels bordered by the vas deferens medially and the gonadal vessels laterally. A mesh size 12×15 cm of polypropylene or polyester is introduced through the sub-umbilical trocar and positioned anterior along the pelvic wall with the center over of the primary hernia defect. Fixation can range from absorbable to non-absorbable tacking devices to the Cooper's ligament and the anterior abdominal wall, or with fibrin sealant, or no fixation at all. The lateral abdominal wall is avoided to prevent entrapment of nerves within the iliopubic tract. The peritoneum is re-approximated with a running suture and ports removed under direct visualization. The fascial defect at the umbilicus is closed under direct visualization.

Laparoscopic total extraperitoneal inguinal hernia repair (TEP)

The operative layout of the total extraperitoneal repair is identical to the TAPP approach. The infra-umbilical

incision in the anterior fascia is made lateral to the linea-alba, and the rectus muscle retracted laterally, exposing the posterior rectus sheath. A balloon dissector can be used, or the laparoscopic cameras, to open up the preperitoneal space under direct visualization. An angled scope can be used to place two 5 mm trocars under direct visualization in the infra-umbilical midline, with the inferior port three fingerbreadths above the pubic symphysis or alternatively two 5.5 mm ports can be placed in mid clavicular line on both side level being slightly lower than camera port. The landmarks and dissection are identical to the TAPP repair. Any inadvertent tears in the peritoneum during dissection can produce a loss of working space. A sutured repair of the defect, or a Veress needle in the upper abdomen to release intra-abdominal pneumoperitoneum, can maintain the preperitoneal working space. If this is not successful, conversion to a TAPP repair would be appropriate.

Table 2: Comparison of inguinodynia incidence with different studies.

Grade of pain	In this study (%)	Callesen's study ⁹ (%)	Scottish Study ¹⁰ (%)
Mild	15.1	19	43
Moderate	5.2	6	3
Severe	1.9		

Table 3: Comparison of inguinodynia incidence in open and laparoscopic hernia repair with other studies.

Type of hernia repair	In this study (%)	Grant's study ¹¹ (%)
Laparoscopic	16.67	24.3
Open	24.83	29.4

In this study, mild, moderate and severe inguinodynia patients' incidence was 15.1%, 5.2% and 1.9% respectively. In Callesen's study, mild and moderate-severe patients' incidence was 19% and 6% respectively.⁹ In Scottish population study, Incidence of mild and moderate-severe inguinodynia was 43% and 3% respectively. Inguinodynia incidence in open vs laparoscopic hernia was 24.83% and 16.67% respectively in this study and 24.3% and 29.4% respectively in Grant's study.¹¹

CONCLUSION

From this study we conclude that overall incidence of inguinodynia is 22.17% and incidence of inguinodynia is higher in open hernia repair in comparison to laparoscopic hernia repair (24.83% versus 16.67%). High incidence of inguinodynia in open surgery group is possibly due to high incidence of wound and scrotal complications apart from other common causes. The incidence of mild inguinodynia is approximately eight times more common than severe inguinodynia. High

percentage of patients have shown tendency towards improvement of inguinodynia over 6 months (58.82%) to 3-year (88.23%) follow-up. Most (50%) of this study patients fall in age group of 40 year to 60 year and require on/off analgesia for pain relief.

Funding: No funding sources

Conflict of interest: None declared

Ethical approval: Not required

REFERENCES

- vanHanswijck de Jonge P, Lloyd A, Horsfall L, Tan R, O'Dwyer PJ. The measurement of chronic pain and healthrelated quality of life following inguinal hernia repair: a review of the literature. *Hernia*. 2008;12:561-9.
- Poobalan AS, Bruce J, King PM, Chambers WA, Krukowski ZH, Smith WC. Chronic pain and quality of life following open inguinal hernia repair. *Br J Surg*. 2001;88:1122-6.
- Courtney CA, Duffy K, Serpell MG, O'Dwyer PJ. Outcome of patients with severe chronic pain following repair of groin hernia. *Br J Surg*. 2002;89:1310-4.
- Bay-Nielsen M, Perkins FM, Kehlet H. Pain and functional impairment 1 year after inguinal herniorrhaphy: a nationwide questionnaire study. *Ann Surg*. 2001;233:1-7.
- Cunningham J, Temple WJ, Mitchell P, Nixon JA, Preshaw RM, Hagen NA. Cooperative hernia study. Pain in the postrepair patient. *Ann Surg*. 1996;224:598-602.
- Callesen T, Bech K, Kehlet H. Prospective study of chronic pain after groin hernia repair. *Br J Surg*. 1999;86:1528-31.
- Kehlet H, Jensen TS, Woolf CJ. Persistent postsurgical pain: risk factors and prevention. *Lancet*. 2006;367:1618-25.
- Lichtenstein IL, Shulman AG, Amid PK, Montllor MM. The tension-free hernioplasty. *Am J Surg*. 1989;157:188-93.
- Callesen T, Bech K, Kehlet H. Prospective study of chronic pain after groin hernia repair. *Br J Surg*. 1999;86(12):1528-31.
- Courtney CA, Duffy K, Serpell MG, O'Dwyer PJ. Outcome of patients with severe chronic pain following repair of groin hernia. *Br J Surg*. 2002;89:1310-4.
- Grant M, Scott NW, O'Dwyer PJ. On behalf of the MRC laparoscopic groin hernia trial group. Five-year follow-up of a randomized trial to assess pain and numbness after lap aroscopic or open repair of groin hernia. *Br J Surg*. 2004;91:1570-4.
- Zhao G, Gao P, Ma B, Tian J, Yang K. Open mesh techniques for inguinal hernia repair: a meta-analysis of randomized controlled trials. *Ann Surg*. 2009;250:35-42.
- O'Dwyer PJ, Alani A, McConnachie A. Groin hernia repair: postherniorrhaphy pain. *World J Surg*. 2005;29:1062-5.
- Aasvang E, Kehlet H. Surgical management of chronic pain after inguinal hernia repair. *Br J Surg*. 2005;92:795-801.
- Merskey H, Bogduk N. Classification of chronic pain: descriptions of chronic pain syndromes and definitions of pain terms. InTask Force on Taxonomy of the IASP. 2nd ed. Seattle, WA: IASP Press; 1994: 209-214.
- Loos MJ, Houterman S, Scheltinga MR, Roumen RM. Evaluating postherniorrhaphy groin pain: visual analogue or verbal rating scale? *Hernia*. 2008;12:147-51.
- Smeds S, Löfström L, Eriksson O. Influence of nerve identification and the resection of nerves 'at risk' on postoperative pain in open inguinal hernia repair. *Hernia*. 2010;14:265-70.
- Eklund A, Montgomery A, Bergkvist L, Rudberg C. for the Swedish multicentre trial of inguinal hernia repair by laparoscopy (SMIL) study group. Chronic pain 5 years after randomized comparison of laparoscopic and Lichtenstein inguinal hernia repair. *Br J Surg*. 2010;97:600-8.
- Ferzli GS, Edwards ED, Khoury GE. Chronic pain after inguinal herniorrhaphy. *J Am Coll Surg*. 2007;205(2):333-41.
- Palumbo P, Minicucci A, Nasti AG, Simonelli I, Vietri F, Angelici AM. Treatment for persistent chronic neuralgia after inguinal hernioplasty. *Hernia*. 2003;7(1):35-8.
- Delikoukos S, Fafoulakis F, Christodoulidis G, Theodoropoulos T, Hatzitheofilou C. Re-operation due to severe late-onset persisting groin pain following anterior inguinal hernia repair with mesh. *Hernia*. 2008;12(6):593-5.
- Vuilleumier H, Hübner M, Demartines N. Neuropathy after herniorrhaphy: indication for surgical treatment and outcome. *World J Surg*. 2009;33:841-5.
- Aasvang EK, Kehlet H. The effect of mesh removal and selective neurectomy on persistent postherniotomy pain. *Ann Surg*. 2009;249(2):327-34.
- Amid PK. New understanding of the causes and surgical treatment of postherniorrhaphy inguinodynia and orchialgia. InHernia Repair Sequelae. Springer, Berlin, Heidelberg. 2010: 287-292.
- Ramaswamy A. chronic pain following inguinal hernia repair. Challenging hernias post graduate course. 12th World Congress of Endoscopic Surgery; 2010.

Cite this article as: Prasad D, Patel Y. A retrospective study of colorectal carcinoma in central India. *Int Surg J* 2020;7:2985-90.