

Original Research Article

Analysis of etiology of loss of skin in lower limb and its reconstructive options

Abhishek Devare*, Arun Bhatnagar

Department of Surgery, Gandhi Medical College and Associated Hamidia Hospital, Bhopal, Madhya Pradesh, India

Received: 29 May 2020

Revised: 18 July 2020

Accepted: 21 July 2020

*Correspondence:

Dr. Abhishek Devare,

E-mail: devareabhishek@yahoo.in

Copyright: © the author(s), publisher and licensee Medip Academy. This is an open-access article distributed under the terms of the Creative Commons Attribution Non-Commercial License, which permits unrestricted non-commercial use, distribution, and reproduction in any medium, provided the original work is properly cited.

ABSTRACT

Background: The goal of lower extremity reconstruction in cases of skin loss is the coverage of defects and open wounds of the leg, so that they resume their life and prevent the deformity or amputation. Skin loss is either managed by dressings or surgically providing skin cover in the form of skin graft or flap.

Methods: This was a prospective, observational hospital based study which involved 100 patients who were admitted in the ward with a diagnosis of skin loss in lower limb in Department of General Surgery and Department of Plastic surgery, Gandhi medical college and associated Hamidia Hospital, Bhopal, Madhya Pradesh from October 2017 to July 2019. Based upon history, clinical and local examination of the wound, necessary investigations, the plan of management, reconstructive procedure was done. The results were compared after one follow up.

Results: The patients suffering were commonly males between 18-29 years and mostly due to trauma. Initial management of wounds with skin loss in lower limb was debridement and dressings. Commonly involved anatomical area was below knee area upto both malleoli. Reconstructive measures were commonly undertaken between 3-7 days. The commonest reconstructive option was split skin grafting. Commonly flap used was perforator based flap and local transposition flap.

Conclusions: It can be concluded that the most common etiology responsible for the loss of skin in lower limb is trauma and the most used reconstructive measure in skin loss of lower limb is split skin grafting. Flap coverage acts as the best modality of reconstruction.

Keywords: Flap, Graft, Lower limb, Reconstruction, Skin loss

INTRODUCTION

The human lower limb plays a simpler role than that of upper limbs. The arm allows interacting with the environment while the leg's primary work is weight bearing and it allows the upright ambulation of body. Hence, the goal of lower extremity reconstruction in cases of skin loss is the coverage of defects and open wounds of the leg to give patients a healed wound and so that they resume their life, ambulate, and go back to work while preventing the deformity or amputation.¹ Open wounds and defects in the lower extremity result from

trauma, tumor resection, infections i.e., necrotizing fasciitis and chronic diseases such as peripheral vascular disease, varicose ulcers and diabetic foot etc. These wounds need reconstruction for many reasons; first, any exposed bone that is devoid of skin and soft tissue is at risk of drying or osteomyelitis and may end up in amputation.² Second, open wounds cause chronic pain, inability to ambulate, significant medical expenses, and deformities leading to unemployment. Third, exposed tendons if not covered early become dry and necrotic and fourth, exposed blood vessels are at risk for rupture if left uncovered.^{3,4}

Skin loss in lower limb is either managed conservatively by dressings to allow healing by secondary intention or surgically providing skin cover in the form of skin graft or flap. Larger wounds are of much importance to us as conservative management is not sufficient for the wound coverage.^{5,6} They require skin cover either split skin graft or flap coverage, and current study is designed to address these defects.

METHODS

The study was carried out in Department of General Surgery and Department of Plastic surgery, Gandhi medical college and associated Hamidia Hospital, Bhopal, Madhya Pradesh from October 2017 to July 2019.

This study was a prospective, observational hospital based study which involved a total number of 100 patients who were admitted in emergency or in routine hours in the ward with a diagnosis of skin loss in lower limb.

Inclusion criteria

Patients more than 14 years of age of either sex; patients presenting with skin loss in lower extremity; patient who can give informed consent for surgical procedure; and patients who are ready for investigation and treatment for their condition and gave consent for study.

Exclusion criteria

Patients less than 14 years of age; all patients with skin loss in perineal region and patients having bed sores; patients who died during the course of treatment; all patients who refused investigation and treatment; patients who did not gave consent for the study; and patients with wound size less than 2×2 cm size.

Data collection and evaluation

After obtaining informed consent and written consent from the patient/ their parents, patients were undertaken for study. A proforma was prepared.

General information about the patient was noted in the Proforma which included Name, Registration no., Age and Sex, Occupation, Address, presenting chief complaints with brief history to know the etiology of loss of skin in lower limb. General and systemic examination in order to assess general condition and to find out other comorbidity if any present.

Local examination of the wound and the involved limb was recorded in size (length and breadth) and the depth of defect, presence or absence of discharge or pus, condition of the underlying tissue, surrounding skin, presence of associated fracture and pulsation were also recorded.

Complete blood count, RFT, RBS, blood group, coagulation profile, urinalysis, ECG in elderly patients was done.

Radiological: X-ray of the involved limb, arterial or venous color Doppler of the involved limb, when needed were done.

Based upon the complete detailed history, clinical and loco-regional examination of the wound, necessary hematological investigations, radiological investigations, the plan of management, reconstructive procedure was decided and was informed explained to the patient attendant and then it was noted in the proforma. Planning was required in the reconstruction of defects of the lower third of the distal third of the leg, ankle, and foot in order to use the most appropriate method for best outcomes. After the discharge of the patient, one follows up of the patient was also recorded.

Statistical tool used in the study was Microsoft excel and word.

RESULTS

In age group of 14-29 years, we found out most of the cases who suffered from loss of skin in lower limb.

Table 1: Age distribution.

Age group in years	Total no. of cases
14-29	28
30-39	22
40-49	22
50-59	18
60-70	10

Table 2: Etiology of skin loss in lower limb.

Etiology of skin loss in lower limb	Total no. of cases
Trauma	40
Burn	25
Necrotizing fasciitis	10
Cellulitis	5
Diabetic foot	15
Malignancy	5

According to the study, most common cause of skin loss in lower limb was trauma.

According to the study, skin loss in lower limb was more common in males.

According to the study, below knee area up to both malleolus was more commonly involved.

According to the study, initial management of underlying cause of skin loss in lower limb was debridement and dressing, which was most commonly done.

According to the study, reconstructive measures were mostly taken within 3-7 days, which was early reconstruction. Primary measures were taken within 3 days and delayed reconstruction was done after 7 days.

Table 3: Reconstructive methods.

Reconstructive methods	Percentage of cases in which done
Split skin grafting	60
Flap	30
Flap with grafts	10

According to the study, the reconstructive method of loss of skin in lower limb was mainly split skin grafting.

Table 4: Types of flaps.

Type of flap	Total no. cases
Gastronecnius flap	8
Reverse sural flap	5
Perforator based flap	10
Cross leg flap	5
Local transposition flap	10
Soleus muscle based flap	2

According to the study, most common flap used in the reconstruction of skin in lower limb was local transposition flap and perforator based flap.

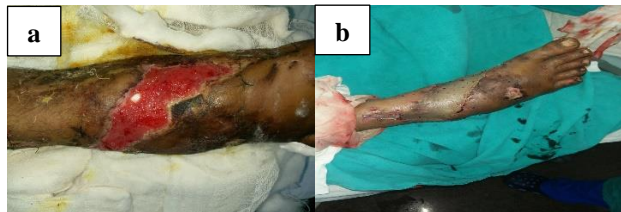


Figure 1: Split skin graft. (a) Defect over right foot due to trauma; (b) Defect covered by meshed skin graft in the right foot.

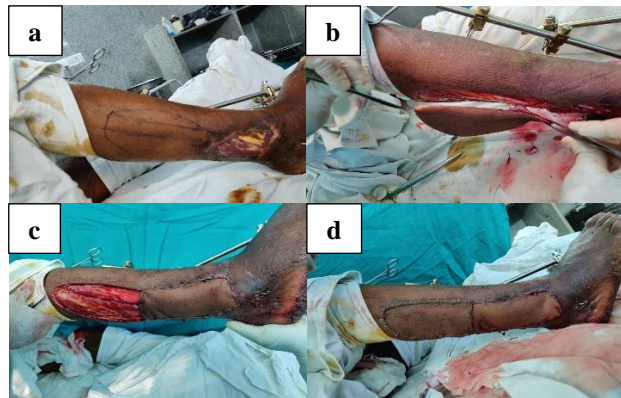


Figure 2: Flap. (a) Defect over right lateral malleoli due to trauma; (b) Perforator based flap with peroneal perforator; (c) Defect covered with propeller flap; (d) Peroneal based perforator flap with meshed skin graft.

DISCUSSION

Macedo et al of Brazil also found out that Road traffic accidents are the dominating the cause for leg and foot defects in which males were more commonly affected. Upper one third leg defects were most common and split thickness skin graft was the most common procedures used to cover the defect followed by skin flaps and muscle flaps.

In our studies we also found the similar results as the commonest cause of skin loss is due to road traffic accidents. Males were predominantly affected. Defect of skin or soft tissue loss predominated in upper one-third and skin graft was commonest option for reconstruction of defect.

In our study, we had better results of propeller based flaps in the lower leg defects due to trauma with 100% acceptance rates in total 10 patients.

Turan et al of Portugal in May 2018 took 25 cases and did reverse sural fasciocutaneous flap and the results were that in all patients, the defects were fully covered. Three patients developed partial necrosis due to venous congestion. There was no complete flap loss in any of the patients.

In our study, we did 10 reverse sural fasciocutaneous flaps, and there was 100% acceptance of the flap. There was no associated complications.

In our study, there were 5 cases of carcinomatous growth over foot and soles and were managed by local transposition flaps. In the cases of local transposition flaps there were 70% acceptance of the flaps and were associated with necrosis of the 30% area of flap, which may be due to pressure necrosis.

CONCLUSION

It can be concluded that the most common etiology responsible for the loss of skin in lower limb is trauma which is mostly due to road traffic accidents involving predominantly males. In soft tissue defects, commonest type of skin cover done is early within 3-7 days after injury.

We can also conclude that the most used reconstructive measure in skin loss of lower limb is split skin grafting. Commonest flap used for upper one-third leg defects was gastrocnemius muscle flap, for middle one-third was transposition flap and for lower one third defect, most commonly used flap was perforator-based flaps.

Flap coverage acts as the best modality of reconstruction of lower limb soft tissue loss specially where there are exposed tendons and bones. Flaps most used in the study

were the perforator based flaps and local transposition flaps. Management of lower extremity trauma with soft tissue injury is a challenging task with the aim of giving early recovery and durable good quality skin cover according to the size and site of skin defect.

The lower limb has always been known for poor wound healing and soft tissue reconstruction of the lower limb is challenging. The ideal reconstruction technique for both simple and complex defects of the lower limb should replace like to like tissue, minimize donor-site morbidity, preserve main vascular trunks, and reduce operating and hospitalization time.

The development of perforator flaps in reconstructive microsurgery has been facilitated by improved knowledge of the arterial basis of flap perfusion.

Funding: No funding sources

Conflict of interest: None declared

Ethical approval: The study was approved by the Institutional Ethics Committee

REFERENCES

1. Harris AM, Althausen PL, Kellam J, Bosse MJ, Castillo R. Lower extremity assessment project (LEAP) study group. Complications following limb-threatening lower extremity trauma. J Orthop Trauma. 2009;23:1-6.
2. Macedo JL, Rosa SC, Botelho DL, Santos CP, Queiroz MN, Gomes TG. Lower extremity reconstruction: epidemiology, management and outcomes of patients of the Federal District North Wing Regional Hospital. Revista do Colégio Brasileiro de Cirurgiões. 2017;44(1):9-16.
3. Turan K, Tahta M, Bulut T, Akgün U, Sener M. Soft tissue reconstruction of foot and ankle defects with reverse sural fasciocutaneous flaps. Revista Brasileira de Ortopedia. 2018;53(3):319-22.
4. Goodacre T. Plastic and reconstructive surgery. In: Williams NS, O'Connell PR, McCaskie AW, eds. Bailey and Love Manual of Short Practice of Surgery. 27th edition Vol. 1. CRC Press: Tyler and Francis group; 2018:633.
5. Bailey and Love Manual of Short Practice of Surgery 27th edition Vol.1 Chapter 42:633.
6. Gillies HD, Millard DR. The principles and art of plastic surgery. J Bone Joint Surg. 1957;39(2):477.

Cite this article as: Devare A, Bhatnagar A. Analysis of etiology of loss of skin in lower limb and its reconstructive options. Int Surg J 2020;7:2976-9.