

## Research Article

# Harmonic Scalpel® haemorrhoidectomy at rural tertiary care centre: a review of 52 cases

Divish Saxena\*, Murtaza Akhtar, Avinash Rode, Mrinal Tandon

Department of Department of Surgery, NKP Salve Institute of Medical Sciences, Dighdoh Hills, Nagpur, Maharashtra, India

**Received:** 11 May 2015

**Revised:** 12 May 2015

**Accepted:** 11 July 2015

### \*Correspondence:

Dr. Divish Saxena,

E-mail: [drdivishsaxena@yahoo.co.in](mailto:drdivishsaxena@yahoo.co.in)

**Copyright:** © the author(s), publisher and licensee Medip Academy. This is an open-access article distributed under the terms of the Creative Commons Attribution Non-Commercial License, which permits unrestricted non-commercial use, distribution, and reproduction in any medium, provided the original work is properly cited.

## ABSTRACT

**Background:** Haemorrhoids is a common problem in spicy food loving population of India. Multiple modalities are available for management of grade II and grade III hemorrhoids. The main postoperative complications associated with any of these procedures are pain and bleeding per rectum. Harmonic Scalpel® (Ethicon Endosurgery) Haemorrhoidectomy was evaluated in this study for post-operative complications and symptomatic relief.

**Methods:** We analyzed 52 patients of hemorrhoids of grade II, III and IV who underwent harmonic scalpel haemorrhoidectomy by a classical Milligan-Morgan technique. The outcome factors analyzed were total operative time, blood loss, post-operative pain on visual analogue scale, any other complication and days of hospital stay.

**Results:** Of all the 52 patients, the operative time was less than 10 minutes in 29 patients (55.76%) and the blood loss, as was measured by number of soaked gauze pieces only one gauze piece was soaked in 33 patients (63.46%). The Average Post-operative pain score measured on Visual Analogue Scale (VAS) at 12, 24 & 48 hours were 6.54, 4.52 and 3.12 respectively. In all patients postoperative period and follow up was uneventful except for one patient who developed anal stricture and presented with chronic constipation. A weekly anal dilatation was performed in this patient with anal dilators for 2 months and patient was relieved thereafter.

**Conclusions:** Harmonic Scalpel® hemorrhoidectomy is a safe and fast modality of treatment for 2<sup>nd</sup>, 3<sup>rd</sup> & 4<sup>th</sup> degree of hemorrhoids whether single or multiple, requiring very less operating time, with no major post-operative complications and early return to day to day activities.

**Keywords:** Harmonic scalpel, Hemorrhoids, Haemorrhoidectomy

## INTRODUCTION

Hemorrhoid is a common problem in spicy food loving population of India. Majority of patients present with bleeding per rectum or some mass coming out of the rectum in daily out-patient department. Various modalities in the form of classical open Milligan-Morgan operation, harmonic scalpel, cryoablation, LASER, stapler haemorrhoidectomy, etc. are available for management of Grade II, III and IV hemorrhoids.<sup>1,5,6</sup> The

major complications after any of the above mentioned modalities is post-operative bleeding and pain.

Harmonic Scalpel® (Ethicon endosurgery) is an energy source which works like a bipolar mode of cautery achieving cutting as well as coagulation at the same time. However the lateral spread of current is just 0.5 to 1 mm which is responsible for less adjacent tissue trauma thereby lowering the incidence of post-operative bleeding or pain and subsequently early return to day to day activities.<sup>2-5</sup>

## METHODS

It was a prospective cohort study carried out at rural based tertiary health care centre over 2 years. All the patients presenting with bleeding per rectum were analyzed.

**Inclusion criteria:** All patients clinically and anoscopically diagnosed as grade II, III and IV hemorrhoids presenting with bleeding per rectum were included in the study.

**Exclusion criteria:** All the patients with previous ano-rectal surgeries or with co morbid conditions and unfit for anesthesia were excluded from the study.

**Procedure:** For this study, a detailed performa was prepared. In all the patients their presenting complaints, clinical and per rectal findings, investigations, intra operative findings, treatment, pain scoring using Visual Analogue Scale (VAS) and a note on post-operative complication were made. All the cases were called for follow up at monthly intervals for three months and their clinical condition were recorded.

The outcome factors analyzed were:

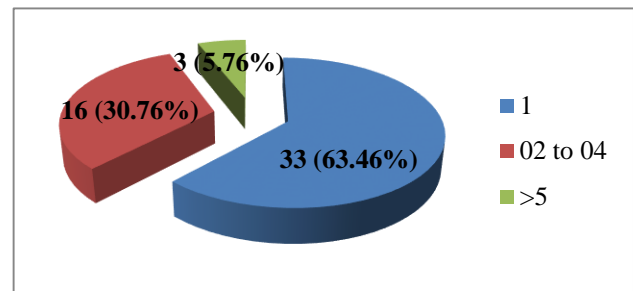
- 1) Total operative time
- 2) Total intra operative blood loss
- 3) Post-operative pain recorded at 12 hours, 24 hours & 48 hours on VAS
- 4) Any post-operative complication in the form of bleeding or urinary retention or constipation
- 5) Number of days of hospital stay

## RESULTS

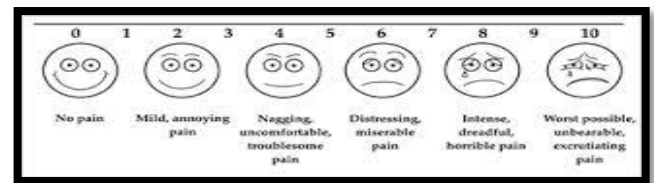
Total 52 patients were enrolled during the period of two years. 34 (65.38%) were males. Bleeding per rectum was the chief presenting complaint of all the patients, while 31 patients presented with something coming out of rectum, 23 patients presented with pain during defecation and 16 patients presented with associated chronic constipation. Total operative time was less than 10 minutes in 29 patients (55.76%) and 10 to 20 minutes in 23 patients (44.23%). Intraoperative blood loss was measured by number of gauze pieces soaked. In 33 patients (63.46%) only one gauze piece was soaked, in 16 patients (30.76%) less than 5 gauze pieces were soaked and in only 3 patients (5.76%) more than 5 gauze pieces were soaked (Figure 1).

Post-operative pain was measured on Visual Analogue Scale (VAS) (Figure 2) in all the patients at 12 hours, 24 hours and 48 hours postoperatively. A VAS score of more than 6 was observed in 33 patients (63.46%) 12

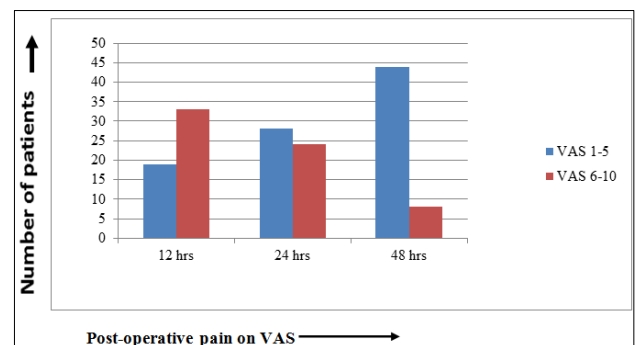
hours postoperatively, in 24 patients (46.15%) 24 hours postoperatively and only in 8 Patients (15.38%) 48 hours after surgery. This shows that with time number of patients having a VAS score between 6 -10 decreases (Figure 3).



**Figure 1: Showing number of gauze pieces soaked during surgery.**



**Figure 2: Visual Analogue Scale (VAS).**



**Figure 3: Chart showing VAS score in patients with passage of time.**

The average post-operative pain score on VAS at 12, 24 & 48 hours were 6.54, 4.52 and 3.12 respectively. None of the patients had post-operative bleeding or urinary retention. Only one patient developed anal stricture on follow up visit. A weekly anal dilatation was done in that patient for two months and patient got symptomatically relief. The mean hospital stay was 2 days.

## DISCUSSION

Haemorrhoidectomy is the treatment of choice for grade II, III and IV hemorrhoids. The major complication for any modality of treatment is post-operative pain. Harmonic scalpel® divides tissue using high-frequency ultrasonic energy. Because the instrument operates at temperature

less than 100°, it is associated with minimal tissue damage, the lateral thermal spread being only 0.5 to 1.0 mm as compared to conventional electrocautery which uses heat energy causing more tissue charring.<sup>2-5</sup> The use of harmonic scalpel therefore causes less time for tissues to heal and thereby early return to daily activities.<sup>2-4</sup>

In our study, 52 patients underwent Harmonic Scalpel Hemorrhoidectomy. The operative time for 23 patients (44.23%) having single haemorrhoid was less than 10 minutes, whereas in 29 patients (55.76%) as multiple haemorrhoids were present operating time was more than 10 minutes. None of the patient required an operative time of more than 20 minutes which is comparable with the study done by Sayfan Joel et al. and Kwok SY et al.<sup>2,6</sup> The blood loss as was estimated by number of gauze pieces soaked also showed that in 33 patients (63.46%) hardly one gauze piece was soaked. A study by Tsunoda et al. showed that the average blood loss during harmonic scalpel haemorrhoidectomy was less than 5 ml which also makes this procedure bloodless.<sup>9</sup> In only 3 patients (5.76%) the number of gauze pieces soaked were more than 5, the reason being presence of multiple haemorrhoids with external component. Post-operative pain was analyzed by using Visual Analogue Scale (VAS) at 12, 24 and 48 hours postoperatively. Out of 52 patients, 33 patients (63.46%) had a VAS score of more than 6, twelve hours postoperatively. However, this figure got reduced to 8 patients (15.38%) 48 hours after surgery. These 8 patients were discharged on 7<sup>th</sup> postoperative day when their pain was completely subsided as compared to rest of the patients who were discharged between 2<sup>nd</sup> to 4<sup>th</sup> post-operative days. The average post-operative pain score on VAS at 12, 24 & 48 hours were 6.54, 4.52 and 3.12 respectively. None of the patient developed urinary retention or post-operative bleeding per rectum in immediate post-operative period or on subsequent follow up period of 3 months. Only one patient (1.92%) developed constipation secondary to anal stricture. This patient was having multiple prolapsed haemorrhoids on presentation. He was advised weekly anal dilatation for about 2 months using anal dilators. Anal dilatation was done on OPD basis for about 2 months and finally patient was symptomatically relieved. Nevertheless, Harmonic Scalpel® Hemorrhoidectomy is a safe and effective surgical modality.<sup>4,7-9</sup>

## CONCLUSION

From our study, we conclude that Harmonic Scalpel® hemorrhoidectomy is a safe and fast modality treatment

for 2<sup>nd</sup>, 3<sup>rd</sup> & 4<sup>th</sup> degree of hemorrhoids whether single or multiple, requiring very less operating time, with no major post-operative complications and early return to day to day activities

*Funding: No funding sources*

*Conflict of interest: None declared*

*Ethical approval: The study was approved by the institutional ethics committee*

## REFERENCES

1. Milligan ETC, Morgan CN, Jones LE, Officer R. Surgical anatomy of the anal canal and the operative treatment of hemorrhoids. Lancet. 1937;2:1119-24.
2. Sayfan J, Becker A, Koltan L. Sutureless closed hemorrhoidectomy: a new technique. Ann Surg. 2001;234(1):21-4.
3. Armstrong DN, Frankum C, Schertzer ME, Ambroze WL, Orangio GR. Harmonic scalpel hemorrhoidectomy, five hundred consecutive cases ; Dis Colon Rectum. 2002 Mar;45(3):354-9.
4. Ramadan E, Vishne T, Dreznik Z. Harmonic scalpel Hemorrhoidectomy: preliminary results of a new alternative method. Tech Coloproctol. 2002 Sep;6(2):89-92.
5. Di Vita G, Patti R, Petrone R, Arcara M, Sieli G. Milligan-Morgan haemorrhoidectomy with ultrasonic scalpel. G Chir. 2003 Nov-Dec;24(11-12):422-7.
6. Kwok SY, Chung CC, Tsui KK, Li MKW. A double-blind randomized trial comparing ligasure and harmonic scalpel hemorrhoidectomy. Dis Colon Rectum. 2005 Feb;48(2):344-8.
7. Ivanov D, Babovic S, Selesi D, Ivanov M, Cvijanovic R. Harmonic scalpel hemorrhoidectomy: a painless procedure. Med Pregl. 2007 Sep-Oct;60(9-10):421-6.
8. Szyca R, Jasiński A, Tomaszewski S, Jaworowska-Detyna I, Leksowski K. Pol Merkur Lekarski Early results of surgical treatment of haemorrhoids at use of harmonic scalpel. 2009 May;26(155):462-4.
9. Tsunoda A, Sada H, Sugimoto T, Kano N, Kawana M, Sasaki T, et al. Randomized controlled trial of bipolar diathermy vs. ultrasonic scalpel for closed hemorrhoidectomy. World J Gastrointest Surg. 2011 Oct;3(10):147-52.

**Cite this article as:** Saxena D, Akhtar M, Rode A, Tandon M. Harmonic Scalpel® haemorrhoidectomy at rural tertiary care centre: a review of 52 cases. Int Surg J 2015;2:366-8.