

## Original Research Article

# Management of prostatic abscess, our experience over 5 year

Sanjay Lakshminarayan Paul\*, Manharsinh Rajput, P. M. Deka, Priyanku Pratik Sarma

Department of Urology, Dispur Hospital, Guwahati, Assam, India

**Received:** 21 May 2020

**Revised:** 08 July 2020

**Accepted:** 10 August 2020

### \*Correspondence:

Dr. Sanjay Lakshminarayan Paul,  
E-mail: [sanjaypaul619@gmail.com](mailto:sanjaypaul619@gmail.com)

**Copyright:** © the author(s), publisher and licensee Medip Academy. This is an open-access article distributed under the terms of the Creative Commons Attribution Non-Commercial License, which permits unrestricted non-commercial use, distribution, and reproduction in any medium, provided the original work is properly cited.

### ABSTRACT

**Background:** The objective of our study was to perform retrospective analysis of management of prostatic abscess in a tertiary care hospital in northeast India.

**Methods:** This was a single tertiary care hospital based retrospective analysis of management of 24 patients diagnosed with prostatic abscess, between January 2015 and January 2020. Diagnosis of prostatic abscess was confirmed by trans-rectal ultrasonography (TRUS) and/or computed tomography (CT) scan/magnetic resonance imaging (MRI) prostate. Various treatment modalities used in our study were conservative, transurethral resection of prostatic abscess (TURP), TRUS-guided trans-rectal drainage/aspiration, trans-urethral drainage (TUD) + trans-urethral incision (TUI).

**Results:** On analysing 24 patients diagnosed with prostatic abscess, mean age was 46.12 years (range, 17 to 73 years), the mean prostate-specific antigen (PSA) was 17.3 ng/ml (range, 2 to 40.0 ng/ml), mean prostatic abscess volume was 33 cubic mm (range, 10 to 75 gm). All patients were hospitalised, on admission all patients were started on intravenous antibiotics (3rd-generation cephalosporin along with an amino-glycoside) or antibiotics as per urine culture report. Diabetes mellitus was most common associated co-morbidity present in almost 50% of patients. Patients presented with dysuria (75%), urinary retention (29%) fever (25%) and perineal pain. Cases were managed by surgical approach after failure of conservative management.

**Conclusions:** Early surgical intervention for prostatic abscess reduces morbidity and mortality associated with it. TRUS guided drainage can be performed under local anaesthesia, are better suited for small localised abscess but associated with increase hospital stay. Trans-urethral drainage are better suited for elderly patient with large prostate volume.

**Keywords:** Prostatic abscess, Trans-urethral drainage, Trans-rectal ultrasonography-guided trans-rectal drainage/aspiration, Prostate specific antigen

### INTRODUCTION

Prostatic abscess still remains a common problem in developing countries and has a high morbidity and mortality rate. Most of the cases are associated with one or more co-morbidities such as diabetes mellitus, hemoglobinopathies, poor socio-economic conditions and spinal injury, which accounts for a sizeable population in northeast India. Conservative treatment alone is not sufficient and it requires some form of surgical modalities of treatment.<sup>1</sup> The management options include trans-

rectal ultrasound (TRUS) guided aspiration/tube drainage, transurethral incision over abscess (TUI), transurethral de-roofing of the abscess cavity (TUD), or formal transurethral resection of prostate abscess (TURP).<sup>1-7</sup> In this study, we have retrospectively analyzed data on conservative treatments, TURP and TRUS guided drainage in 24 cases over a 5-year period.

The objective of our study was to perform retrospective analysis of management of prostatic abscess in a tertiary care hospital in northeast India.

## METHODS

This study was a single center tertiary care hospital based retrospective analysis of management of 24 patients diagnosed with prostatic abscess, between January 2015 and January 2020. The data of patients were collected retrospectively from the medical records. Patients presented with dysuria, urinary retention fever, perineal pain, urethral discharge and severe tenderness with or without fluctuation was elicited on digital rectal examination. All patients were evaluated with routine blood and urine test, urine culture sensitivity, viral screening for retroviral disease, renal function test. Diagnosis was confirmed in all the patients by TRUS/CT/multi-parametric MRI (MP-MRI).

### *Inclusion criteria*

Patient with dysuria, urinary retention, perineal pain, fever and abnormal digital rectal findings, later confirmed with imaging study of having prostatic abscess, minimum of 17 years of age, fit to undergo all protocol procedure including TRUS guided drainage, fit for general or spinal anaesthesia, if required were included.

### *Exclusion criteria*

Patients with previous history of prostate biopsy, prostate surgery, or treatment for prostate cancer and abnormal coagulation profile were excluded.

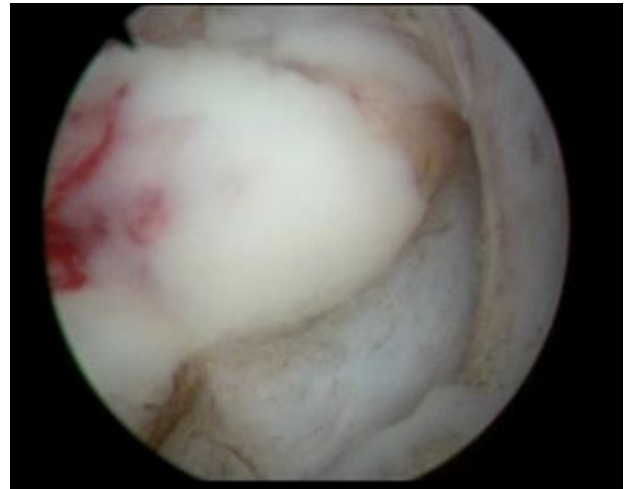
All patients received intravenous antibiotics (3<sup>rd</sup> generation cephalosporins and gentamicin) and tablet metronidazole empirically on admission or as per urine culture sensitivity report.

Surgical drainage was performed after failure of antibiotic therapy (Figure 1 and 3). Treatment modalities used in our study were conservative, trans-urethral drainage by resection alone or combining with trans-urethral incision with Collins knife, trans-rectal drainage/aspiration.

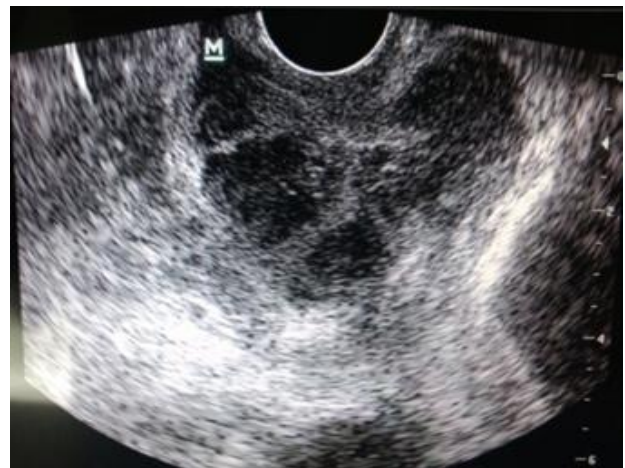Trans-urethral drainage was performed using Iglesias continuous rotating bipolar/monopolar resectoscope. Trans-urethral resection and deroofting was done, additionally, the release of pus to the prostatic urethra was facilitated by intra-operative prostatic massage. Another method used by us to induce pus release to the prostatic urethra was by creating several incisions with a Collins knife in the expected site of the abscess, thus avoiding excessive resection of prostatic tissues.

Trans-rectal probe and a biopsy guide attachment was used for needle aspiration, probe was covered with condom and lubricant anaesthetic gel was used (Figure 4). The needle was inserted under TRUS guidance via the probe through the rectal wall into the abscess cavity. After the aspiration of pus, antibiotic solution was instilled and re-aspirated. Patient was by TRUS at one week for any re-accumulation. Postoperatively patients were given antibiotics for four

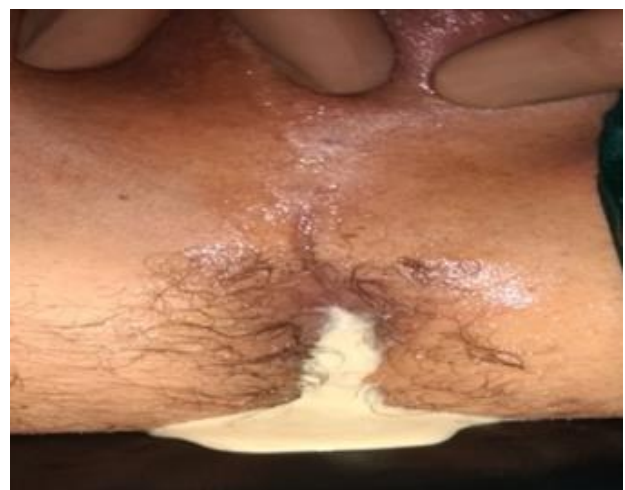weeks as per culture results. Criteria for successful treatment were clinical improvement and no pus collection on follow-up.



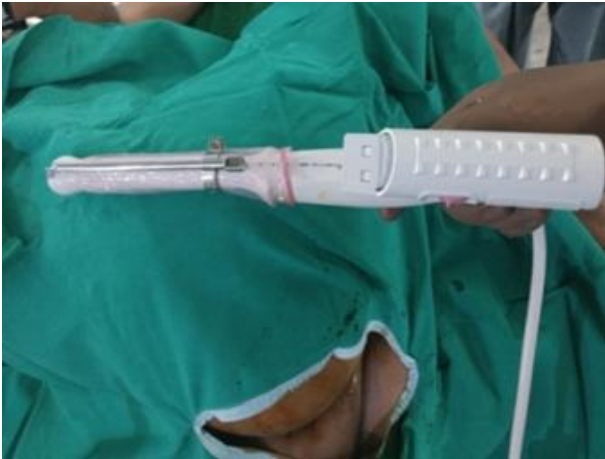
**Figure 1: Cystoscopic image after drainage of prostate abscess.**



**Figure 2: TRUS showing hypoechoic lesion.**



**Figure 3: Purulent drainage after TRUS drainage.**



**Figure 4: Trans-rectal probe with attachment.**

#### Statistical analysis

Statistical analysis was performed by using statistical product and service solutions (SPSS) version 18.0 software. Fisher's exact test was used to compare categorical variables. The data are expressed as the mean  $\pm$  standard deviation or median and range. P-values less than 0.05 were considered statistically significant in our study.

## RESULTS

On analysing 24 patients diagnosed with prostatic abscess, mean age was 46.12 years (range, 17 to 73 years), the mean prostate-specific antigen (PSA) was 17.3 ng/ml (range, 2 to 40.0 ng/ml), mean prostatic abscess volume was 33 cubic mm (range, 10 to 75 gm). All patients were hospitalised, on admission all patients were started on intravenous antibiotics (3rd generation cephalosporin along with an amino-glycoside) or antibiotics as per urine culture report. Diabetes mellitus was most common associated co-morbidity present in almost 50% of patients. Patients presented with dysuria (75%), urinary retention (29%) fever (25%) and perineal pain. Cases were managed by surgical approach after failure of conservative management.

Prostatic abscesses were managed by transurethral resection in 11 cases, and TRUS-guided trans-rectal drainage/aspiration in 6 cases, trans-urethral drainage (TUD) and trans-urethral incision (TUI) in 2 cases, and conservative treatment in 5 cases. The average hospitalization stay was 9.7 days. Patients treated by transurethral resection and TRUS-guided trans-rectal drainage were hospitalized for 9.8 days and 12.83 days respectively. All patients were followed up 1 month after the procedure, complications were managed accordingly.

**Table 1: Data of all the 24 patients.**

S. no.	Age (years)	DM	Associated co-morbidities	Presenting symptom	PSA (ng/ml)	Prostate volume (mm <sup>3</sup> )	Treatment modalities performed	Hospital stay	Recurrence
01	65	+		AUR+ dysuria	24	74	TRD	12	-
02	70	+	Hypertension, A	AUR + fever	36	60	TRD	14	+
03	50	-	Hypertension	Dysuria	16	44	TUD	10	-
04	29	-		Dysuria	10	20	Conservative	10	-
05	36	+		Dysuria+ fever	18	25	TUD	7	-
06	38	+		AUR	40	30	Conservative	6	-
07	42	-		Dysuria	38	34	TUD	8	-
08	62	+	Spinal cord injury	UR	12	50	TUI + TUD	12	-
09	18	-		Fever, perineal pain+ dysuria	04	15	Conservative	7	-
10	17	-		Perineal pain+ dysuria	02	10	Conservative	7	-
11	49	-		Dysuria	08	15	TUD	10	-
12	65	+	Hypertension	AUR + dysuria	14	25	TRD	11	-
13	61	+		Dysuria	28	38	TRD	15	-
14	57	-		Dysuria	20	20	TUI + TUD	15	-
15	45	+	A	Dysuria	30	45	TUD	12	-
16	42	-		Fever, perineal pain	06	40	TUD	09	-
17	58	+	Hypertension	Dysuria	02	50	TRD	13	-

Continued.

S. no.	Age (years)	DM	Associated co-morbidities	Presenting symptom	PSA (ng/ml)	Prostate volume (mm <sup>3</sup> )	Treatment modalities performed	Hospital stay	Recurrence
18	30	-		Fever, perineal pain+ dysuria	04	20	Conservative	08	-
19	28	-		Dysuria	02	10	TUD	07	-
20	50	-		AUR	20	15	TUD	06	-
21	58	+		Dysuria	24	25	TUD	05	-
22	43	+		AUR + dysuria	16	38	TUD	10	-
23	21	-		Fever, perineal pain	06	14	TUD	07	-
24	73	+	Hypertension	Dysuria	36	75	TRD	12	-

TUI=transurethral incision, TUD=transurethral diathermy, DM=diabetes mellitus, PSA= prostate-specific antigen, AUR= acute urinary retention, UR=urinary retention, TRD=transrectal drainage, A=anaemia

## DISCUSSION

Early surgical intervention for prostatic abscess reduces morbidity and mortality associated with it. Minimally invasive treatment with TRUS guidance can be performed under local anaesthesia and should be a primary modality of treatment in non-elderly patients with localized abscess cavities.

The most common finding in TRUS of the prostate is the presence of one or more hypo-echoic areas, which assists in the treatment and follow-up of patients with prostatic abscess (Figure 2). Primary management of prostatic abscess starts with broad-spectrum antibiotic

administration and drainage of abscess when conservative management fails. Drainage of abscess cavity can be performed by trans-rectal or trans-perineal ultrasound-guided, digital-guided puncture/drainage by the perineal route, transurethral incision of the prostate, TURP or open perineal drainage. All methods have been reported to be safe and effective. Recent findings suggest that less invasive treatment by ultrasound-guided percutaneous or trans-rectal drainage is preferred to TUR drainage because it can be performed under local anesthesia or sedation and repeated if necessary. Less invasive methods also have a lower risk of complications, in particular, possible retrograde ejaculation after TUR drainage in relatively young patients.<sup>8-10</sup>

**Table 2: Comparison between various studies.**

Study	No. of cases (period)	Age (years)	PSA (ng/ml)	Prostate size/ volume	DM	Clinical presentation	Treatment modalities			Hospital stay (days)	Recurrence
							TUR	TRD	TUR+ TUI		
Bansal et al <sup>4</sup>	18 (2005-07)	47.12	-	-	6 (33%)	Dysuria, fever and pain perineum	-	04	-	9.4	-
Shazly et al <sup>11</sup>	11 (2008-10)	51	-	-	99 (81%)	Fever	07	02	-	-	-
Goyal et al <sup>12</sup>	17 (2003-11)	61.53	-	-	09 (52%)	dysuria and lower urinary tract symptom	17	-	-	-	-
Jang et al <sup>13</sup>	52 (2000-10)	61.3	18.54	56.3	22 (42.3%)	fever (47, 90.4%), perineal discomfort (43, 82.7%)	23 (44.2%)	18 (34.6%)	-	17.5	04
<b>Our study</b>	24 (2015-18)	46.125	17.30	33	12 (50%)	Dysuria (75%), retention (29%)	11	06	02	9.7	01

## CONCLUSION

Early diagnosis and management of prostatic abscess significantly decrease morbidity and mortality, TRUS plays an important role in diagnosis, management and

follow up. We conclude with the present study that patients treated by trans-urethral approach had a shorter hospital stay as compared to trans-rectal with no cases of recurrence or mortality. Trans-rectal drainage approach was associated with increase hospital stay and recurrence

was found in one case. Minimally invasive treatments should be preferred as the primary treatment in relatively young patients with localized abscess cavities. Resection and drainage should be preferred in cases with diffuse, large abscess cavities or after other modalities fail.

*Funding: No funding sources*

*Conflict of interest: None declared*

*Ethical approval: The study was approved by the Institutional Ethics Committee*

## REFERENCES

1. Aravantinos E, Kalogeras N, Zygoulakis N, Kakkas G, Anagnostou T, Melekos M. Ultrasound-guided trans-rectal placement of a drainage tube as therapeutic management of patients with prostatic abscess. *J Endourol.* 2008;22(8):1751-4.
2. Cytron S, Weinberger M, Pitlik SD, Servadio C. Value of trans-rectal ultrasonography for diagnosis and treatment of prostatic abscess. *Urol.* 1988;32(5):454-8.
3. Granados EA, Riley G, Salvador J, Vicente J, Krieger JN, Uehling DT. Prostatic abscess: diagnosis and treatment. *J Urol.* 1992;148(1):80-2.
4. Bansal P, Gupta A, Mongha R, Bera M, Ranjit K, Kundu AK. Minimally-invasive management of prostatic abscess: the role of trans-rectal ultrasound. *Urol Annals.* 2009;1(2):56-60.
5. Basiri A, Javaherforooshzadeh A. Percutaneous drainage for treatment of prostate abscess. *Urol J.* 2010;7(4):278-80.
6. Bhagat SK, Kekre NS, Gopalakrishnan G, Balaji V, Mathews MS. Changing profile of prostatic abscess. *Int Braz J Urol.* 2008;34(2):164-70.
7. Ludwig M, Schroeder-Printzen I, Schiefer HG, Weidner W. Diagnosis and therapeutic management of 18 patients with prostatic abscess. *Urol.* 1999;53(2):340-5.
8. Vaccaro JA, Belville WD, Kiesling VJ, Davis R. Prostatic abscess: computerized tomography scanning as an aid to diagnosis and treatment. *J Urol.* 1986;136(6):1318-9.
9. Kinahan TJ, Goldenberg SL, Ajzen SA, Cooperberg PL, English RA. Transurethral resection of prostatic abscess under sonographic guidance. *Urol.* 1991;37(5):475-7.
10. Bachor R, Gottfried HW, Hautmann R. Minimal invasive therapy of prostatic abscess by trans-rectal ultrasound-guided perineal drainage. *Eur Urol.* 1995;28(4):320-4.
11. El-Shazly M, El-Enzy N, El-Enzy K, Yordanov E, Hathout B, Allam A. Transurethral Drainage of Prostatic Abscess: Points of Technique. *Nephro-Urol Mon.* 2012;4(2):458-61.
12. Goyal NK, Goel A, Sankhwar S, Dalela D. Transurethral Resection of Prostate Abscess: Is It Different from Conventional Transurethral Resection for Benign Prostatic Hyperplasia? *Hindawi Publishing Corporation ISRN Urology Volume.* 2013;109505:5.
13. Jang K, Lee DH, Lee SH, Chung BH. Department of Urology, Gangnam Severance Hospital, Seoul, Korea, Treatment of Prostatic Abscess: Case Collection and Comparison of Treatment Methods. *Korean J Urol.* 2012;53(12):860-4.

**Cite this article as:** Paul SL, Rajput M, Deka PM, Sarma PP. Management of prostatic abscess, our experience over 5 year. *Int Surg J* 2020;7:2955-9.