

## Case Report

# Kodamaea Ohmeri: a rare fungus causing a severe case of necrotizing fasciitis

Mercy Jimenez<sup>1</sup>, Emily S. Seltzer<sup>2\*</sup>, Javeria Shakil<sup>3</sup>, Martine Louis<sup>1</sup>

<sup>1</sup>Department of Surgery, Flushing Hospital Medical Center, Parsons Blvd, Flushing, NY, USA

<sup>2</sup>New York Institute of Technology College of Osteopathic Medicine, Northern Blvd, Glen Head, NY, USA

<sup>3</sup>Department of Infectious Disease, Flushing Hospital Medical Center, Parsons Blvd, Flushing, NY, USA

**Received:** 18 May 2020

**Accepted:** 07 July 2020

### \*Correspondence:

Emily S. Seltzer,

E-mail: [Eseltz01@nyit.edu](mailto:Eseltz01@nyit.edu)

**Copyright:** © the author(s), publisher and licensee Medip Academy. This is an open-access article distributed under the terms of the Creative Commons Attribution Non-Commercial License, which permits unrestricted non-commercial use, distribution, and reproduction in any medium, provided the original work is properly cited.

### ABSTRACT

Necrotizing soft tissue infection, NSTI, involves the soft tissue characterized by rapid spread of infection and consequent cell necrosis. NSTI, in particular necrotizing fasciitis (NF), is a significant disease burden in the US with an annual mortality of 4.8 per 1,000,000 person years. Here we describe a rare fungal pathogen, *Kodamaea Ohmeri*, as a cause of NF in a diabetic but otherwise healthy male patient. In the past *K. Ohmeri* has been described in children, immunocompromised individuals, and in cases with IV catheters and prolonged use of IV antibiotics. A febrile and hypotensive male (LRINEC score of 6) presented after sustaining abrasions of his right lower extremity. He was initially started on broad-spectrum antibiotics and underwent surgical exploration. During the following weeks, the patient developed sepsis and endured a total of four debridement. Wound cultures resulted *K. Ohmeri* with sensitivity to miconazole and voriconazole. Anti-fungal, silver dressings and wound vacuum, were utilized to assist in treatment and tissue granulation. To our knowledge, this is the first case describing *Kodamea ohmeri* as a causative agent of NF. *K. Ohmeri* should be on the radar of the health care providers taking care of patients with NF, especially in the context of intermittent bouts of sepsis and prolonged hospital course. Our case illustrates the fact that prompt identification, addition of fungal cultures and appropriate surgical treatment are crucial to improve patient outcomes.

**Keywords:** Necrotizing fasciitis, *Kodamaea Ohmeri*, Case report

### INTRODUCTION

Necrotizing soft tissue infection, NSTI, is a spectrum of diseases, from necrotizing cellulitis to necrotizing fasciitis (NF), involving the soft tissue and is characterized by rapid spread of infection and consequent cell necrosis. NSTI, in particular NF has an annual mortality of 4.8 per 1,000,000 person-years.<sup>1</sup> NSTI are categorized into four types depending on the causative organisms; type I caused by obligate or facultative anaerobes and polymicrobial in nature, type II monomicrobial secondary to beta-hemolytic streptococcus, type III vibrio vulnificus and type IV fungal in origin.<sup>2</sup> Here we present a case of a rare

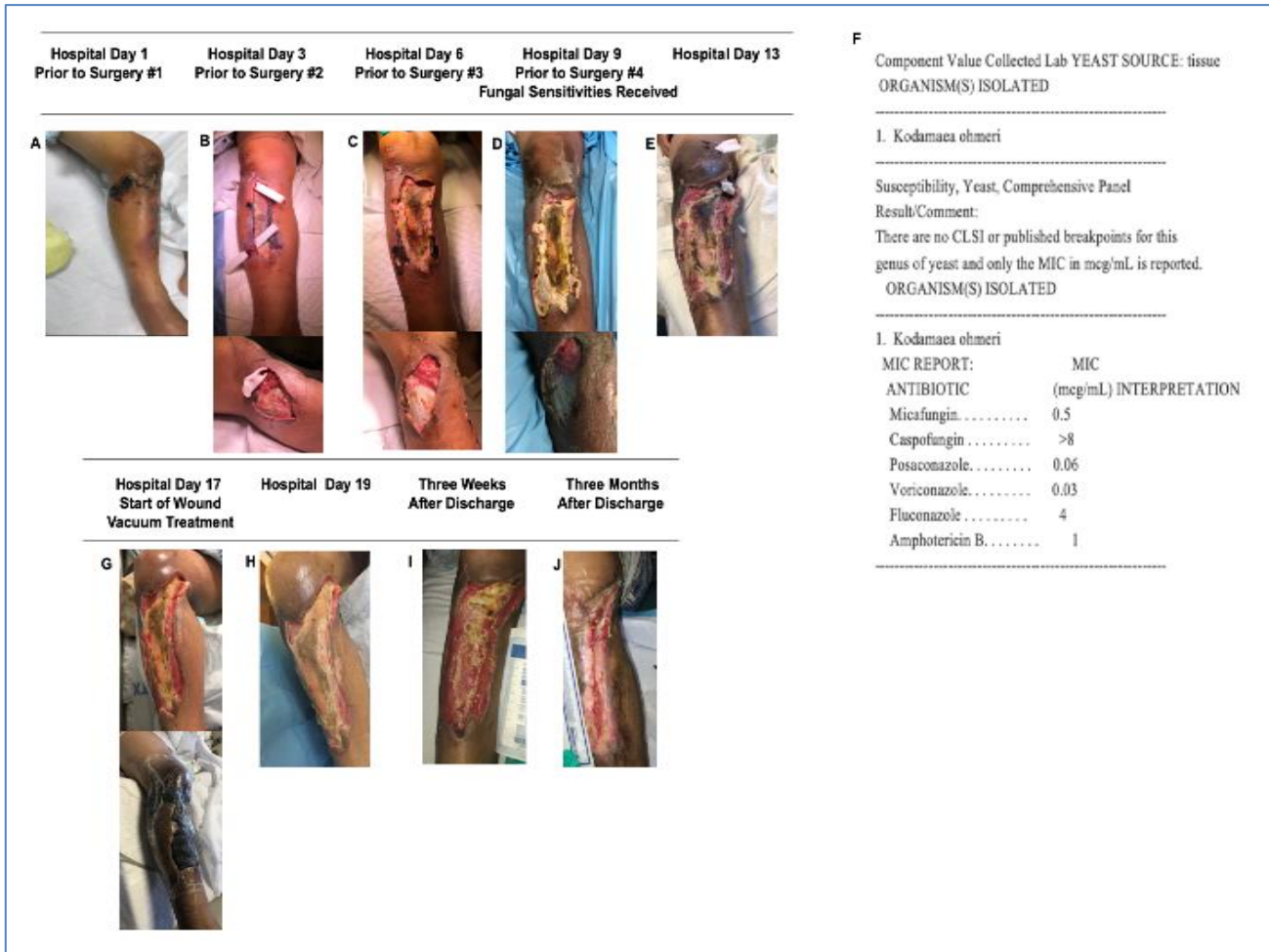
emerging fungal pathogen, *Kodamaea Ohmeri*, as a cause of NF and severe sepsis in a diabetic male patient at a community hospital.

### *Patient presentation and clinical course*

A 43-years-old Hispanic male with a history of poorly controlled diabetes and normal BMI (24.2) presented to the emergency department two weeks after sustaining abrasions and bruising to his right lower extremity from a motorbike accident. He complained of increasing swelling and pain in his right leg and knee, as well as fevers and chills for the past five days. He was afebrile (36.8 °C), hypotensive (80/56 mmHg), with a normal

heart rate (94 bpm). The physical exam was significant for a large ulcerated blister, along with surrounding warmth, erythema and foul-smelling purulent discharge and induration on the right anterior tibia and lateral knee. The lower extremity was neurovascularly intact with palpable pulses distally, full range of motion and intact sensation; all compartments were soft.

Bloodwork was significant for a leukocytosis (WBC 20.1K), hematocrit of 36.4%, platelet count of 339/mm<sup>3</sup>, sodium 134 meq/l, serum glucose of 287 mg/dl, D dimer 815 µg/l, lactate 1.2 mg/dl, CRP >9.0 mg/l (LRINEC 6). Tib/Fib X-ray was negative for any occult fractures.



**Figure 1: Progression of necrotizing fasciitis; (A) lateral-length 9 cm, width 5.5 cm, depth 0.6 cm, medial-length 18 cm, width 3 cm, depth 1 cm, additional lateral incision 1 cm by 0.1 cm, intra-operative findings included large abscesses over lateral and anterior right leg with the seropurulent drainage, in the initial debridement the fascia appeared viable, and the patient diagnosed as necrotizing cellulitis; (B-E) necrotizing tissue extended to the fascia and required three additional debridements, pockets of foul fluid overlying the wound and fascia was removed and penrose drains were placed; (F) culture and sensitivities were received on hospital day 9; (G and H) wound vacuum and silver negative pressure dressings were used to facilitate the wound healing process and granulation of tissue; (I and J) after hospital discharge the patients wound continued to heal with bi-weekly wound dressing changes.**

The patient was given IV fluids, broad-spectrum antibiotics (Zosyn, clindamycin and vancomycin) and was admitted under surgical service for concern of necrotizing soft tissue infection. On the day of admission, the patient was taken to the operating room for emergent incision, drainage, debridement and irrigation of his right leg. Intraoperative findings included large abscesses over lateral and anterior right leg with seropurulent drainage, with the fascia appeared viable (Figure 1A). The patient

did well for the first 48 hours, there was no growth from the wound culture, and he was transferred to the floor. On hospital day 3, an episode of temperature spike, hypotension and worsening clinical exam prompted a repeat debridement with findings of worsening fascial involvement and new pocket of pus, new wound cultures were sent. A fungal pathogen was suspected after discussion with the Infectious disease specialist, and the addition of fluconazole was suggested. The patient improved again, for 48 hours, on day 6 again he

experienced hypotension and fevers, was debrided again and improved Figure 1 (B-D). On hospital day 8, the patient's state acutely worsened with hypotension, this time not responsive to fluids, requiring vasopressors. He was placed in surgical intensive care unit for two days, and at this time he underwent one last debridement and washout, exposing a significant portion of the anterior tibia (Figure 1E). Wound cultures, which had grown yeast, resulted on day 9 as *K. ohmeri*, with sensitivity to micafungin and voriconazole, which were immediately started (figure 1F). Thereafter, wound healing continued with daily dressing changes. Silver dressings and wound vacuum therapy were utilized to assist in granulation. Figure 1 (G and H). The patient was seen on weekly to bi-weekly basis for dressing changes once he left the hospital, until final healing Figure 1 (I and J).

## DISCUSSION

Historically, *Kodamaea Ohmeri* was used in the fermentation of rinds, fruit and pickles and the first pathologic case of *K. Ohmeri* was reported in an immunocompromised patient in Italy by Bergman et al.<sup>3</sup> The majority of case reports presenting *K. Ohmeri* to date involved neonates, or immunocompromised individuals including those with HIV, endocarditis, burn patients, hemochromatosis, organ transplant recipients or patients with artificial heart valves.<sup>4-13</sup> Other conditions associated with overwhelming infection of *K. Ohmeri* include prolonged intravenous antibiotic use, diabetes mellitus, COPD, coronary artery disease, hemodialysis, recent surgery, prolonged intravenous catheter use.<sup>14-16</sup> Given the low prevalence of *K. Ohmeri* infection and relatively small number of reported cases, it is difficult to discern specific risk factors for this pathogen independent of those for disseminated yeast infections in general, which are largely candida species. In general, bloodstream infections of *K. Ohmeri* are typically less life threatening than disseminated infections with other rare yeasts.<sup>15</sup> Internationally, some reports have identified other rare fungi in the setting of necrotizing fasciitis including *Apophysomyces* species and *Saksenaia* (a type of mucormycetes) in northern India.<sup>17,18</sup> In the US, fungi are rarely encountered in soft tissue infections, except for candida, which typically causes local infection of the dermis and commonly treated with creams and powders. Diagnosis of *K. Ohmeri* via cultures using CHROM agar has been shown to be an effective in multiple studies.<sup>7,19,20</sup> High tech mass spectrometry has been widely used for confirmation and speciation, as well as PCR analysis of the rRNA.<sup>20-22</sup> *Kodamaea Ohmeri* is a rare, but emerging pathogen of wound and bloodstream infections. Prompt identification and treatment is crucial to improve patient outcome, especially when empiric treatment for common fungal infection are ineffective. This case is unique because *K. Ohmeri* was identified in wound culture with trauma as the precipitating condition. The majority of published cases of *K. Ohmeri* described it as a bloodstream pathogen found mostly in neonates and patients with central venous catheters.<sup>4-6,14-16</sup>

Furthermore, the majority of cases of *K. Ohmeri* published have been in Europe, India, Japan and South America with very few in the US.

There have been few other published reports of *K. Ohmeri* causing severe cellulitis making this a relevant topic. One published report was of a burn victim, an elderly female who presented with 45% TBSA of 3rd degree burns and receiving debridements and skin grafting.<sup>9</sup> This patient developed cellulitis with wound cultures growing multiple organisms including *Pseudomonas*. Similar to our patient, she worsened despite broad spectrum antibiotics until placed on appropriate antifungal therapy, unfortunately this patient died due to worsening sepsis and other complications. Another case report was of an elderly diabetic male with significant Cushing's disease and CAD, with cellulitis and subsequent worsening clinical status.<sup>23</sup> Final cultures grew *K. Ohmeri*, he was successfully treated with amphotericin and discharged. Although *K. Ohmeri* has exhibited resistance to fluconazole, in most cases it has remained susceptible to treatment with amphotericin or micafungin.<sup>5,9-11,14,21,23</sup> Our patient was on broad spectrum antibiotics and was not started on antifungal therapy with fluconazole until hospital day 3. In soft tissue infection, bacteremia is a more common cause of sepsis and fungal cultures take longer to grow.<sup>2</sup> Yeast identification and sensitivities returned on hospital day 9, and voriconazole and micafungin were started. In the literature, resistance of *K. Ohmeri* to caspofungin has been described, however the particular strain of our patient demonstrated susceptibility to the echinocandin class, micafungin (Figure 1F).<sup>22</sup>

The failure to identify a fungal organism in NSTI can lead to delayed treatment and potentially increased mortality for this subset of patients. Disseminated yeast infection should be considered as a source of sepsis in patients with negative bacterial, polymicrobial cultures, especially when identifiable risk factors are present including but not limited to diabetes or other immunocompromised or prolonged intravenous. Additional studies of this organism will elucidate complications of infection and help guide further management.

## CONCLUSION

*Kodamea Ohmeria* is a rare but emerging pathogen of wound and bloodstream infections. To our knowledge, this is the first case of *K. Ohmeri* described in the setting of NF in a diabetic younger adult, after a trauma. If not properly identified, yeast infections can lead to delayed treatment and potentially increased mortality for this subset of patients. Disseminated yeast infection, especially *K. Ohmeri*, should be considered as a source of sepsis in patients with identifiable risks factors and negative or polymicrobial cultures, with deterioration despite repeated debridements and broad-spectrum antibiotics. In such cases, an earlier addition of a broad-

spectrum antifungal, such as with micafungin, may be a more optimal initial coverage until final identification and sensitivities are obtained. Additional studies of *K. Ohmeri* will elucidate complications of infection and help guide further management.

*Funding: No funding sources*

*Conflict of interest: None declared*

*Ethical approval: Not required*

## REFERENCES

- Arif N, Yousfi S, Vinnard C. Deaths from necrotizing fasciitis in the United States, 2003-2013. *Epidemiology Infection*. 2016;144(6):1338-44.
- Misiakos EP, Bagias G, Patapis P, Sotiropoulos D, Kanavidis P, Machairas A. Current concepts in the management of necrotizing fasciitis. *Frontiers Surg*. 2014;1:36.
- Bergman M, Gagnon D, Doern GV. *Pichia Ohmeri* fungemia. *Diagnostic Microbiology Infectious Disease*. 1998;30(3):229-31.
- Socarras AJ, Torres RJP, Soler VJA, Guerrero C. Infeccion por *Kodamaea Ohmeri* en un recién nacido con una masa mediastinal. *Archivos Argentinos de Pediatría*. 2016;114(5):319-22.
- Vivas R, Beltran C, Munera MI, Trujillo M, Restrepo A, Garces C. Fungemia due to *Kodamaea Ohmeri* in a young infant and review of the literature. *Medical Mycology Case Reports*. 2016;13:5-8.
- Aldeen TS, Doiphode S, Han X. *Kodamaea (Pichia) ohmeri* fungaemia in a premature neonate. *J Med Microbiology*. 2006;55(2):237-9.
- Menon T, Herrera M, Periasamy S, Palanivelu V, Sikkhamani R, Wickes B. Oral candidiasis caused by *Kodamaea Ohmeri* in a HIV patient in Chennai, India. *Mycoses*. 2010;53(5):458-9.
- Ni B, Gu W, Mei Y, Miao K, Zhang S, Shao Y. A Rare Life-threatening *Kodamaea Ohmeri* Endocarditis Associated with Hemophagocytic Lymphohistiocytosis. *Revista Espanola de Cardiologia*. 2018;71(01):51-3.
- Tashiro A, Nei T, Sugimoto R. *Kodamaea Ohmeri* fungemia in severe burn: case study and literature review. *Medical Mycology Case Reports*. 2018;22:21-3.
- Mahfouz RA, Otrrock ZK, Mehawej H, Farhat F. *Kodamaea (Pichia) Ohmeri* fungaemia complicating acute myeloid leukaemia in a patient with haemochromatosis. *Pathology*. 2008;40(1):99-101.
- Capoor M, Gupta D, Verma P, Sachdeva H. Rare yeasts causing fungemia in immunocompromised and haematology patients: case series from Delhi. *Indian J Med Microbiology*. 2015;33(4):576.
- Chiu CH, Wang YC, Shang ST, Chang FY. *Kodamaea Ohmeri* fungaemia successfully treated with caspofungin. *International J Anti-microbial Agents*. 2010;35(1):98-9.
- Distasi M, Gaudio DT, Pellegrino G, Pirroni A, Passera M, Farina C. Fungemia due to *Kodamaea Ohmeri*: first isolating in Italy. Case report and review of literature. *J Med Mycology*. 2015;25(4):310-6.
- Kanno Y, Wakabayashi Y, Ikeda M. Catheter-related bloodstream infection caused by *Kodamaea Ohmeri*: A case report and literature review. *J Infection Chemotherapy*. 2017;23(6):410-4.
- Ruiz FM, Guinea J, Asensio PM. Fungemia due to rare opportunistic yeasts: data from a population-based surveillance in Spain. *Med Mycology*. 2016;55(2):125-36.
- Imbert J, Gomez J, Escudero R, Blasco J. Onicomicosis por levaduras no comunes en diabeticos de un centro de salud. *SEMERGEN Med de Familia*. 2016;42(7):449-57.
- Chander J, Stchigel AM, Izquierdo AA. Fungal necrotizing fasciitis, an emerging infectious disease caused by *Apophysomyces (Mucorales)*. *Revista Iberoamericana de Micología*. 2015;32(2):93-8.
- Chander J, Singla N, Kaur M. *Saksenaeya erythrospora*, an emerging mucoralean fungus causing severe necrotizing skin and soft tissue infections—a study from a tertiary care hospital in north India. *Infectious Diseases*. 2017;49(3):170-7.
- Lee JS, Shin JH, Kim MN. *Kodamaea Ohmeri* isolates from patients in a university hospital: identification, antifungal susceptibility, and pulsed-field gel electrophoresis analysis. *J Clin Microbiology*. 2007;45(3):1005-10.
- Santino I, Bono S, Borruso L. *Kodamaea Ohmeri* isolate from two immunocompromised patients: first report in Italy. *Mycoses*. 2013;56(2):179-81.
- Yang BH, Peng MY, Hou SJ, Sun JR, Lee SY, Lu JJ. Fluconazole resistant *Kodamaea Ohmeri* fungemia associated with cellulitis: case report and review of the literature. *Int J Infectious Diseases*. 2009;13(6):493-7.
- Eddouzi J, Lohberger A, Vogne C, Manai M, Sanglard D. Identification and antifungal susceptibility of a large collection of yeast strains isolated in Tunisian hospitals. *Med Mycology*. 2013;51(7):737-46.
- Shang ST, Lin JC, Ho SJ, Yang YS, Chang FY, Wang NC. The emerging life-threatening opportunistic fungal pathogen *Kodamaea Ohmeri*: optimal treatment and literature review. *J Microbiol Immunol Infection*. 2010;43(3):200-6.

**Cite this article as:** Jimenez M, Seltzer ES, Shakil J, Louis M. *Kodamaea Ohmeri*: a rare fungus causing a severe case of necrotizing fasciitis. *Int Surg J* 2020;7:2718-21.