

Case Report

Morgagni-Larrey parasternal diaphragmatic hernia masquerading as pleural effusion: an interesting presentation with review of literature

Amit Gupta^{1*}, Sudhir Kumar Singh¹, Anshuman Darbari², Durga Soumya S.¹, Rishit Mani¹

¹Department of Surgery, ²Department of Cardiothoracic and Vascular Surgery, All India Institute of Medical Sciences, Rishikesh, Uttarakhand, India

Received: 18 May 2020

Accepted: 18 June 2020

*Correspondence:

Dr. Amit Gupta,

E-mail: dramit2411@gmail.com

Copyright: © the author(s), publisher and licensee Medip Academy. This is an open-access article distributed under the terms of the Creative Commons Attribution Non-Commercial License, which permits unrestricted non-commercial use, distribution, and reproduction in any medium, provided the original work is properly cited.

ABSTRACT

Congenital diaphragmatic hernia (CDH) is a major malformation found in newborns and babies but rarely in adults. CDH is defined by the presence of a defect in the diaphragm, which permits the herniation of abdominal contents into the thorax. The diagnosis of CDH is based on clinical history, examinations and is confirmed by plain X-ray films and computed tomography scans. Here we report a case which was misdiagnosed at another centre as pleural effusion and managed by placement of intercostal tube drainage and later on diagnosed to be case of Morgagni-Larrey parasternal diaphragmatic hernia. Congenital diaphragmatic hernia (CDH) is a major malformation found in newborns and babies but rarely in adults. CDH is defined by the presence of a defect in the diaphragm, which permits the herniation of abdominal contents into the thorax. The diagnosis of CDH is based on clinical history, examinations and is confirmed by plain X-ray films and computed tomography scans. The purpose of reporting this case is to provide information on late-presenting CDH and to emphasize that a high index of suspicion is required for diagnosis and to avoid unwanted complications.

Keywords: Congenital diaphragmatic hernia, Pleural effusion, Laparoscopy

INTRODUCTION

Congenital diaphragmatic hernia (CDH) usually presents soon after birth and is an idiopathic malformation. The prevalence of CDH is 0.3-0.5/1000 births.¹ It predominantly occurs on left side and most common defect is postero-lateral type known as Bochdalek hernia. Defect at parasternal level is less common, known as Morgagni-Larrey parasternal hernia which is predominant on right side. Prenatal diagnosis of CDH can be made precisely in 60-90% cases on screening ultrasonography, which detects herniation of the bowel or liver into the thorax along with polyhydramnios in some severe cases.^{2,3}

Within first few hours of the life most of the cases with CDH present with respiratory distress. Cause of respiratory insufficiency is often secondary to pulmonary hypoplasia and persistent pulmonary hypertension.⁴ 5-30% of CDH present beyond neonatal period.⁵ Presentation of late-onset CDH can range from frequent respiratory tract infection, wheeze, non-specific gastrointestinal symptoms to cardio-respiratory failure. Clinical manifestations of CDH may be mild respiratory distress or may even be an unexpected finding during a medical check-up for any other reasons. In these cases, a hernial sac is most often present.⁶

A diagnosis of CDH is unanticipated if the patient is asymptomatic and diagnosed usually on radiological findings, especially on plain X-ray chest done for

respiratory symptoms. Computed tomography (CT) scan has highest sensitivity and specificity for a correct diagnosis and is the radiological investigation of choice.⁷ Delayed presentation of CDH in asymptomatic adults are described in the literature in a very few cases.

We report a case of CDH in adult patient who presented with herniation of abdominal viscera in the thorax, who was misdiagnosed as pleural effusion for which chest tube was inserted and came to our institute for non-resolving symptoms.

CASE REPORT

A 45 years old gentleman attended the surgical clinic with complaints of occasional chest discomfort and dyspnoea on exertion. He had earlier consulted at some private hospital for the same symptoms where on the basis of plain X-ray chest, diagnosis of right pleural effusion was made and intercostal tube was placed in right pleural cavity. As patient was not improving symptomatically and pleural effusion was not resolving on repeat chest X-ray, the patient was referred to our institute for further management.

On history, except for occasional chest discomfort and dyspnea on exertion, he did not have other symptoms such as chest pain, abdominal pain, dysphagia, vomiting, and dyspepsia. There was no history of trauma or surgery. On physical examination, there was remarkably decreased breath sounds and bowel sounds were heard on the right hemithorax. Chest X-ray revealed a smooth radio-opacity in lower part of right pulmonary area with air fluid level suggestive of intestinal loop (Figure 1).

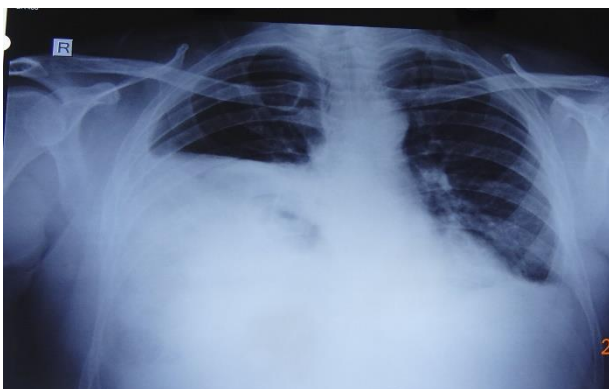


Figure 1: Chest X-ray (PA view) showing a smooth radio-opacity in lower part of right pulmonary area with air fluid level suggestive of intestinal loop.

Contrast-enhanced chest computed tomography (CT) showed a notable displacement of the abdominal viscera into the right thoracic cavity and the interrupted right hemi diaphragm at parasternal level. Slight atelectasis of the right lung was present along with lower part of right thoracic cavity was filled by transverse colon, small bowel loop and omentum (Figure 2).

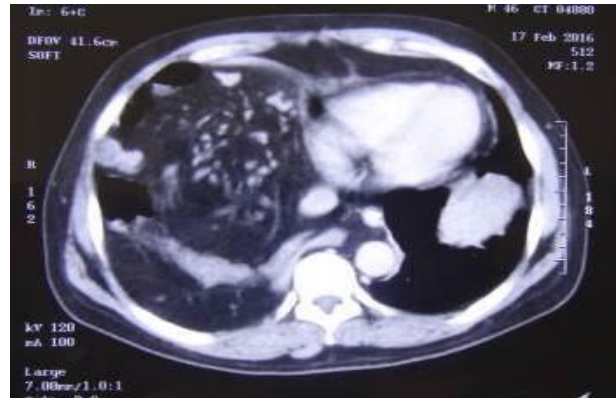


Figure 2: Contrast-enhanced computed tomography of thorax showing displacement of the abdominal viscera into the right thoracic cavity.

As the pre-operative diagnosis of right sided Morgagni hernia made, the patient was posted for surgery after pre-anesthetic check-up. Under general anaesthesia using a double lumen tube, laparoscopy through umbilical port was done to evaluate the defect and herniated viscera. The bowel loops including transverse colon and most part of small bowel along with omentum were herniating through the defect. All the herniated bowel loops were reduced laparoscopically. A large elliptical defect of size approximately 15x5 cm was noticed above the superior surface of liver in right hemi diaphragm (Figure 3 (a and b)).

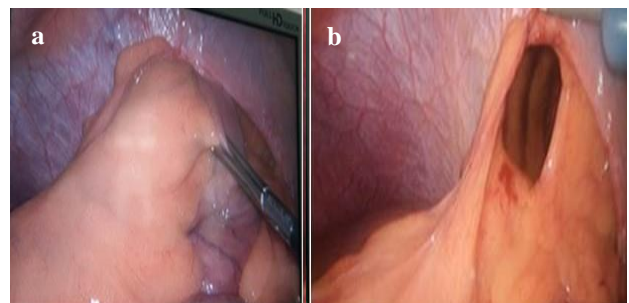


Figure 3: (a) Laparoscopic view of the herniated bowel loops into the right hemithorax and (b) defect in right hemidiaphragm after reducing the bowel loops.

Laparoscopic repair of defect was attempted but due to technical difficulty, a small right subcostal incision was given and the defect was repaired by continuous vicryl no-1 suture. Repair was reinforced by composite mesh which was fixed with polypropylene 3-0 suture. The right thoracic cavity was drained by an intercostal tube (28 F). In the post-operative period, the patient had an uneventful and smooth recovery. A repeated chest radiograph after 3 days of surgery revealed complete expansion of the right lung after which drain was removed (Figure 4). On the post-operative day 4, patient was discharged in stable condition. Patient is doing well after 48 months of surgery in follow up clinics.

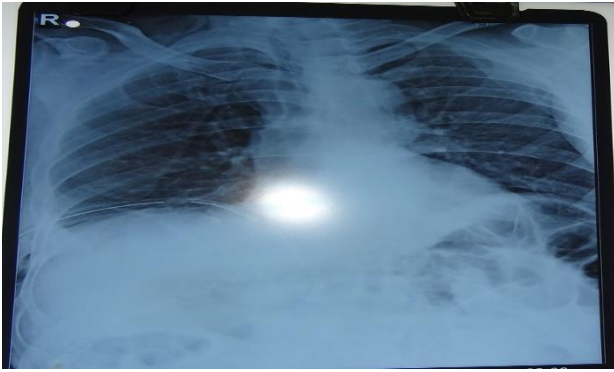


Figure 4: Chest X-ray (PA view) after 3 days of surgery showing complete expansion of the right lung.

DISCUSSION

During embryological development, the diaphragm is derived from several sources including the septum transversum, pleuroperitoneal membranes and the mesenchyma of the body wall. Normal diaphragm closure occurs at the eighth week. CDH is due to herniation of abdominal organs into the thoracic cavity through a weak area or a distinct defect in the diaphragm. Most frequent types of diaphragmatic hernia are the left posterolateral (Bochdalek hernia) and the sternocostal (Morgagni hernia) types. A Bochdalek hernia is most common CDH which occurs generally on left side of the diaphragm and results from insufficient closure of the posterolateral pleuroperitoneal membrane. Parasternal diaphragmatic hernia (PDH) through the sternocostal triangle also known as Morgagni hernias are rare diaphragmatic hernias represent 3-5% of all CDH and rarely accompanied by other congenital malformation.⁸

However most frequent cause of diaphragmatic herniation in adults is trauma, in neonates and adolescent it is most often attributable to congenital defect in fusion of the septum transversum or the pleuroperitoneal membrane and prenatal diagnosis can be made by ultrasonography in 60-90% of cases.⁹ Most CDH presents in the neonatal period with respiratory distress and can be life threatening. Diagnosis can readily be made on the basis of symptoms and physical signs. However physical examination may be sufficient, a plain X-ray chest can diagnose the herniation of bowel loops in to the thorax in most of the cases. Before a plain X-ray placing nasogastric tube in stomach may helpful in Bochdalek hernia in which the tip of catheter may be located in the imaging left side of thorax due to herniation of stomach.

Late presenting CDH in adults, usually asymptomatic and incidentally detected during plain X-ray films or CT scans for other symptoms not related to this pathology. Symptoms, if any, are typically imprecise. It may present with gastrointestinal tract symptoms that may include intermittent abdominal pain, vomiting, and dysphagia. Respiratory symptoms usually include dyspnea and chest pain. Depending on the extent of herniation of abdominal

viscera into the thorax, symptoms may be intermittent or acute. An acute presentation is usually due to incarceration, obstruction, or strangulation of the herniated viscera.¹⁰ Since our patient had asymptomatic diaphragmatic hernia, we presumed that diaphragmatic defects was congenital.

Diagnosis of CDH is made by a combination of chest examination, chest X-rays, CT and magnetic resonance imaging (MRI). In some cases, upper gastrointestinal and bowel double-contrast studies may be helpful to ascertain the diagnosis. On chest examination, there may be reduced air entry and presence of bowel sound in hemithorax as found in our case. Chest X-ray may reveal a radio-opacity in pulmonary area with air fluid level in presence of herniated bowel loop. CDH may be misdiagnosed as pleural effusion, pneumonia, tension pneumothorax, lung cysts, or atelectasis on the basis of chest X-ray; hence careful analysis of chest films and a thorough search for connecting bowel segments passing through the diaphragmatic defect may help to avoid incorrect diagnosis. The inappropriate insertion of chest drain may result in serious consequences by damaging intrathoracic viscera and bowel loops. Confusion with pneumonia or pneumothorax can be diminished by instillation of oral contrast material in cases with herniated bowel.¹¹

In diaphragmatic hernia, typical findings on a CT scan would be the abutment of fat or soft tissue along the upper surface of the diaphragm in anterolateral location on the hemidiaphragm in Morgagni hernia, diaphragmatic discontinuity adjacent to the mass, continuous density above and below the diaphragm through the defect and presence of bowel loops in hemithorax.¹²

For CDH, surgical repair should be performed in order to avoid serious complication. Management of CDH includes reducing the abdominal contents and repairing the defect through a laparotomy or thoracotomy. However laparoscopic approach is preferred approach, a successful laparoscopic and thoracoscopic repair of diaphragmatic hernias has been described in literatures.¹³ The outcome of adult patients suffering from congenital hernia depends on the type of clinical presentation. Prognosis is poorer when presentation is after strangulation or incarceration of the herniated bowel loops.

CONCLUSION

Late-presenting CDH is often difficult to diagnose, and delays in treatment are common. A diagnostic possibility of CDH should be kept in mind in patients presenting as a case of pneumothorax or hydro-pneumothorax, especially in absence of trauma. Thus, one can avoid inappropriate insertion of intercostal tube and related grave visceral injuries. In suspicious cases, accurate diagnosis can be made by computed tomography and upper or lower gastrointestinal contrast studies. All diaphragmatic

defects could be closed by an open or laparoscopic approach without post-operative complications. This case highlights the significance of early detection and prompt intervention in order to prevent life threatening complications. A high index of suspicion is required to correctly diagnose these cases as plain chest X-ray may be misleading.

Funding: No funding sources

Conflict of interest: None declared

Ethical approval: Not required

REFERENCES

1. Gattot D, Boda C, Ughetto S, Perthus I, Robert-Gnansia E, Francannet C, et al. Prenatal detection and outcome of congenital diaphragmatic hernia: a French registry-based study. *Ultrasound Obstet Gynecol.* 2007;29(3):276-83.
2. Davenport M, Holmes K. Current management of congenital diaphragmatic hernia. *Br J Hosp Med.* 1995;53(3):95-101.
3. Sinha CK, Islam S, Patel S, Nicolaidis K, Greenough A, Devenport M. Congenital diaphragmatic hernia: prognostic indices in the fetal endoluminal tracheal occlusion era. *J Pediatr Surg.* 2009;44(2):312-6.
4. Bronshtein M, Lewit N, Sujov PO, Markoul IR, Blazer S. Prenatal diagnosis of congenital diaphragmatic hernia: timing of visceral herniation and outcome. *Pren Diagn.* 1995;15(8):695-8.
5. Gleeson F, Spitz L. Pitfalls in the diagnosis of congenital diaphragmatic hernia. *Arch Dis Child.* 1991;66(6):670-1.
6. Numamoglu A, Steiner Z, Millar A, Cywes S. Delayed presentation of congenital diaphragmatic hernia. *S Afr J Surg.* 1997;35(2):74-6.
7. Gayer G, Bilik R, Vardi A. CT diagnosis of delayed presentation of congenital diaphragmatic hernia simulating massive leuropneumonia. *Eur Radiol.* 1999; 9(8):1672-4.
8. Bianchi E, Mancini P, Stefania DV, Pompili E, Taurone S, Guerrisi I, et al. Congenital asymptomatic diaphragmatic hernias in adults: a case series. *J Med Case Report.* 2013;7(1):125.
9. Nakayama DK, Harrison MR, Chrinn DH, Callen PW, Filly RA, Golbus MS, et al. Prenatal diagnosis and natural history of the fetus with a congenital diaphragmatic hernia: initial clinical experience. *J Pediatr Surg.* 1985, 20(2):118-24.
10. Sridhar AV, Nichani S. Late presenting congenital diaphragmatic hernia. *Emerg Med J.* 2004;21(2):261-2.
11. Baerg J, Kanthimathinathan V, Gollin G. Late-presenting congenital diaphragmatic hernia: diagnostic pitfalls and outcome. *Hernia.* 2012;16(4):461-6.
12. Wilbur AC, Gorodetsky A, Hibbeln JF. Imaging findings of adult Bochdalek hernias. *Clin Imaging.* 1994;18(3):224-9.
13. Yilmaz M, Isik B, Coban S, Sogutlu G, Ara C, Kirimlioglu V, et al. Transabdominal approach in the surgical management of Morgagni hernia. *Surg Today.* 2007;37:9-13.

Cite this article as: Gupta A, Singh SK, Darbari A, Soumya DS, Mani R. Morgagni-Larrey parasternal diaphragmatic hernia masquerading as pleural effusion: an interesting presentation with review of literature. *Int Surg J* 2020;7:2450-3.