

## Original Research Article

# Management of forgotten double-J stent in a tertiary care center with ten years of experience: a retrospective study

**Khalid Mahmood, Kamalkant Harishankar Singh\*, Rohit Upadhyay, Vijoy Kumar, Amit Kumar, Deelip K. Singh**

Department of Urology, Indira Gandhi Institute of Medical sciences, Patna, Bihar, India

**Received:** 26 May 2020

**Revised:** 21 June 2020

**Accepted:** 29 June 2020

### \*Correspondence:

Dr. Kamalkant Harishankar Singh,  
E-mail: [kamspreadsmiles@gmail.com](mailto:kamspreadsmiles@gmail.com)

**Copyright:** © the author(s), publisher and licensee Medip Academy. This is an open-access article distributed under the terms of the Creative Commons Attribution Non-Commercial License, which permits unrestricted non-commercial use, distribution, and reproduction in any medium, provided the original work is properly cited.

## ABSTRACT

**Background:** Forgotten double-J (DJ) stents is documented commonly in urological cases with consequences varying from encrustation, UTIs, pyelonephritis, hydronephrosis and non-functioning kidney. This study aimed to present the experience of managing patients with forgotten DJ stents (>3 months) over a period of ten years.

**Methods:** The study conducted a retrospective review of patients with forgotten DJ stents from January 2009 to December 2019. The details reviewed included indications for stent placement, indwelling time, presenting complaints, reason for non removal, radiological investigations, management techniques, and complications.

**Results:** 52 patients with forgotten DJ stents for >3 months were reviewed. Mean age was 32.1 years. The majority were literate (73.1%). Ureterscopy was the most common primary surgery performed (53.8%). The mean indwelling time was 38.96 months. Presence of the ureteric stone, bladder stone, and renal stone was observed in 45 (86.5%), 42 (80.7%), and 28 (53.8%) patients, respectively. The DJ stent was fragmented in 13.4% of the patients. The commonest complaints were pain (88.4%) and dysuria (63.4%). The stents were managed by combinations of various endourological techniques including cystoscopic stent retrieval (CPE), PCNL, URSL, ESWL with cystoscopic stent retrieval, PCLT (percutaneous cystolithotripsy). Cystolithotomy was used for very large bladder stones. Nephrectomy was needed in 2 cases due to nonfunctional kidneys while one required open ureterolithotomy and stent retrieval after failure of endoscopic approach.

**Conclusions:** Forgotten DJ stents have severe consequences and management approach requires combination of various endourological procedures with ESWL, URSL, PCNL, open ureterolithotomy and cystolithotripsy.

**Keywords:** Encrustation, Endourology procedures, DJ stent

## INTRODUCTION

Over the last few decades there are continuous advancements occurring in the technique of placement along with the materials used for preparation of ureteral stents. It has gained recognition from urologists all over the globe as a requisite technique in their routine urology-related surgical practices. Double J (DJ) ureteral stent is the most widely used indwelling stent for the management of patients with upper urinary tract obstruction symptoms.

Even though DJ stents come with various benefits, their placement for longer duration has severe consequences including hematuria, stent occlusion, migration, fragmentation, encrustation, and stone formation.<sup>1-5</sup> Most of the times patients tend to forget the removal of DJ stent in spite of written and verbal instruction thereby resulting in the emergence of complications such as stone formation and encrustation which may lead to hydronephrosis, urosepsis, and renal impairment. Therefore, forgotten DJ stent has become a challenging issue for urologists. Evidence of a wide spectrum of

endourological techniques for the management of DJ stents is present in the literature with few Indian studies.<sup>6-</sup>

<sup>9</sup> However, there is a lack of guidelines focused on the management of patients with forgotten DJ stent.

The present study intended to report the experience of the management of patients with forgotten DJ stents at a tertiary care center from North India over a period of ten years.

## METHODS

This was a retrospective study conducted at the Department of Urology, Indira Gandhi Institute of Medical Sciences, Patna, India. The study was approved by the Institutional Ethics Committee and the study procedure was in accordance with the principles of the Declaration of Helsinki.

### Sampling method

All patients who presented with forgotten double J (DJ) stents (>3 months without prolonged indications) and were managed at this institute during period January 2009 to December 2019 were included.

The patients were assessed and diagnosed on the basis of history, physical examination and ancillary investigation. The details reviewed included the indwelling time, primary surgery requiring stent placement, presenting complaints, radiological investigation, and procedures required for complete DJ stent removal. In all patients, the initial diagnosis was done by the kidney, ureter, bladder X-ray (KUB X-ray) and ultrasound of whole abdomen. Initial evaluation included urinalysis, serum levels of creatinine, whole blood count, urine culture and sensitivity test. A preoperative urine culture was obtained in all the patients, and when positive, culture-specific antibiotics were given. A prophylactic intravenous antibiotic was given during all the invasive procedure.

To evaluate stone burdens and stent encrustation, non-contrast computerized tomography (NCCT) and/or intravenous pyelography were performed. Renal function was assessed with diethylene triamine pentaacetic acid (DTPA) renography. The patient anatomy, stent encrustation, related stone burden, and status of the stent (broken or migrated stent) were evaluated with the help of KUB X-ray and/or NCCT.

To remove the stents and related stone burden various combinations of treatments extracorporeal shock wave lithotripsy (ESWL), percutaneous cystolithotripsy (PCLT), percutaneous nephrolithotomy (PCNL) and ureteroscopic lithotripsy (URSL) were used. Nephrectomy was performed in patients with nonfunctional kidney to avoid the morbidity of numerous interventions. Descriptive statistical analysis was performed and data was represented as number (%).

## RESULTS

The hospital records of a total of 52 patients of forgotten DJ stents were retrospectively reviewed. The mean age of patients was 32.1 years with male to female ratio of 3:1. The incidence of forgotten DJ stent was 26.9% in the patients who were illiterate, followed by other literate groups. The number of patients with placement of DJ stent on either left or right side were equal (50%, each).

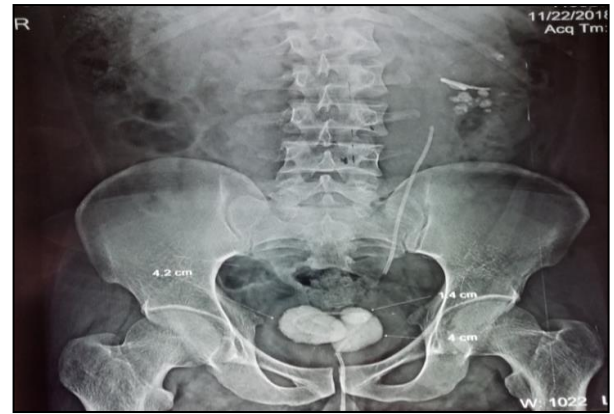
**Table 1: Patients and characteristics (n=52).**

Parameters	Total N (%)
<b>Age, years [mean (SD)]</b>	32.1 (9.22)
<b>Range</b>	8-54
<b>Sex</b>	
Men	39 (75.0)
Women	13 (25.0)
<b>Educational qualification</b>	
Illiterate	14 (26.9)
School	9 (17.3)
SSC	9 (17.3)
HSC	10 (19.2)
Graduate	8 (15.3)
Post-graduate	2 (3.8)
<b>Side</b>	
Left	26 (50.0)
Right	26 (50.0)
<b>Primary surgery</b>	
B/L DJ stent insertion	1 (1.9)
Percutaneous nephrolithotomy (PCNL)	9 (17.3)
Pyelolithotomy/Ureterolithotomy	2 (3.8)
Pyeloplasty	7 (13.4)
Ureteroneocystostomy	5 (9.6)
Ureteroscopy (URS)	28 (53.8)
<b>Indwelling time (months)</b>	38.96 (3-120)
<b>Location of stone (solitary or in combination)</b>	
Renal stone	28 (53.8)
Bladder stone	42 (80.7)
Ureteric stone	45 (86.5)
<b>Combination</b>	
Bladder stone + ureteric stone	17 (28.8)
Renal stone + bladder stone	5 (5.7)
Renal stone + ureteric stone	6 (11.5)
Renal stone + bladder stone + ureteric stone	19 (36.5)
Fragmented	7 (13.4)
<b>Symptoms</b>	
Pain	46 (88.4)
Dysuria	33 (63.4)
Acute urinary retention	4 (7.7)
Hematuria	5 (9.6)
Urinary tract infection	19 (36.5)
<b>Reasons</b>	
Forgot (F)	24 (46.1)
Did not know	28 (53.8)

Data shown as N (%), unless otherwise specified.

In the majority of patients, URSL (53.8%) was the primary surgery performed leading to DJ stent placement; however, other procedures requiring DJ stent insertion were PCNL (17.31%), pyeloplasty (13.46%), ureteroneocystostomy (9.62%), pyelithotomy (3.84%), bilateral ureteric obstruction (1.92%). The average indwelling time of the ureteral stents was 38.96 months (range, 8 120 months) (Table 1).

Among all the patients who had DJ stent insertion, presence of the ureteric stone, bladder stone, and renal stone was observed in 45 (86.5%), 42 (80.7%), and 28 (53.8%) patients, respectively. Presence of combination of stones in all three locations (36.5%) was most common than that of two locations (mostly bladder and ureter) among the total study population. The incidence of fragmented DJ stent was observed in 13.4% of the patients. Two patients with forgotten DJ stents had solitary kidneys.



**Figure 3: X-ray KUB showing forgotten and fragmented left DJ stent with bladder and renal stone formation.**

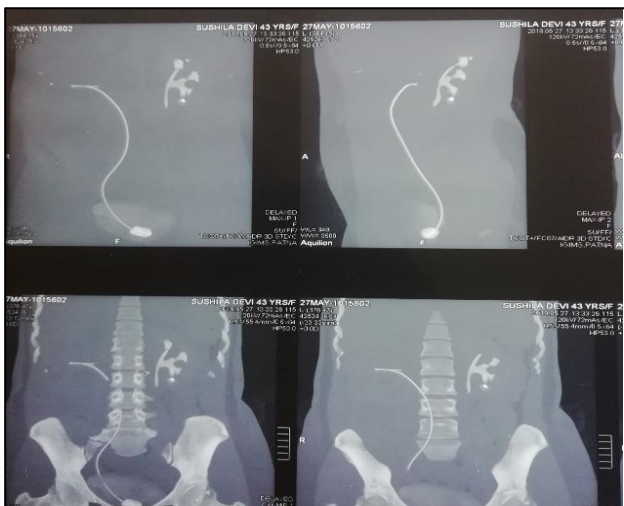24 (46.15%) patients were aware about DJ stent but did not report while 28 (53.85%) of patients were unaware of the DJ stents. Among all the patients, pain was the most common adverse event (88.4%), followed by dysuria (63.4%), urinary tract infection (36.5%), hematuria (9.6%) and acute urinary retention (7.7%) (Table 1).

**Table 2: Management of forgotten DJ stents (n=52).**

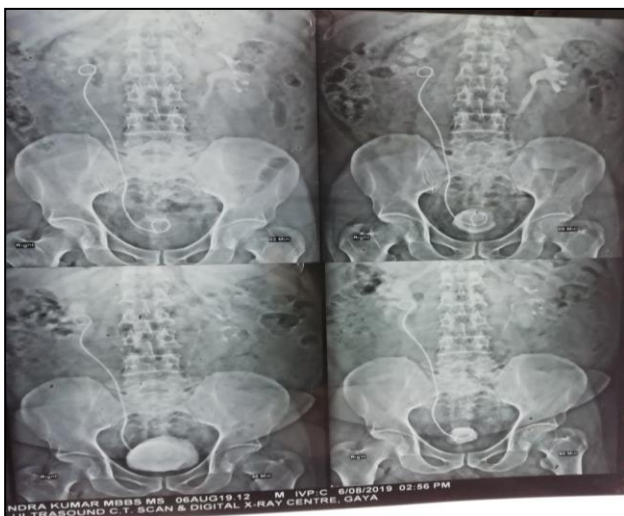
Treatments	Total N (%)
URSL	7 (13.5)
CPE	9 (17.3)
Cystolithotomy + Nephrectomy	1 (1.9)
Cystolithotomy + URSL	2 (3.8)
Cystolithotripsy	3 (5.7)
PCLT	1 (1.9)
ESWL + Cystolithotripsy	1 (1.9)
ESWL + DJ removal	4 (7.7)
ESWL + PCLT + URSL	1 (1.9)
ESWL + URSL + Cystolithotripsy	4 (7.7)
PCLT + ESWL + DJ removal	1 (1.9)
PCLT + Nephrectomy	1 (1.9)
PCLT + PCNL	1 (1.9)
PCLT + URSL	3 (5.7)
PCNL + Cystolithotripsy + URSL	6 (11.5)
Open ureterolithotomy + DJ removal	1 (1.9)
PCNL + URSL	1 (1.9)
URSL + Cystolithotripsy	1 (1.9)
URSL + DJ removal	2 (3.8)
URSL + PCLT	2 (3.8)

Data shown as n (%), unless otherwise specified.  
 DJ, double J; ESWL, extracorporeal shock wave lithotripsy; PCLT, percutaneous cystolithotripsy; PCNL, percutaneous nephrolithotomy; URSL, ureteroscopic lithotripsy

The DJ stents were retrieved in 50 patients. Most were managed by a combination of endourological techniques. Nine patients managed with simple cystoscopic DJ



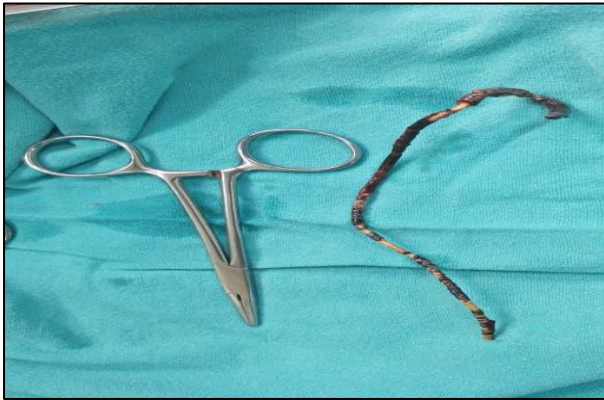**Figure 1: CT showing non functioning right kidney with forgotten DJ stent.**



**Figure 2: IVP showing right forgotten DJ stent with UB calculus.**



removal which included one patient with 10 years period of indwelling DJ stent. For proximal renal calculus, PCNL was done in nine patients while URSL was done in 15 patients. One patient required conversion to open ureterolithotomy after PCNL and cystolithotripsy combination failed. ESWL with cystolithotripsy was done in eight patients, however, ESWL along with URSL was performed in five patients. Two patients were managed by cystolithotripsy. Two patients required nephrectomy as their renal unit had become nonfunctional (Table 2).



**Figure 4: DJ stent retrieval done by open surgery after failure of endoscopic approach.**

## DISCUSSION

El-Faqih et al reported that encrustation occurred in 9.2% of stents retrieved before 6 weeks, 47.5% of stents left in place for 6 to 12 weeks, and 76.3% of stents left in place longer than 12 weeks.<sup>1</sup> Definition of “forgotten” Double J ureteric stent is not standardized, with various studies considering a period of 3 to 6 months to define a forgotten DJ stent.<sup>6</sup> Associated morbidity was found to be minimal if indwelling times did not exceed 6 weeks. Regardless of the stent composition, manufacturers usually recommend exchange of stents at 3 to 6-month intervals. We had one case at 4 months that required cystolithotripsy for stent removal while one case with indwelling time of 29 months had minimal encrustations and was managed by cystoscopic removal.

Several previous studies highlighted the importance of timely removal of the DJ stent to prevent development of complications associated with prolongation of indwelling time.<sup>6,9-12</sup> However, patient’s forgetfulness or ignorance or incomplete knowledge regarding prolonged DJ stent complications as well as physician’s inadequate counselling regarding timely removal of ureteral stents are the two key reasons that attribute to the forgotten DJ stents and associated complications. Stent registry has long been suggested as a measure to prevent this event. Lynch et al, Sabharwal et al and Patil et al reported use of computer-based registry system and patient directed automated notification to prevent incidence of retained DJ stent.<sup>13-15</sup> Use of biodegradable stent and metallic

stents is under study and may be feasible preventing long term complications of retained ureteric stents.<sup>16-18</sup>

The present study revealed that the complications emerged due to forgotten DJ stent included encrustation and stone formation in ureter, bladder and kidney of patients, fragmentation of stent, pain, dysuria, hematuria and urinary tract infection. Encrustation is a common complication of forgotten DJ stent and the rate of encrustation is directly proportional to the indwelling time.<sup>1</sup> Type of material used for stent also impacts encrustation due to their resistance power to encrustation.<sup>19</sup> In the present study, the average indwelling time of the ureteral stents was 38.96 months. Previous studies reported varied range of indwelling period. In the study by Thapa et al, indwelling time was four months to 10 years.<sup>10</sup> Another study by Gupta et al reported mean (SD) indwelling time of 11 (5.5) months with two patients having an indwelling time of 24 months.<sup>20</sup> Similarly, Adanur et al demonstrated the average indwelling time of the ureteral stents was 22.6 (6-144) months in their study patients.<sup>21</sup> However, Sohrab et al observed longest mean indwelling time of 102.9 months (median 23 months).<sup>6</sup> A recent study by Thapa et al reported management details of 27 patients with forgotten DJ stent. They revealed that stent syndrome was mode of presentation in 74% followed by encrustation or stone formation in 29.5% and urinary tract infection in 15%. Urinary bladder was the common site of encrustation (59.2%). Endourological approach was used in majority (92.5%) of the patients out of which 26% of patients were managed with more than one modality of treatment.<sup>10</sup>

In a decade old study done by Damiano et al flank pain (25.3%) and encrustations (21.6%) were common complications followed by irritative bladder symptoms (18.8%), hematuria (18.1%), UTI (12.3%), and stent migration (9.5%).<sup>11</sup> On the other hand, Sohrab et al observed irritative bladder symptoms and hematuria as the predominant complications while flank pain was relatively less common. They further reported 14.2% of mortality among 28 study patients within the duration of 13 years.<sup>6</sup>

A study from Pakistan conducted during 2015-2016 included 16 patients with forgotten DJ stent. Incidence of urinary tract infection (37.5%) and mild encrustation (43.8%) was prevalent with the mean (SD) indwelling time of 16.31 (32) months. A significant morbidity was observed in a patient with a forgotten stenting period of 85 months, leading to a non-functioning kidney and nephrectomy.<sup>12</sup> Agarwal et al showed LUTS as the most common complication followed by hematuria and flank pain. Additionally, they demonstrated association of longer duration of stent retention with increased frequency of encrustations, infections, calculus formation and obstruction of the stented tract.<sup>9</sup>

Management of forgotten DJ stents is mainly dependent on the site of encrustation, the size of the stone burden and the function of the affected kidney. Management of these complicated forgotten DJ stents was achieved by multimodality approach which included PCNL, URSL, ESWL, cystoscopic removal, cystolithotripsy, and nephrectomy. Previous studies have reported use of multiple endourological approaches and/ open surgeries.<sup>6,9-12</sup> In the present study, majority of patients were managed with URSL alone, while eight patients were managed with combination of ESWL and cystolithotripsy. Nephrectomy was the preferred choice for patients with non-functioning kidneys.

A study by Gupta et al reported management of patients with forgotten DJ stent in 33 patients with endourological procedure [CPE (n=17)], PCNL for proximal renal calculus (n=7), ureteroscopy with pneumatic lithotripsy (n=6) and cystolithotripsy (n=3). Two patient required nephrectomy.<sup>20</sup> Thapa et al reported cystoscopic removal (n=15) of forgotten DJ stents in the majority of their study patients.<sup>10</sup> Nerli et al retrospectively reviewed a series of 14 children with forgotten/retained DJ ureteric stents and reported multimodal approach for removal of forgotten DJ stent. They used a combination of ESWL, cystolitholapaxy and PCNL to free the DJ stent and extract it.<sup>7</sup> In a recently published study, management of the ureteral stents and related stones were successfully done by combined endourologic techniques to achieve a stone-free state in all patients except for patient with 110 months of forgotten stent time in whom nephrectomy was performed for a nonfunctioning kidney related to the forgotten stent.<sup>21</sup>

It was a retrospective study. In absence of specific guidelines and sufficient data, surgical procedures performed for management of forgotten DJ stent were mainly based on guidelines for urolithiasis and choice, comfort and experience of the operating surgeons. No data on DJ stent registry and attempts to contact patient by medical team for the same was available to assess its effectiveness.

## CONCLUSION

In conclusion, the present study observations corroborate with the previous studies confirming varied range of complications are associated with forgotten DJ stents and individualized management strategies are necessary. Therefore, combinations of various endourological procedures with ESWL, PCNL and cystolithotripsy can aid in the management of complications of forgotten DJ stents. Proper post-operative counselling involving patient himself rather than relatives along with a DJ stent diary or newer software technology to serve as a reminder for both physicians and patients is a simple, cost effective and necessary preventive strategies that can save undue morbidity to the patients.

*Funding: No funding sources*

*Conflict of interest: None declared*

*Ethical approval: The study was approved by the Institutional Ethics Committee*

## REFERENCES

1. el-Faqih SR, Shamsuddin AB, Chakrabarti A, Atassi R, Kardar AH, Osman MK, et al. Polyurethane internal ureteral stents in treatment of stone patients: Morbidity related to indwelling times. *J Urol.* 1991;146:1487-91.
2. Mohan-Pillai K, Keeley FX Jr, Moussa SA, Smith G, Tolley DA. Endourological management of severely encrusted ureteral stents. *J Endourol.* 1999;13:377-9.
3. Schulze KA, Wettlaufer JN, Oldani G. Encrustation and stone formation: Complication of indwelling ureteral stents. *Urology.* 1985;25:616-9.
4. Singh V, Srinivastava A, Kapoor R, Kumar A. Can the complicated forgotten indwelling ureteric stents be lethal? *Int Urol Nephrol.* 2005;37:541-6.
5. Singh I, Gupta NP, Hemal AK, Aron M, Seth A, Dogra PN. Severely encrusted polyurethane ureteral stents: Management and analysis of potential risk factors. *Urology.* 2001;58:526-31.
6. Sohrab A, Aneesh S, Sureka SK, Varun M, Nitesh P, Manoj K, et al. Forgotten reminders: An experience with managing 28 forgotten double-J stents and management of related complications. *Indian J Surg.* 2015;77:1165-71.
7. Nerli RB, Magdum PV, Sharma V, Guntaka AK, Hiremath MB, Ghagane S. Forgotten/retained double J ureteric stents: A source of severe morbidity in children. *Afr J Paediatr Surg.* 2016;13:32-5.
8. Kelkar V, Patil D. Management of forgotten double J stent and severe multiple large encrusted stones in the bladder and renal pelvis. *Cent Eur J Urol.* 2012;65:238-41.
9. Agarwal S, Sarpal R, Pathak P, Biswas M, Mittal A, Rathore K, et al. Tricks and tacks in the management of the forgotten double J stent. *Int Surg J.* 2018;5:792-5.
10. Thapa BB, Thapa N, Bhandari BB. Fate of forgotten DJ stent. *Med J Shree Birendra Hosp.* 2018;17(2):38-43.
11. Damiano R, Oliva A, Esposito C, De Sio M, Autorino R, D'Armiento M. Early and late complications of double pigtail ureteral stent. *Urol Int.* 2002;69:136-40.
12. Anwar MS, Farooq M, Ayub M, Shah AA, Akhter SH, Qureshi AM. Management of forgotten ureteral double J stents: Causes and management. *Ann Punjab Med Coll.* 2017; 11: 227-32.
13. Lynch MF, Ghani KR, Frost I, Anson KM. Preventing the forgotten ureteral stent: Implementation of a web based stent registry with automatic recall application. *Urology.* 2007;70:423-6.

14. Sabharwal S, Macaden AR, Abrol N, Mukha RP, Kekre NS. A novel computer based stent registry to prevent retained stents: Will patient directed automated short message service and letter generator help? *Indian J Urol.* 2014;30:150-2.
15. Patil SM, Magdum PV, Shete JS, Nerli RB, Hiremath MB. Forgotten DJ stent- a source of morbidity: Is stent registry a need of the hour? *Int J Recent Sci Res.* 2015;6:2674-6.
16. Schlick RW, Planz K. In vitro results with special plastics for biodegradable endoureteral stents. *J Endourol.* 1998;12:451-5.
17. Kulkarni R, Bellamy E. Nickel-titanium shape memory alloy Memokath 051 ureteral stent for managing long-term ureteral obstruction: 4-year experience. *J Urol.* 2001;166:1750-4.
18. Lang EK, Irwin RJ, Lopez-Martinez RA, LaNasa Jr J, Kasabian N, Watson RA. Placement of metallic stents in ureters obstructed by carcinoma of the cervix to maintain renal function in patients undergoing long-term chemotherapy. *Am J Roentgenol.* 1998;171(6):1595-9.
19. Tunney MM, Keane PF, Jones DS, Gorman SP. Comparative assessment of ureteral stent biomaterial encrustation. *Biomaterials.* 1996;17:1541-6.
20. Gupta R, Gupta A, Anand A, Azad T. Forgotten DJ stent a nagging problem-management and long term follow up. *JK Sci.* 2017;19:110-4.
21. Adanur S, Ozkaya F. Challenges in treatment and diagnosis of forgotten/encrusted double-J ureteral stents: The largest single-center experience. *Ren Failure.* 2016;38:920-6.

**Cite this article as:** Mahmood K, Singh KH, Upadhyay R, Kumar V, Kumar A, Singh DK. Management of forgotten double-J stent in a tertiary care center with ten years of experience: a retrospective study. *Int Surg J* 2020;7:2615-20.