

## Case Report

# Cystic lymphangioma of abdominal wall in an adult: a rare site

Krishnanand Anand, Vishal Bansal\*, Palak Paliwal

Department of Surgery, L. N. Medical College and J. K. Hospital, Bhopal, Madhya Pradesh, India

**Received:** 13 May 2020

**Accepted:** 18 June 2020

**\*Correspondence:**

Dr. Vishal Bansal,

E-mail: [drbansal.vb@gmail.com](mailto:drbansal.vb@gmail.com)

**Copyright:** © the author(s), publisher and licensee Medip Academy. This is an open-access article distributed under the terms of the Creative Commons Attribution Non-Commercial License, which permits unrestricted non-commercial use, distribution, and reproduction in any medium, provided the original work is properly cited.

### ABSTRACT

Cystic lymphangiomas are rare, congenital, benign lesions occurring early in life, mainly in the head, neck, and oral cavity, rarely occur in abdominal wall and its discovery in adult is also very rare. It is due to aberrant proliferation of lymphatic vessels resulting from abnormal development of the lymphatic system. These are soft, variable in size and shape and tend to grow extensively if not surgically excised. These are multilocular cysts filled with clear or yellow lymph fluid, sometime mixed with blood. The present case report describes a case of cystic lymphangioma of right lower abdominal wall in a 36 years old male and its clinical, ultrasonographic, CECT, and histopathological correlation.

**Keywords:** Cystic lymphangioma, Abdominal wall, Lymphatic system, Very rare

## INTRODUCTION

Lymphangiomas are rare benign tumors of lymphatic origin. They are preferentially located in the head and neck 75%, and axilla 20% in children.<sup>1</sup> They are slow growing tumors and usually located in one organ but once they infiltrate into local tissue, surrounding muscles and adjacent nerves and vessels, then surgical removal becomes difficult. Other sites are in the maxilla, superior mediastinum, mesentery, retroperitoneal region, pelvis and lower limbs.<sup>2,3</sup> Rarely it occurs on the abdominal wall. There is no predilection for either sex the etiology is unclear, but they are considered due to failure of communication between the primary lymphatic sacs to drain into the venous system.

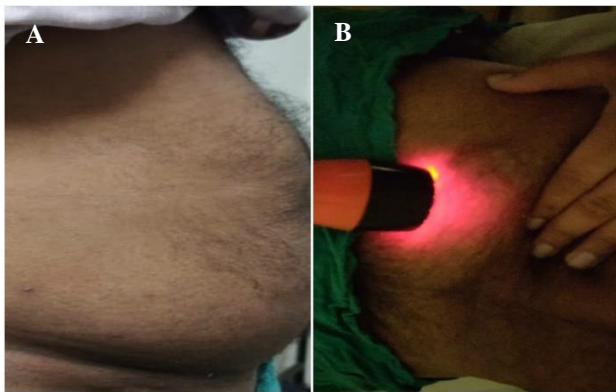
Abdominal ultrasonography and computed tomography are necessary in describing the cyst and providing important information regarding its location, size, and adjacent organs involvement.<sup>4</sup> Several treatments of cystic lymphangioma have been reported. We present a rare case of a lymphangioma in the abdominal wall. who underwent complete surgical resection with no recurrence.

## CASE REPORT

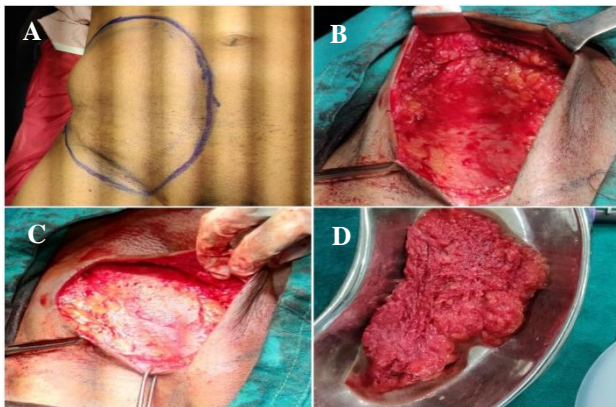
A 36 years male admitted in surgery department with chief complaint of swelling in right lower abdominal wall. This swelling was since birth, which has progressively increased in size and he also had a history of needle aspiration multiple times in past but got no relief. On physical examination (Figure 1) there was a palpable soft, non-tender swelling of 15x10 cm size seen in subcutaneous plane of right lower lateral abdominal wall with transillumination test positive. The overlying skin was normal. All laboratory test results were normal. Ultrasound study of abdomen reveals large subcutaneous multilocular clusters of abnormal cystic channels with internal echoes of 10x12 cm size in right lower abdominal wall. There was no abnormal vascularity seen on color doppler. No obvious invasion of muscles was seen. CECT abdomen findings showed a non-enhancing fluid density irregular lesion in subcutaneous plane in anterior abdominal wall on right side, it measures about 2.3x12.2x13.4 cm and there was no evidence of intraabdominal extension. The aspiration cytology from the lesion showed predominantly lymphocytes against a proteinaceous background suggestive of lymphangioma.

### Surgical intervention

Marking of the lesion was done (Figure 2) and operated under spinal anaesthesia supine position was given. Curvilinear incision was given over the swelling 2cm above inguinal crease of around 10cm and skin flaps was raised to excise the tumor. On aspiration lymphatic fluid was seen after which whole of the tumor was excised along the border. There was no intraperitoneal extension. Negative suction drain was placed and wound was sutured in double layer and compression dressing was done. Patient recovered well drain was removed on 5<sup>th</sup> post-operative day and patient discharged on 7<sup>th</sup> day. There was no sign of any recurrence in the follow up to six weeks.



**Figure 1: (A) Showing swelling in right lower abdomen and (B) showing transillumination test positive over cystic lesion.**



**Figure 2: (A) Marking of swelling, (B) flaps after dissection of subcutaneous plane, (C) lymphangioma along all border and (D) excised specimen.**

### DISCUSSION

The lymphatic system develops as sac like out growth from the endothelium of veins in the fifth week of gestation. Six primary lymph sacs develop, two in jugulars, two iliac, one retroperitoneal and one cisterna chyli. Failure of communication with lymph system results in formation of cystic lymphangioma.<sup>5</sup>

Approximately, 65% of cystic lymphangiomas are apparent at birth, and 90% appear at the end of the second year.<sup>1</sup> Abdominal wall lymphangioma is a rare condition. The diagnosis of cystic lymphangioma is made by physical examination, transillumination and ultrasonography. Clinically, it occurs as a large, soft, cystic mass. Transillumination can help differentiate it from solid tumors. Ultrasonography shows a characteristic multi-lobular cystic mass that contains a septum of variable thickness. Doppler ultrasonography should be done to detect any vascular component of the cystic lymphangioma. Aspiration cytology of the lesion was showing predominantly lymphocytes against a proteinaceous background. Surgical excision is considered as a standard treatment. Incomplete excision often results in recurrence. Other complications include damage to surrounding blood vessels, nerves, infection, hypertrophied scar and lymphatic discharge from the wound.<sup>6</sup> Other types of adjuvant treatment have been proposed, such as radiotherapy, injection of sclerosing agents via 100% ethanol or OKT-432, but they are controversial.<sup>7</sup> Systemic chemotherapy and interferon- $\alpha$  have been tried with limited success for patients with extensive inoperable lesions.<sup>8</sup> Reports of malignant alteration are unfounded. When the lesion has been completely excised, it is thought that the prognosis is good. We presented a rare case of cystic lymphangioma in the abdominal wall that was treated with complete surgical resection.

### CONCLUSION

Cystic lymphangioma is a commonly seen in paediatric age but very rare in adult. Abdominal wall is uncommon site of involvement, should be kept in differential diagnosis of cystic lesions. From the above we can conclude that, preoperative diagnosis of lymphangioma is usually difficult due to its variable misleading clinical presentations, rarity of the disease, and its resemblance to many other intra-abdominal cysts. Complete surgical excision is the treatment of choice of it to avoid cyst complications and reduce the incidence of recurrence. The definitive diagnosis is made only after histopathological examination of the excised specimen.

*Funding: No funding sources*

*Conflict of interest: None*

*Ethical approval: Not required*

### REFERENCES

1. Chen CW, Hsu SD, Lin CH, Cheng MF, Yu JC. Cystic lymphangioma of the jejunal mesentery in an adult: a case report. *World J Gastroenterol.* 2005;11:5084-6.
2. Panditt SK. Cystic lymphangioma with special reference to rare sites. *Indian J Pediatr.* 2000;67:339-41.
3. Aimanan K, Pian PM, Thangrathnam RR, Azim M, Padmanaban B, Guan CL, et al. Case report of chest

- wall cystic hygroma in a teenager. *Med J Malaysia.* 2016;71:5.
4. Bansal H, Jenaw RK, Mandia R. Huge Mesenteric Lymphangioma: A Rare Cause of Acute Abdomen. *Int J Health Res.* 2010;3:195-8.
  5. Snehansu Pan. A rare site of Cystic Hygroma. *IOSR J Dent Med Sci.* 2015;14(11):10-11.
  6. Ngoc T. Cystic hygroma in children: a report of 126 cases. *J Pediatr Surg.* 1974;9(2):1915.
  7. Ninh TN, Ninh TX. Cystic hygroma in children: a report of 126 cases. *J Pediatr Surg.* 1974;9:191-5.
  8. Turner C, Gross S. Treatment of recurrent suprahyoid cervicofacial lymphangioma with intravenous cyclophosphamide. *Am J Pediatr Hematol Oncol.* 1994;16:325-8.

**Cite this article as:** Anand K, Bansal V, Paliwal P. Cystic lymphangioma of abdominal wall in an adult: a rare site. *Int Surg J* 2020;7:2725-7.