

## Case Report

# Lumbar spine metastasis in a breast cancer survivor after twelve years of disease-free survival

Okwuoma Okwunodulu\*, Moses O. Inojie, Francis C. Campbell,  
Chika A. Ndubuisi, Samuel C. Ohaegbulam

Department of Neurosurgery, Memfys Hospital, KM-2 Enugu-Onitsha Expressway, Enugu, Nigeria

**Received:** 02 April 2020

**Accepted:** 10 June 2020

### \*Correspondence:

Dr. Okwuoma Okwunodulu,  
E-mail: [okwufine@gmail.com](mailto:okwufine@gmail.com)

**Copyright:** © the author(s), publisher and licensee Medip Academy. This is an open-access article distributed under the terms of the Creative Commons Attribution Non-Commercial License, which permits unrestricted non-commercial use, distribution, and reproduction in any medium, provided the original work is properly cited.

## ABSTRACT

Spine metastasis is a common occurrence in breast cancer. The median time of spine metastasis from the diagnosis of breast cancer is approximately 3 years. In this case report, a 55 years old woman presented with insidious onset and progressively worsening severe low back pain. Spine MRI revealed L4-S1 heterogeneous marrow signal changes with L5 vertebral body collapse. She had undergone surgery, radiation, and chemotherapy for breast cancer 12 years prior. Although she had not received any anticancer treatment for 12 years, but she has been on regular follow up with the oncology team with no clinical evidence of local tumour recurrence. She had laminectomy and biopsy and the histological diagnosis was metastatic adenocarcinoma from breast cancer. She had palliative external beam radiation therapy and systemic chemotherapy with improvement in Karnofsky performance. We present a case of dormant micro metastasis re-activated 12 years after perceived cure for breast cancer.

**Keywords:** Spine metastasis, Breast cancer, Local tumour recurrence

## INTRODUCTION

Breast cancer is the most commonly diagnosed malignancy and is the second leading cause of cancer-related death in the western world.<sup>1,2</sup> Spine metastasis commonly occurs in breast cancer, accounting for approximately two-thirds of the osseous metastases discovered.<sup>2,3</sup> The incidence of spine metastasis from breast cancer is increasing because patients with primary breast cancer are surviving longer.<sup>2</sup> Median time to spine metastasis is about 42 months with the longest reported interval of 97 months.<sup>4</sup> We report a rare case of spine metastasis diagnosed 12 years (144 months) in a breast cancer survivor.

## CASE REPORT

A 55 years old woman presented with complaints of low back pain of 10 months duration and difficulty with

walking of seven months duration. The low back pain was insidious onset, but has worsened progressively with a visual analogue score of 8/10. There was associated bilateral lower limbs radiculopathy, paraesthesia and neurogenic claudication with decreasing claudication distance. Three months later she developed progressively worsened lower limbs weakness that is worse on the left with inability to walk. There was no sphincter dysfunction. Past surgical history revealed left radical mastectomy with adjuvant chemotherapy and radiotherapy for a triple negative invasive ductal carcinoma (stage 2) 12 years earlier. She had remained disease free following completion of adjuvant chemoradiation 12 years prior to presentation.

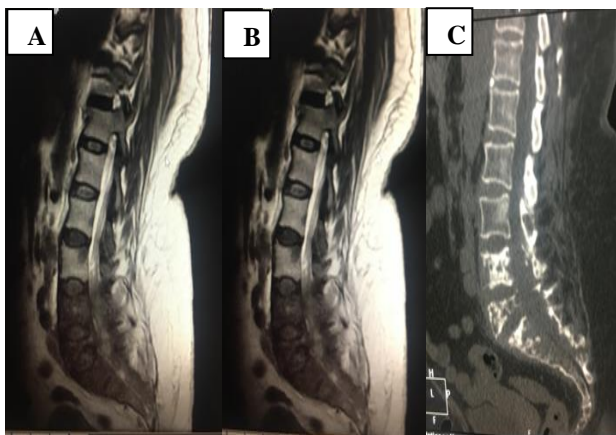
On examination her vital signs were within normal ranges. She has a Glasgow coma score (G.C.S) of 15/15 with intact higher cerebral and cranial nerves functions. Tone was normal in all the limbs. Power (myotomes) in

the lower limbs were; grade 4/5 on the left L3, grade 3/5 each left L4 to S1, grade 4/5 on the right L3 to S1, and grade 5/5 in both upper limbs. Deep tendon reflexes were depressed on the left lower limbs. Plantar reflex was flexion bilaterally. Fine touch and pin prick sensation were reduced on L3 and L4 dermatomes bilaterally. Joint position was normal both lower extremities. She had tenderness on the lumbosacral region, other musculoskeletal system examinations were unremarkable. Chest examination revealed a primarily healed left mastectomy scar and was clinically clear on auscultation. The right breast was normal. Abdominal examination was normal.

X-ray of the lumbosacral spine showed destruction of pedicles at L4/L5 and adjoining upper sacrum. Dynamic X-ray studies of the lumbar spine showed grade 1 anterolisthesis of L5 on S1.

Magnetic resonance imaging (MRI) of the lumbosacral spine showed L4/L5/S1 heterogeneous marrow signal changes with L5 vertebral body collapse with associated spinal canal/neuraforaminal/lateral recess narrowing and theca sac/cauda equina compression.

Spine computed tomography showed multiple lytic lesions involving bodies and posterior elements of L4, L5, and sacrum, consistent with metastatic spine disease. The thoracic spine was normal.

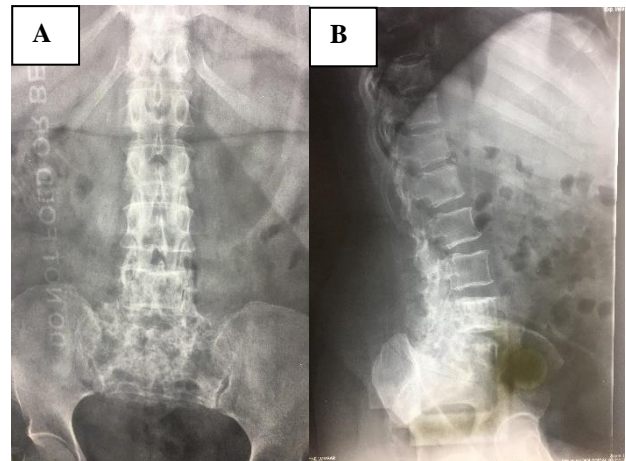


**Figure 1: Lumbosacral T2WI MRI (A and B) T2WI MRI shows multiple heterogeneous marrow signal changes involving the lumbosacral vertebrae with L5 vertebral body collapse and associated cauda equina compression and (C) CT scan showing multiple lytic lesions involving bodies and posterior elements of L4, L5, and the sacrum.**

Mammography and abdomino-pelvic ultrasonography were normal. Chest X-ray showed mild hypertensive heart changes and no evidence of metastatic deposit noted. ECG was normal.

She was optimized and had left sided L4 and L5 laminectomy with exit foraminotomy plus L4, L5, S1 laminar biopsy. Intraoperative findings showed a dark

unhealthy soft tissue infiltrating the lower lumbar and sacral bones facets of L4-S1, pathologically softened L4-S1 vertebrae with theca compression at L4-L5 plus left L3/L4 exit foramina stenosis. Histology revealed an ER (estrogen receptor), PgR (progesterone receptor), and Her-2 neu receptors negative (triple negative) metastatic breast ductal adenocarcinoma similar to the former disease. She had palliative fractionated external beam radiotherapy and single agent chemotherapy with docetaxel. She is currently being considered for additional treatment with capecitabine following improvement in karnofsky performance.



**Figure 2: Lumbosacral plain X-rays (A) anterior-posterior and lateral and (B) showing multiple osteosclerotic changes involving anterior and posterior elements of lower lumbar and sacral vertebrae suggestive of metastasis.**

She had significant pain relieve and good neurologic improvement with left lower limb L3-S1 power improved to 4+/5 and she currently ambulates with a walking stick. She has since returned to work.

## DISCUSSION

The extremely long 12 years disease free survival with the occurrence of spine metastasis in this patient who has had complete oncologic care for stage 2 breast cancer shifts the known time limits of a cancer survivor. This exceeded the 10 years period of breast cancer after which cure is generally considered with little or no risk of distant metastasis.<sup>12</sup> Also the median time to spine metastasis following breast cancer is about 42 months with the longest reported interval of 97 months.<sup>4</sup>

Early micro metastasis to the lumbosacral spine with prolonged dormancy may account for the far too late spine metastasis. It is known that micro-metastasis of breast adenocarcinomas to bone can remain dormant for years if the environment for tumour proliferation and propagation is not favourable, until there is a favourable milieu to initiate tumour growth at a distant sites.<sup>11</sup> The length of the interval periods of dormancy is dependent on several factors, such as genetic, immunologic,

endocrine, nutritional and local factors of the sites of micro metastasis. These factors usually determine the duration of time interval between occurrence of primary breast cancer and distant metastasis to spine, and this is said to usually have significant bearing on patients' outcome.<sup>11,13</sup> These factors with improved cancer regimens may be responsible for the uncommonly long disease-free survival evident in this case.

Literatures have shown that bone is the most common site of distant metastasis from breast cancer and this is followed by the lung, brain, and liver in decreasing frequencies.<sup>2,3,5</sup> The frequency of breast cancer metastasis to different sites is affected by the histological subtypes of breast cancer, for example, the risks of spine metastasis from breast cancer is seen more in luminal-A (ER or PR expression positivity and low Her-2 neu expression) and luminal-Her-2 neu (ER or PR positive and HER2 positive) histological subtypes.<sup>6,7</sup> Indeed, ER, PgR and Her-2 neu were all negative (triple negative) in this case, which are not considered to be high risk indicators for developing spine metastasis. This may account for the late spine metastasis.

More than 50% of spine metastases from breast cancer cases demonstrate multiple spine lesions, the thoracic and thoracolumbar spine regions are the common metastatic sites.<sup>8-10</sup> However, the occurrence of spine metastasis, without local recurrence or recurrence at any other site, is not extremely rare.<sup>11</sup> Considering these points, this appears to be a unique case of spine metastasis from breast cancer due to its lower lumbar and sacral locations, and absence of other systemic recurrence.

This case shows the possibility of a rather late spine metastasis in breast cancer survivors more than a decade of disease-free survival.

## CONCLUSION

Spinal micrometastasis in breast cancer survivors can be reactivated after 12 years of dormancy in stage II breast cancer to cause metastatic spine disease. This may extend the post for long-term survivors currently pegged at 10 years of disease-free survival.

*Funding: No funding sources*

*Conflict of interest: None declared*

*Ethical approval: Not required*

## REFERENCES

1. Esteva FJ, Valero V, Pusztai L, Michaud BL, Buzdar AU, Hortobagyi GN. Chemotherapy of metastatic breast cancer: what to expect in 2001 and beyond. *Oncologist*. 2001;6(2):133-46.
2. Ju DG, Yurter A, Gokaslan ZL, Sciubba DM. Diagnosis and surgical management of breast cancer metastatic to the spine. *World J Clin Oncol*. 2014;5(3):263-71.
3. Briasoulis E, Karavasilis V, Kostadima L, Ignatiadis M, Fountzilas G, Pavlidis N. Metastatic breast carcinoma confined to bone. *Cancer*. 2004;101(7):1524-8.
4. Hill ME, Richards MA, Gregory WM, Smith P, Rubens RD. Spinal cord compression in breast cancer: a review of 70 cases. *Br J Cancer*. 1993;68(5):969-73.
5. Manders K, Franse VDP, Creemers LVGJ, Vreugdenhil G, Sangen VD, Nieuwenhuijzen MJGA. Clinical management of women with metastatic breast cancer: a descriptive study according to age group. *BMC Cancer*. 2006;6:176.
6. Park HS, Kim S, Kim K, Yoo H, Chae BJ, Bae JS, et al. Pattern of distant recurrence according to the molecular subtypes in Korean women with breast cancer. *World J Surg Oncol*. 2012;10:4.
7. Yamada SM, Tomita Y, Shibui S, Kurokawa T, Baba Y. A case of breast cancer brain metastasis with a 16 years' time interval without evidence of cancer recurrence. *J Breast Cancer*. 2017;20(2):212-6.
8. Togawa D, Lewandrowsky KU. The pathophysiology of spinal metastases. In: McLain RF, editor. *Cancer in the Spine*. *Curr Clin Oncol*. 2006: 17-23.
9. Henry JL. *Tumors and tumorous conditions of the bones and joints*. Philadelphia. Pa Lea Febiger. 1958;629:701.
10. Brihaye J, Ectors P, Lemort M, Houtte VP. The management of spinal epidural metastases. *Adv Tech Stand Neurosurg*. 1988;16:121-76.
11. Maccauro G, Spinelli MS, Mauro S, Perisano C, Graci C, Rosa MA. Physiopathology of spine metastasis. *Int J Surg Oncol*. 2011;2011:107969.
12. Kurtz MJ, Amalric R, Delouche G, Pierouin B, Roth J, Spitalier JM. The second ten years: Long-term risks of breast conservation in early breast cancer. *Int J Radiat Oncol Biol Phys*. 1987;13(9):1327-32.
13. Braun S, Vogl FD, Naume B, Janni W, Osborne MP, Coombes RC, et al. A pooled analysis of bone marrow micro metastasis in breast cancer. *N Engl J Med*. 2005;353(8):793-802.

**Cite this article as:** Okwunodulu O, Inojie MO, Campbell FC, Ndubuisi CA, Ohaegbulam SC. Lumbar spine metastasis in a breast cancer survivor after twelve years of disease-free survival. *Int Surg J* 2020;7:2396-8.