

## Case Report

# Achondroplasia: a case report and the review of the basics

Sujan Narayan Agrawal\*

Department of Surgery, SBRKM Government Medical College, Jagdalpur (Bastar), Chhattisgarh, India

**Received:** 22 April 2020

**Revised:** 02 June 2020

**Accepted:** 03 June 2020

### \*Correspondence:

Dr. Sujan Narayan Agrawal,

E-mail: [drsujanagrawal@gmail.com](mailto:drsujanagrawal@gmail.com)

**Copyright:** © the author(s), publisher and licensee Medip Academy. This is an open-access article distributed under the terms of the Creative Commons Attribution Non-Commercial License, which permits unrestricted non-commercial use, distribution, and reproduction in any medium, provided the original work is properly cited.

## ABSTRACT

The achondroplasia is a variant of short-limbed dwarfism. The word achondroplasia literally means without cartilage formation. However, in achondroplasia the problem is not in formation of cartilage but, in its conversion to bone (i.e. ossification). This deficient ossification is particularly seen in the long bones of arm and leg. The characteristic external appearance of people born with achondroplasia is short stature. The average height of an adult male with achondroplasia is 131 centimetres (4 feet, 4 inches), and the average height for adult females is 124 centimetres (4 feet, 1 inch). The trunk is of average size but the leg and upper arm is of short length. It is because the femur and humerus are relatively shorter in length. The range of movement at elbow is limited. The head is enlarged called macrocephaly and is with a prominent forehead. People with Achondroplasia are generally of normal intelligence. They have bowed legs and abnormal curvature of spine giving rise to lordosis or kyphosis. They may develop spinal stenosis, which is associated with pain, tingling and weakness in leg. This may cause difficulty in walking. The other health problems associated with Achondroplasia are episodes of apnoea, obesity and recurrent ear infection. The purpose of this study is to evaluate the cardinal phenotypic features in patient of Achondroplasia. It is also to assess the body physique, anthropometric measurements and to study the typical radiological signs in such patients as the main tool of diagnosis.

**Keywords:** Achondroplasia, Fibroblast growth factor receptor 3, Rhizomelia, Skeletal dysplasia

## INTRODUCTION

The achondroplasia is a type of bony dysplasia, which results in a short stature. A short stature is defined as the height that is less than the third percentile, for the chronological age of the patient. A clinician can easily diagnose the skeletal dysplasia by history and physical examination of the child. The presenting complaint of the parents is short stature of their child, which is established easily by physical examination. In achondroplasia the short stature is most prominent in the proximal segment of the limb i.e. in femur or humerus. This condition is called Rhizomelia. The achondroplasia is an example of the short limb dwarfism. The radiological examination further confirms the diagnosis. The word achondroplasia

literally means ‘without cartilage formation’. However, it is a misnomer, since in achondroplasia, the problem is not in formation of cartilage but it is, in its ossification. In achondroplasia the cartilage is not converted to bone (ossification), particularly in the long bones of arm and legs. This is the most common type of short limb dwarfism and it occurs in one in 26,000 to 28,000 live births.<sup>1</sup>

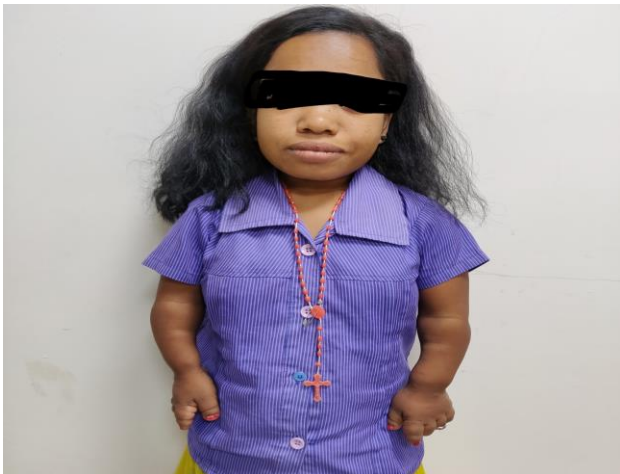The short stature is further divided into two main patterns i.e. proportionate and disproportionate. Achondroplasia is the most common cause of disproportionate short stature. Affected individuals have shortening of femur and humerus (rhizomelia). They have macrocephaly, frontal bossing and midface retrusion. The developmental motor

milestones are delayed and are accompanied by hypotonia. The cranio-cervical junction compression increases the risk of death in infancy. The additional complications include obstructive sleep apnoea, middle ear infection, kyphosis or lordosis and spinal stenosis.

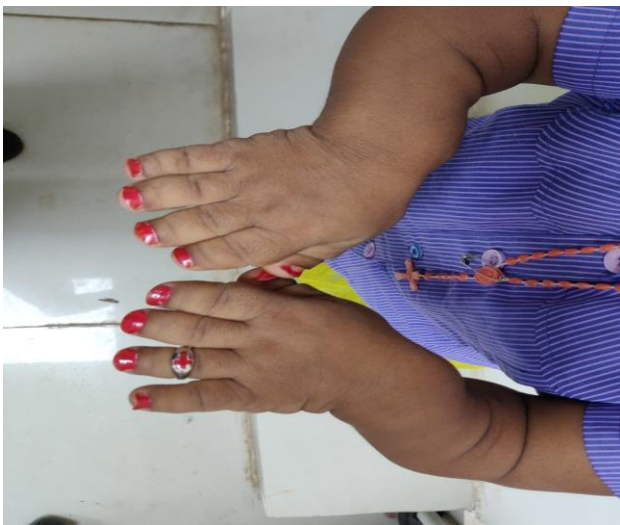## CASE REPORT

A patient named X was admitted in our hospital for pain in joints and vague illness. She is the third child of her parents. The mother was of 34 years of age, when she was born. There are three siblings in the family, she is the youngest. At the time of presentation, her age is 16 years. Parents and other children are of normal height.

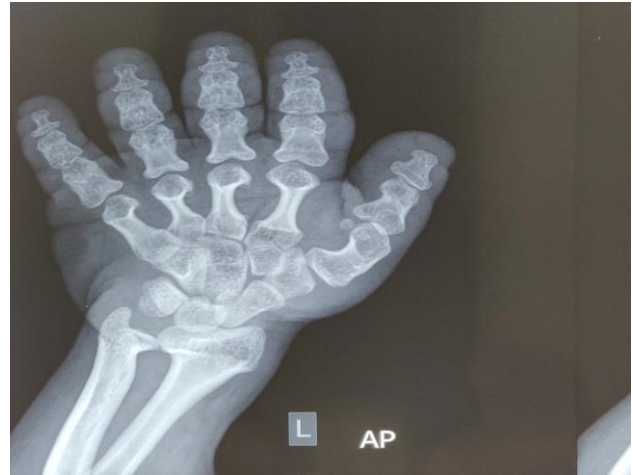On physical examination her height is 124 CMs. There was frontal bossing with depressed bridge of nose. The upper limb shortening is noted as compare to lower limb. The extension at elbow is restricted. Fingers are typically short and all are of same length. The middle finger was also of the same length as others. A provisional diagnosis of achondroplasia was made (Figure 1).



**Figure 1: Typical features of achondroplasia.**



**Figure 2: The spatulated, trident hand.**



**Figure 3: X-ray hand in achondroplasia.**

## DISCUSSION

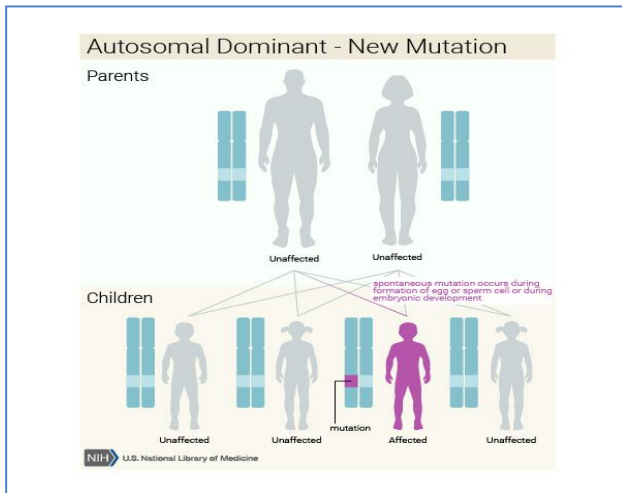
### *The genetics*

Fibroblast growth factor receptor 3 (FGFR-3), is a membrane-spanning tyrosine kinase receptor with an extracellular ligand-binding domain consisting of three immunoglobulin (Ig) subdomains, a transmembrane domain, and a split intracellular tyrosine kinase domain.<sup>2</sup> FGFR-3 is activated by various fibroblast growth factors (FGFs).<sup>3</sup> Binding appear to result in receptor dimerization, transactivation of tyrosine kinase, and transphosphorylation of tyrosine residues.<sup>4</sup> These modifications result in activation of a number of downstream signalling pathways, including signal transducer and activator of transcription (STAT), mitogen-activated protein kinase (MAPK) and a number of others.<sup>4-6</sup> Overall, these secondary pathways cause slowing of proliferation and differentiation of chondrocyte.<sup>7</sup> The G380R mutation in FGFR3 transmembrane domain is known as the genetic cause for achondroplasia.<sup>8</sup> Achondroplasia is inherited in an autosomal dominant pattern, which means one copy of the altered gene in each cell is sufficient to cause the disorder. This genetic disorder interferes with the maturation of the cartilage growth plate of long bones.<sup>9,10</sup> The phenotype is characterized by short stature, narrowing of the lumbar spinal canal, accentuated bowing of the middle and lower part of the back, and trident-shaped hands.<sup>11</sup> The affected individuals often exhibit other skeletal as well as neurological complications.

### *Inheritance pattern*

Achondroplasia is inherited in an autosomal dominant pattern, which means one copy of the altered gene in each cell is sufficient to cause the disorder. About 80 percent of people with Achondroplasia have average-size parents; these cases result from new mutations in the FGFR3 gene. Individuals who inherit two altered copies of this gene typically have a severe form of Achondroplasia that causes extreme shortening of the bones and an

underdeveloped rib cage. These individuals are usually stillborn or die shortly after birth from respiratory failure.



**Figure 4: Pattern of autosomal dominance.**

### The physical characters

The children born with achondroplasia have rhizomelic shortening of arms, hydrocephalic head, narrow chest and short fingers. The typical physical features are as follows.

#### Short stature

The average adult height for men with Achondroplasia is  $131 \pm 5.6$  cms. For women it is around  $124 \pm 5.9$  cms. Obesity is a major problem with this condition.<sup>12</sup> Mild to moderate hypotonia is typical.

**Table 1: The skeletal survey.**

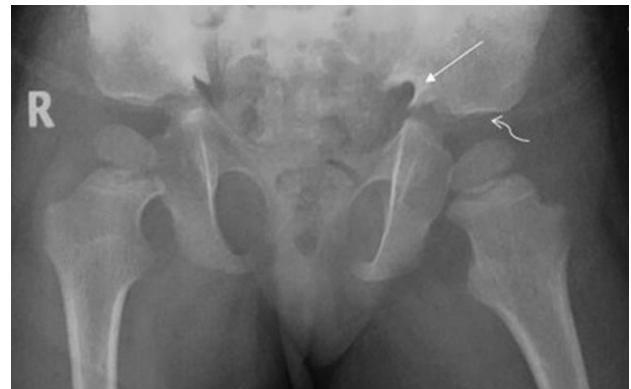The skeletal survey	Findings in Achondroplasia
<b>Facial phenotype</b>	Frontal bossing mid face hypoplasia, depressed nasal bridge short neck
<b>Trunk</b>	Lumbar kyphosis exaggerated lumbar lordosis protuberant abdomen
<b>Upper limb</b>	Rhizomelic shortening, limited elbow extension generalized joint laxity brachydactyly and trident hand configuration (Figure 2)
<b>Lower limb</b>	Bowing of legs or genu varum multiple skin creases over the limbs (Michelin tire creases)
<b>Miscellaneous</b>	Upper respiratory tract infection, snoring, sleep apnoea otitis media muscular hypotonia delayed motor developmental milestones

The motor development is also slow. There is small joint hyper motility and with short fingers it may interfere with

self-feeding.<sup>13</sup> Most children with achondroplasia are macro cephalic.<sup>14</sup> There are midface retrusion and depressed bridge of nose. The head is large (hydrocephalic) may be due to foramen magnum stenosis.<sup>15</sup> Middle ear infections is a frequent problem.<sup>16</sup> It contributes significantly to the hearing loss. In fact, about 40% of individuals with achondroplasia have functional hearing loss. With the hearing loss the ability to learn is also hampered.

### The skeletal issues

There is symmetrical shortening of all long bones, with proximal portions being more affected and lower limb involvement being more than the upper limb (rhizomelia). There's relative flaring and splaying of metaphyses with normal epiphyses. There is increased gap between 2<sup>nd</sup> and 3<sup>rd</sup> digit of hand and inability to approximate them in extension leading to appearance of trident hand (Figure 1-4).<sup>17</sup>



**Figure 4: Pelvis radiograph in achondroplasia, shows, square shape of the iliac bone, horizontal acetabular roof (squiggly arrow), and rhizomelic shortening of the femur.**

Also note the trident sign in achondroplasia. The three-pronged pear shape of the sciatic notch is well visualized in this radiograph (straight arrow).<sup>18</sup>

### Pelvis

There is trident pelvis/tombstone shape of iliac bone. Small square shaped iliac wings akin to tombstone, with horizontal acetabular roof and telephone handle shaped femur. The spur at the medial and lateral acetabular margin and in the centre of the acetabulum gives rise to trident sign, due to its resemblance of a three-pronged spear. The pelvic inlet is described as Champagne glass shaped pelvic inlet, because of the flattening of iliac blades with increased acetabular angles and small Sacro sciatic notch (Figure 4).

### Lower limb

Angular deformity of the lower limb usually develops in the child with achondroplasia. Genu-varum and tibia vara are more common than varus deformities.<sup>19</sup> Relative



overgrowth of fibula as compare to tibia has been proposed as the cause of varus deformity.

### Thoracolumbar kyphosis

It is seen in slightly older babies when they start sitting. It has been proposed that this may be due to the large head, reduced muscular tone, lack of trunk control and tendency for hip flexion contributes towards kyphotic deformity. There is spinal stenosis due to abnormal growth of vertebral pedicles. There is interpedicular narrowing and thickening of pedicles, hypertrophy of facets and enlargement of laminae. These abnormalities cause spinal stenosis which becomes symptomatic in 3<sup>rd</sup> decade of life or even earlier.<sup>20</sup>

### CONCLUSION

Traditionally, the term achondroplasia was initially used to describe all individuals with short-limbed dwarfing disorders. Over the past 50 years diagnostic criteria have been available to distinguish true achondroplasia from other short limb disorders or dwarfism. A condition that may be confused with achondroplasia includes hypochondroplasia, thanatophoric dysplasia, severe achondroplasia with developmental delay and acanthosis Nigricans (SADDAN) syndrome, cartilage-hair hypoplasia, pseudoachondroplasia, etc. A good clinical examination, anthropometric evaluation and radiological findings are usually sufficient to establish the diagnosis of achondroplasia. Achondroplasia is inherited in an autosomal dominant manner. Approximately 80% of individuals with achondroplasia have parents of average stature and have achondroplasia as a result of a denovo FGFR3 pathogenic variant. Denovo pathogenic variants are associated with advanced paternal age, often defined as older than age 35 years.<sup>21</sup> The denovo pathogenic variants causing achondroplasia are exclusively inherited from the father.<sup>22</sup> The remaining 20% of individuals with achondroplasia have at least one affected parent. In the families, that have an apparent denovo pathogenic variant, they should undergo genetic testing and counselling. The optimal time for determination of genetic risk and discussion of the availability of prenatal testing is before pregnancy. It is appropriate to offer genetic counselling (including discussion of potential risks to offspring and reproductive options) to young adults who are affected. Genetic counselling is also recommended when both parents have a skeletal dysplasia.

*Funding: No funding sources*

*Conflict of interest: None declared*

*Ethical approval: Not required*

### REFERENCES

1. Waller DK, Correa A, Vo TM, Wang Y, Hobbs C, Langlois PH, et al. The population-based prevalence of Achondroplasia and Thanatophoric dysplasia in

- selected regions of the US. Am J Med Genet A. 2008;146A:2385-9.
2. Laederich MB, Horton WA. Achondroplasia: pathogenesis and implications for future treatment. Curr Opin Pediatr. 2010;22:516-23.
3. Ornitz DM. FGF signalling in the developing endochondral skeleton. Cytokine Growth Factor Rev. 2005;16:205-13.
4. Narayana J, Horton WA. FGFR3 biology and skeletal disease. Connect Tissue Res. 2015;56:427-33.
5. Deng C, Boris WA, Zhou F, Kuo A, Leder P. Fibroblast growth factor receptor 3 is a negative regulator of bone growth. Cell. 1996;84:911-21.
6. Eswarakumar VP, Lax I, Schlessinger J. Cellular signalling by fibroblast growth factor receptors. Cytokine Growth Factor Rev. 2005;16:139-49.
7. Klag KA, Horton WA. Advances in treatment of Achondroplasia and osteoarthritis. Hum Mol Genet. 2016;25(1):2-8.
8. Shiang R, Thompson LM, Zhu YZ, Church DM, Fielder TJ, Bocian M, et al. Mutations in the Transmembrane Domain of FGFR3 Cause the Most Common Genetic Form of Dwarfism, Achondroplasia. Cell. 1994;78:335-42.
9. Horton WA, Hall JG, Hecht JT. Achondroplasia. Lancet. 2007;370:162-72.
10. Ponseti IV. The Ponseti Technique for Correction of Congenital Clubfoot. J Bone Joint Surg Am. 1970;52:701-16.
11. Vajo Z, Francomano CA, Wilkin DJ. The Molecular and Genetic Basis of Fibroblast Growth Factor Receptor 3 Disorders: The Achondroplasia Family of Skeletal Dysplasias, Muenke Craniosynostosis, and Crouzon Syndrome with Acanthosis Nigricans. Endocr Rev. 2000;21:23-39.
12. Hecht JT, Butler KJ, Cott CL. Long-term neurological sequelae in Achondroplasia. Eur J Pediatr. 1984;143:58-60.
13. Ireland PJ, Donaghey S, Gill MJ, Zankl A, Ware RS, Pacey V, et al. Development in children with Achondroplasia: a prospective clinical cohort study. Dev Med Child Neurol. 2012;54:532-7.
14. Horton WA, Rotter JJ, Rimoin DL, Scott CI, Hall JG. Standard growth curves for Achondroplasia. J Pediatr. 1978;93:435-8.
15. Etus V, Ceylan S. The role of endoscopic third ventriculostomy in the treatment of tri-ventricular hydrocephalus seen in children with achondroplasia. J Neurosurg. 2005;103:260-5.
16. Tunkel D, Alade Y, Kerbavez R, Smith B, Hardison RD, Fong HJ. Hearing loss in skeletal dysplasia patients. Am J Med Genet A. 2012;158A:1551-5.
17. Panda A, Gamanagatti S, Jana M, Gupta AK. Skeletal dysplasias: a radiographic approach and review of common non-lethal skeletal dysplasias. World J Radiol. 2014;6(10):808-25.
18. Jana M, Nair N, Gupta AK, Kabra M, Gupta N. Pelvic radiograph in skeletal dysplasias: an approach. Indian J Radiol Imaging. 2017;27:187-99.

19. Basse TT, GS. Lower extremity abnormalities in dwarfing conditions. *Instr Course Lect.* 1990;30:389.
20. Hamamci H, Hawran S, Sorensen BF. Achondroplasia and spinal cord lesion: three case report. *Paraplegia.* 1993;31:375.
21. Stoll C, Roth MP, Bigel P. A re-examination on parental age effect on the occurrence of new mutations for Achondroplasia. *Prog Clin Biol Res.* 1982;104:419-26.
22. Wilkin DJ, Szabo JK, Cameron R, Henderson S, Bellus GA, Mack ML, et al. Mutations in fibroblast

growth-factor receptor 3 in sporadic cases of Achondroplasia occur exclusively on the paternally derived chromosome. *Am J Hum Genet.* 1998;63:711-6.

**Cite this article as:** Agrawal SN. Achondroplasia: a case report and the review of the basics. *Int Surg J* 2020;7:2420-4.