

Original Research Article

Functional and aesthetic outcomes of first dorsal metacarpal artery flap for thumb reconstruction: a prospective study

Sujana Ravada, Surya Rao Rao Venkata Mahipathy*, Alagar Raja Durairaj, Narayanamurthy Sundaramurthy, Anand Prasath Jayachandiran

Department of Plastic and Reconstructive Surgery, Saveetha Medical College and Hospital, Kanchipuram, Tamilnadu, India

Received: 20 April 2020

Revised: 19 May 2020

Accepted: 20 May 2020

*Correspondence:

Dr. Surya Rao Rao Venkata Mahipathy,
E-mail: surya_3@hotmail.com

Copyright: © the author(s), publisher and licensee Medip Academy. This is an open-access article distributed under the terms of the Creative Commons Attribution Non-Commercial License, which permits unrestricted non-commercial use, distribution, and reproduction in any medium, provided the original work is properly cited.

ABSTRACT

Background: Reconstruction of soft tissue defects of the thumb, with exposure of tendon, joint or bone, has been a challenging problem. Surgical options include local, regional or free flaps. Here, we have evaluated the functional and aesthetic outcomes of first dorsal metacarpal artery (FDMA) island flap in reconstruction of various soft tissue defects of the thumb.

Methods: Between January 2018 and January 2019, twenty patients with post-traumatic and post-infective thumb defects underwent FDMA flaps. Sensory function was evaluated with static 2 point discrimination and mobility of the thumb was tested by the Kapandji score. The aesthetic outcome was also assessed.

Results: The mean defect size was 39.9×19.95 mm. Eighteen flaps survived completely and one had distal flap necrosis and one had superficial epidermal peeling which was treated conservatively. The mean static two-point discrimination was 9.3 mm. Cortical reorientation was complete in 45%. The average Kapandji score was 7.9. The aesthetic outcome was excellent in ten, good in eight and poor in two subjects. After a mean follow up period of 11.85 months, most patients regained all functions of the thumb and index finger and were pleased with the cosmetic appearance of the flap and donor site.

Conclusions: FDMA flap offers a good quality skin cover for small to moderate sized thumb defects. It is a reliable and versatile flap which is sensate and pliable. It gives excellent functional and aesthetic outcomes with minimal or no donor site morbidity.

Keywords: Thumb defects, Reconstruction, First dorsal metacarpal artery

INTRODUCTION

The thumb is the most important structure in human hand functions.¹ Hence, injury to the thumb have a higher and more significant impact on the normal daily life activities than of the injury to other digits.² Reconstruction of soft tissue defects of the thumb, with exposure of the underlying tendon, bone or joint, is challenging to hand surgeons due to the paucity of local soft tissue and the need for good quality and sensate skin coverage to

preserve the thumb function which is of utmost importance.³ Generally, these defects can be resurfaced by Moberg advancement flap, cross-finger flap, little's neurovascular island flap, first dorsal metacarpal artery (FDMA) flap, reversed radial forearm flap, distant flaps and free flaps from the first and second toes and web space of the foot. The FDMA flap was first reported by Hilgenfeldt in 1961 and Holveich in 1963 as a peninsular flap with preservation of the skin over the pedicle.⁴ An island flap was first described by Foucher

and Braun in 1979, who mentioned that a sensate skin island flap could be harvested from the dorsum of the index finger, based on the first dorsal metacarpal artery and by incorporating a sensory branch of the superficial radial nerve.⁵ The first dorsal metacarpal artery, is a constant vessel, with very little variability originating from the radial artery in the first intermetacarpal space just proximal to the point where it dips between both heads of the first dorsal interosseous muscle and distal to extensor pollicis longus tendon. The FDMA runs supra-fascially over the fascial layer of the first dorsal interosseous muscle in 57% of cases, while it takes a subfascial course in 43% of patients, following which it divides into ulnar branch to the index finger, intermediate branch to the first web space and radial branch to the thumb.⁶ The ulnar branch runs distally between the shaft of the second metacarpal bone and the ulnar head of the first dorsal interosseous muscle until reaching the metacarpophalangeal joint, where it forms a functionally important anastomoses with the branches of the second dorsal and palmar metacarpal arteries, then it ramifies into a number of small vessels that supply the dorsal aspect of the index proximal phalanx through a rich subdermal plexus. The FDMA has two venae comitantes that are in connection with large cutaneous superficial veins in the first intermetacarpal space representing the venous drainage of the flap.⁷ Being a sensate flap with a constant vascular anatomy, the FDMA flap has been successfully used for reconstruction of thumb soft tissue defects. This study was done to evaluate the functional and aesthetic outcomes of the FDMA island flap in reconstruction of soft tissue defects of the thumb.

METHODS

This prospective study was performed, between January 2018 and January 2019, in the Department of Plastic and Reconstructive Surgery, Saveetha Medical College and Hospital, on twenty patients with complex post-traumatic and post-infective soft tissue thumb defects (6 dorsal and 12 volar) that were covered with first dorsal metacarpal artery island flaps. Informed consent was taken from all patients after detailed description of the procedure. Approval of the Institutional Ethical Committee was obtained before commencing the study. The flap was marked over the dorsal skin of the proximal phalanx of the index finger. The flap width was outlined so that it didn't go beyond the ulnar and radial mid-axial lines of the proximal phalanx and its margins distally and proximally were designed to maintain the dorsal skin of the proximal interphalangeal (PIP) joint and the metacarpophalangeal (MCP) joint respectively. Between the bases of the first and second metacarpal bones, the radial artery pulsation was felt. The FDMA course was marked extending radial and parallel to the second metacarpal bone from the radial pulsation. All patients were operated under regional anaesthesia with the aid of pneumatic tourniquet control 250-300mmHg and loupe magnification. After debridement and

preparation of the thumb defect, the flap was outlined according to the size of the defect (Figure 1a). A lazy-S incision was done between the radial border of the MCP joint and the tip of the triangular first web space (the pivot point) (Figure 1b). Thereafter, subdermal dissection was done to expose the pedicle, with great care to avoid injury of the large superficial subcutaneous veins. Elevation of the flap initiated from distal to proximal side and from ulnar to radial side preserving the paratenon to ensure the free gliding of the extensor tendon and for the skin graft take. The pedicle was then dissected towards the pivot point. To ensure safe dissection, the extensor hood at the radial aspect of the MCP joint, the periosteum of the radial shaft of the second metacarpal bone and the fascia of the ulnar head of the first dorsal interosseous muscle must be included within the pedicle along with the sensory branch of the radial nerve and the dorsal veins. After flap harvesting, the tourniquet was released to ensure its vascularity (Figure 1c).

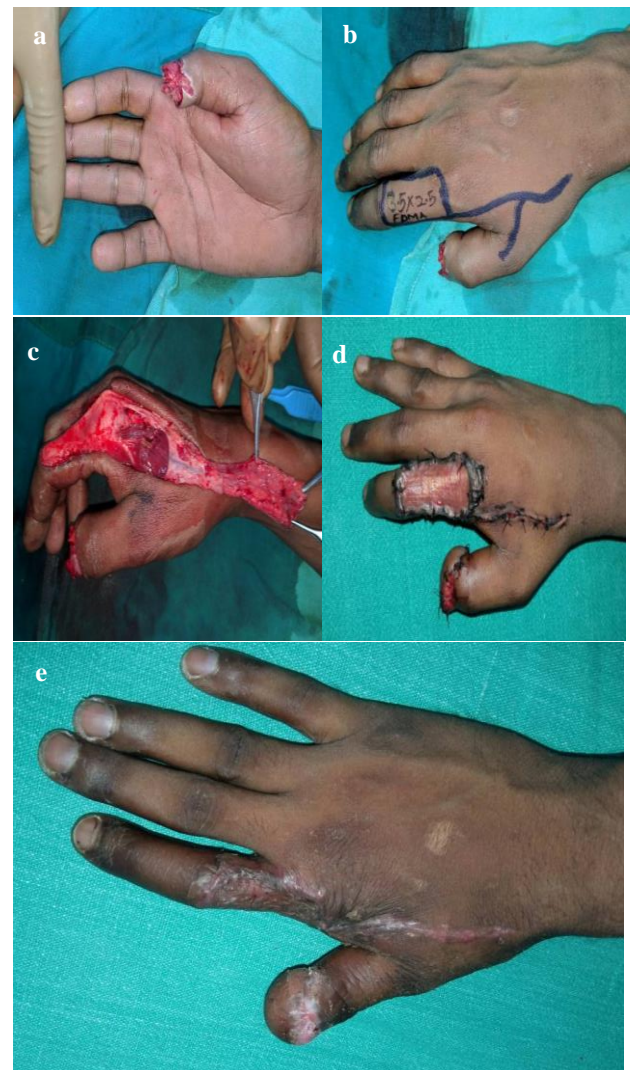


Figure 1: (a) The defect, (b) flap and incision markings, (c) flap harvest, (d) flap and donor area at first look on 5th post-operative day and (e) well settled flap and SSG after 1 month post-operative period.

The flap was then transferred through a subcutaneous tunnel into the defect of the thumb by gentle traction. The tunnel was tight in five 25% patients and had to be laid open then sutured primarily after flap in setting. The donor sites were grafted by split skin grafts harvested from medial aspect of the same arm in all patients (Figure 1d). After suturing and graft dressing were complete, a protective splint was applied. The hand and the fingers were immobilized in neutral position with dorsal splint for 10 days to ensure proper graft take. All patients were discharged after graft dressing on the 5th post-operative day. Sutures were removed on 10-14th post-operative day followed by physiotherapy for 6 weeks in all patients (Figure 1e). The patients were followed up in the post-operative every month for 3 months, then every 3 months thereafter. All patients were evaluated for features of early post-operative complications like flap necrosis, hematoma, infection, wound dehiscence and graft loss. Sensory function was evaluated with static 2 points discrimination (S2-PD) testing. Cortical reorientation was tested by asking the patient whether the needle prick stimulation coming from the thumb or the index. The mobility of the first ray was tested by thumb opposition using the Kapandji score.⁸ The esthetic outcome was objectively assessed by two different plastic surgeons and was graded as poor, good and excellent also taking into account the patient's satisfaction. The aesthetic appearance of the flap and donor site was done and noted.

RESULTS

In one year, twenty first dorsal metacarpal artery island flaps were used for reconstruction of complex post-traumatic and post-infective soft tissue thumb defects (Figure 2a). There were 18 males and 2 females with age ranging from 14 to 45 years with a mean age of 27.8 years (Figure 2b). Sixteen patients were operated as emergency with immediate reconstruction, while four had delayed surgery due to late presentation (Figure 2c). The dominant hand was affected in eighteen 90% patients (Figure 2d). There were 14 volar and 6 dorsal defects, with 13 patients with right sided and 7 patients with left sided defects Figure 3 (a and b). The flap sizes ranged from 23×17 mm to 38×21 mm (mean 39.9×19.95 mm). The mean follow-up period was 11.85 months (range 9-15 months). The static two points discrimination (s2-PD) ranged from 6 to 13 mm; with an average of 9.3 mm. Cortical reorientation was complete in nine 45% patients (Figure 4a). The average Kapandji score was 7.9 (range: 6-9). The aesthetic outcome of the donor and recipient areas was excellent in twelve (50%) patients, good in eight 40% patients and poor in two 10% case (Figure 4b). Most patients regained all functions of the thumb and index finger and were pleased with the cosmetic appearance of the flap and donor site. Eighteen flaps survived completely, one had distal flap necrosis and one had superficial epidermal peeling that were treated conservatively and healed by secondary intention (Figure 4c). All the recipient and donor areas were healed

uneventfully. Examples of a few cases are shown (Figure 5-9).

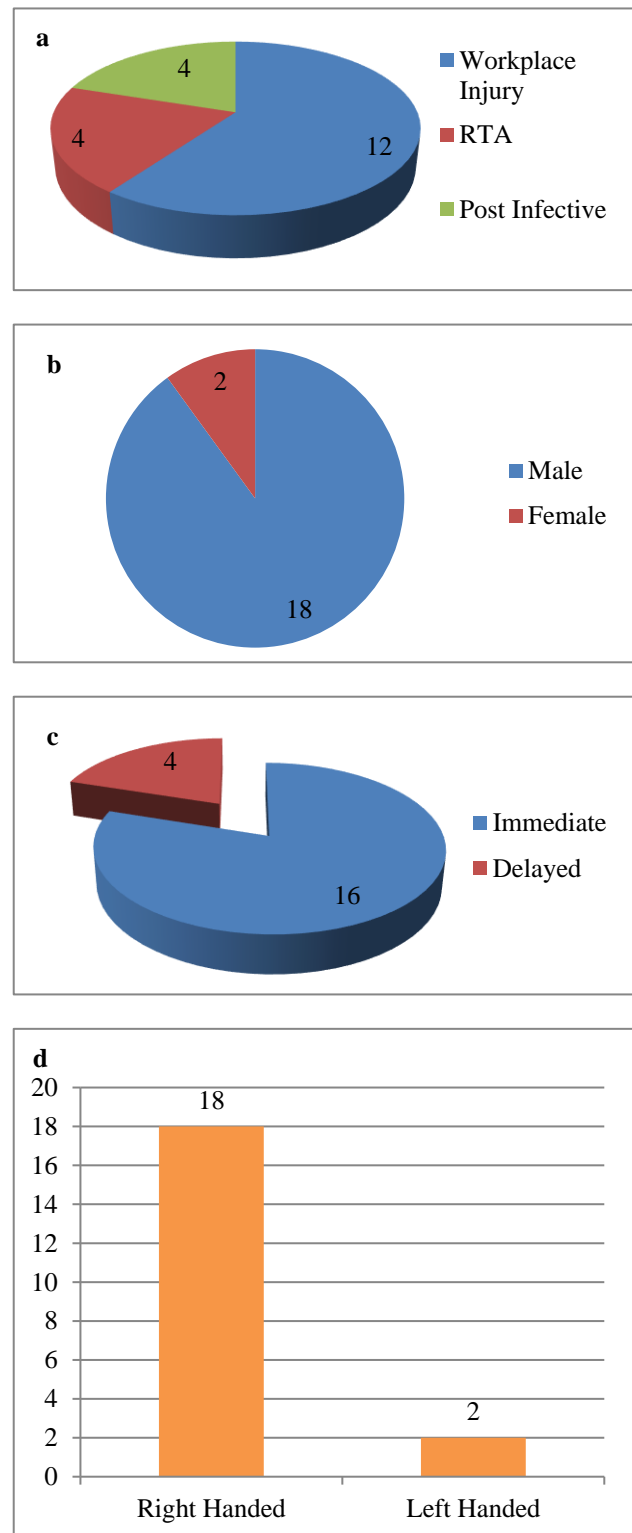


Figure 2: (a) The cause of injury in our group of patients, (b) pie diagram depicting the sex ratio among the cases, (c) pie chart showing the type of reconstruction and (d) bar diagram showing the hand dominance in our patient group.

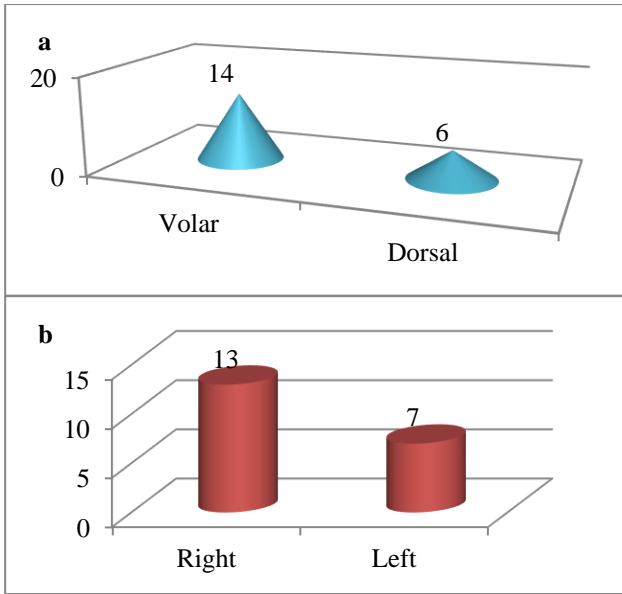


Figure 3: (a) Cone diagram showing the location of defect and (b) bar chart depicting the side of the defect.

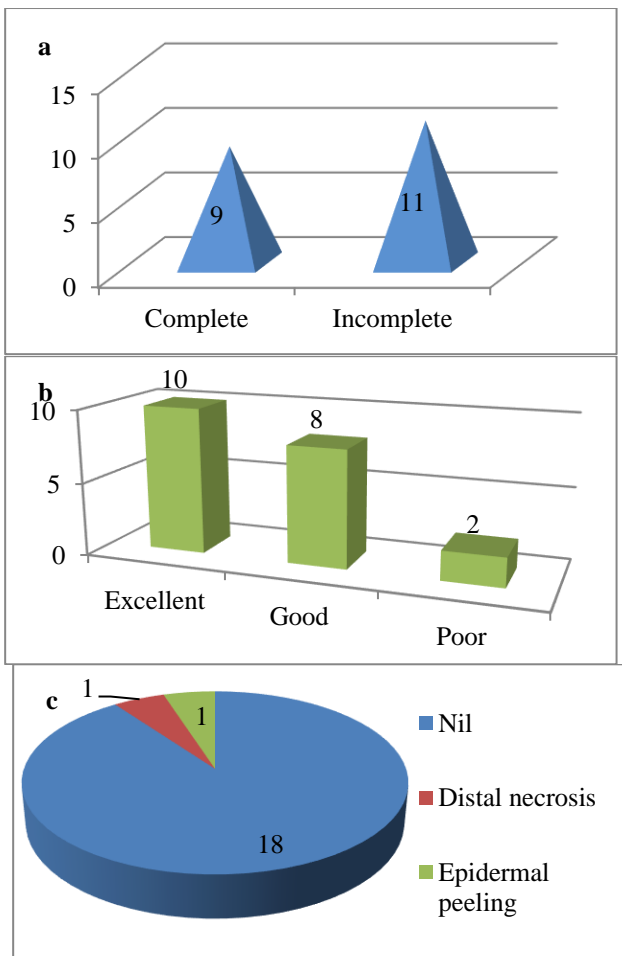


Figure 4: (a) Pyramidal cone showing the cortical re-orientation of flaps, (b) depicting the final aesthetic outcome and (c) the complication in our patients.

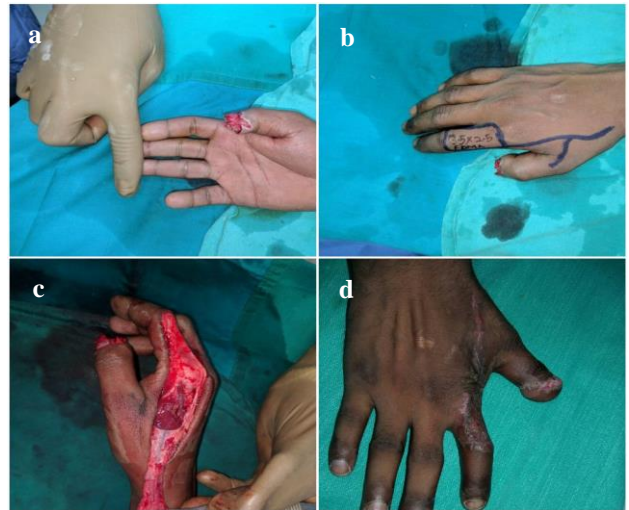


Figure 5 (a-d): The defect, flap and incision markings, flap elevation and final post-operative result of patient 1.

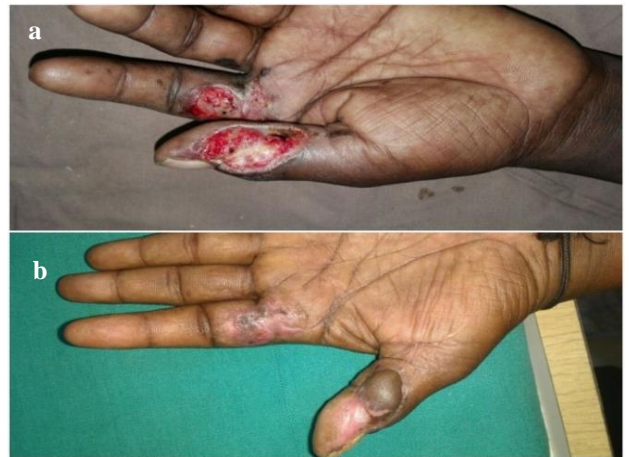

Figure 6 (a and b): Pre- and post-operative photos of patient 2.

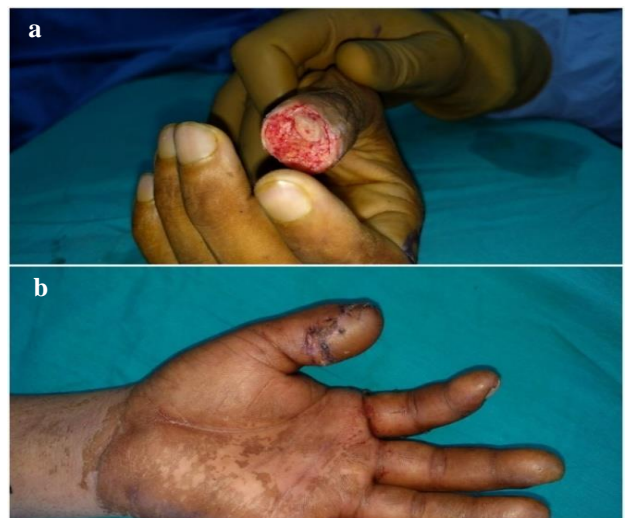

Figure 7 (a and b): Pre- and post-operative photos of patient 3.

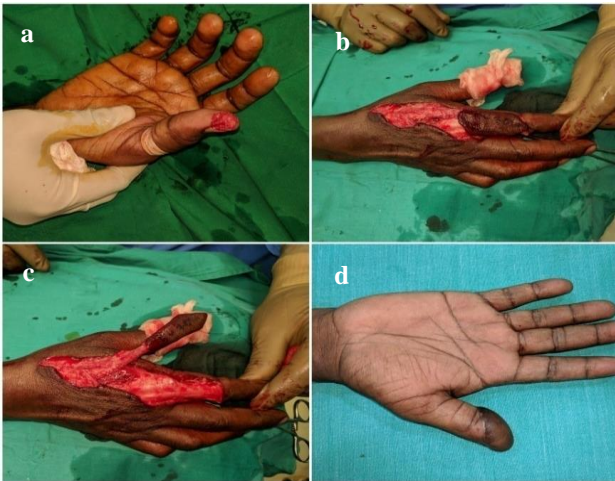


Figure 8 (a-d): The defect, flap harvest and late post-operative result in patient 4.

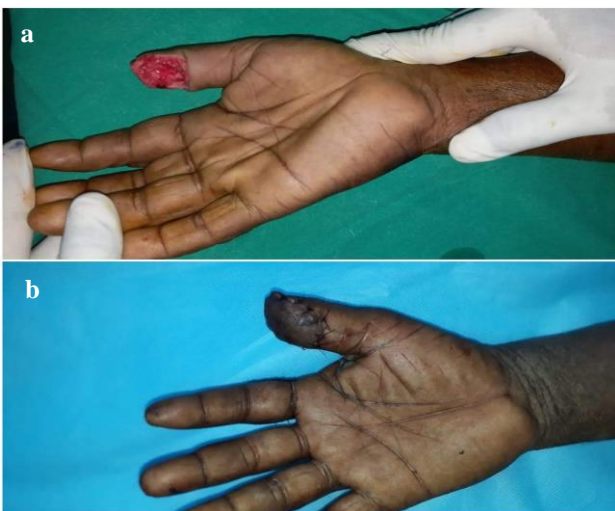

Figure 9 (a and b): Pre- and post-operative pictures of patient 5.

DISCUSSION

Complex soft tissue defects of the thumb, with exposure of tendons, joints or bones have always been a challenging reconstructive task. Local, regional and free flaps have been used to resurface such defects. Nevertheless, each therapeutic modality has its own advantages and limitations. Local flaps offer superior esthetic results due to replacement 'like with like' tissue.⁹ However, limited arc of rotation and limited amount of soft tissue availability are major drawbacks. The Moberg advancement flap causes risk of thumb IP flexion contracture, the cross-finger flap is a staged procedure with the risk of finger joints stiffness and first web contracture. Littler's neurovascular island flap has the disadvantages of cold intolerance, poor cortical reorientation and loss of two-point discrimination.¹⁰ The reversed radial forearm flap has significant donor site morbidity and sacrifice of one of the two major vascular axes of the forearm are the main limitations. Although

distant flaps less commonly used, they remain a useful tool for complex soft tissue defects of the thumb but are limited by the need for additional procedures for separation and debulking to optimize hand functions.¹¹ Microvascular transfer of free flaps from the foot was described to remedy such problem. However, the needs for microsurgical experience and facilities, long operative time and moderate to poor sensory outcome are major handicaps. With the Hilgenfeldt technique, the skin remains intact towards the base of the flap. With the Holvech technique, the skin island over the pedicle is smaller and gives the flap the form of a tennis racquet or a flag.⁴ This avoids the excess of skin in the first commissure region. With the Foucher technique, there is no skin over the neurovascular pedicle.⁵ In this case, a subcutaneous tunnel is made along the ulnar aspect of the thumb from the snuffbox to the proximal margin of the pulp defect to transfer the flap into the defect by gentle traction. The donor site is grafted with a split-thickness skin graft. This study was aimed to evaluate the functional and aesthetic outcomes of the first dorsal metacarpal artery island flap in reconstruction of soft tissue defects of the thumb. The FDMA flap or Foucher's flap is an island sensory flap based on the first dorsal metacarpal artery and a branch of the superficial radial nerve. It was first described by Foucher and Braun in 1979 to cover thumb defects.⁵ It also known as "kite flap" as the flap is raised with its neurovascular pedicle that resembles the kite. We observed that the FDMA has a constant anatomy which is consistent with de Rezedo et al, who found that the first and second dorsal metacarpal arteries are anatomically constant and they are very reliable as a source of pedicle flaps without the need for pre-operative Doppler study.¹² In our study, the mean flap size was 39.9×19.95 mm and we had one distal flap necrosis and one superficial epidermal necrosis that were managed conservatively. In a similar study, Satish et al used 9 FDMA flaps to cover post-traumatic thumb defects and found that the mean flap size was 33.3×19.4 mm and only one flap had partial necrosis that healed without secondary procedure.¹³ They reported that the size limitation is a drawback of this flap that could not extend beyond the PIP distally. El-Khatib devised an extended version of the FDMA flap for reconstruction of combined palmar and dorsal thumb defects in five patients and observed complete survival of all flaps which could be attributed to presence of rich dermal-subdermal plexus, supplying the skin of the dorsal aspect of proximal and middle phalanges of the index finger, allowing harvesting the skin of the dorsal aspect of the middle phalanx as a random extension.¹⁴ In this study, we noticed that the mean value of static two-point discrimination (s2-PD) was 9.3 mm. Similarly, Ege et al used 21 Foucher's flaps for thumb reconstruction and had an average s2-PD of 10.8 mm.¹⁵ In another study, Chang et al observed that the mean s2-PD was 8.1 mm. The ability of the brain to recognize any stimulation of the flap site as from the thumb not from the index is called 'cortical reorientation'. In our series, we had complete cortical reorientation in nine 45% patients. The

incomplete reorientation in the remaining patients didn't interfere with their normal daily activities. We observed that the least period needed for reorientation was 11 months which was not consistent with other studies, who reported that a two-year period is needed for complete reorientation.^{16,17} Trankle et al studied the quality of sensation of innervated FDMA flaps in different age groups and found that there is no significant age-related differences in the surgical outcome of the FDMA flap.¹⁸ We observed that after a mean follow up period of 11.85 months, the average Kapandji score in our patients was 7.9. Similar to our study and findings, Muyltermans et al noticed that the average Kapandji score, after a mean follow up period of 15.4 months, was 7.43 and concluded that the FDMA flap is of choice in coverage of thumb defect at the proximal phalanx and proximal segment of the distal phalanx.¹⁶ Eski et al used 14 FDMA flaps to correct post-burn thumb deformities and observed that all deformities were corrected with satisfactory aesthetic outcome, functional recovery and minimal donor site morbidity.¹⁹ Ratcliffe et al used the FDMA flap to cover defects of the thumb in 5 patients and reported no morbidity related to the donor site.²⁰ Cil et al advocated that there was no donor site morbidity of FDMA flap in their study.²¹ Sherif described the use of 23 FDMA flaps for reconstruction of the first web space and coverage of thumb dorsal surface, thumb palmar surface and hand dorsal surface defects and reported complete flap survival and satisfactory functional and aesthetic outcomes.²² We can therefore conclude that the first dorsal metacarpal artery flap offers a sensate, pliable and versatile coverage for small to moderate sized defects of both dorsal and volar aspects of the thumb. Furthermore, it provides good functional and aesthetic outcomes with minimal donor site morbidity.

CONCLUSION

The FDMA flap has a constant anatomy and easy dissection. It has low donor site morbidity and shows good functional and aesthetic results. The FDMA flap is a first treatment of choice for defects of the proximal phalanx and proximal part of the distal phalanx of the thumb.

Funding: No funding sources

Conflict of interest: None declared

Ethical approval: The study was approved by the Institutional Ethics Committee

REFERENCES

1. Ray E, Sherman R, Stevanovic M. Immediate reconstruction of a non-replantable thumb amputation by great toe transfer. *Plast Reconstr Surg.* 2009;123:259-67.
2. Lai CH, Lai CS, Huang SH, Lin SD, Chang KP. Free medial plantar artery perforator flaps for resurfacing of thumb defects. *Ann Plast Surg.* 2010;65:535-40.
3. Prabhu M, Powar R, Sulhyan SR. FDMA flap: a versatile technique to reconstruct the thumb. *Int J Pharm Med Bio Sc.* 2013;2:8-14.
4. Holevich J. A new method of restoring sensibility to the thumb. *J Bone Joint Surg.* 1963;45:496-502.
5. Foucher G, Braun JB. A new island flap transfer from the dorsum of the index to the thumb. *Plast Reconstr Surg.* 1979;63:344-9.
6. Earley MJ. The arterial supply of the thumb, first web and index finger and its surgical application. *J Hand Surg.* 1986;11:163-74.
7. Sherif MM. First dorsal metacarpal artery flap in hand reconstruction, I: anatomy study. *J Hand Surg.* 1994;19:26-31.
8. Kapandji A. Clinical test of apposition and counter-apposition of the thumb. *Ann Chir Main.* 1986;5:67-73.
9. Hurren J, Cormack G. The application of the rotation flap to the dorsum of the hand. *Br J Plast Surg.* 2000;53:491-4.
10. Rehim SA, Chung KC. Local flaps of the hand. *Hand Clin.* 2014;30:137-51.
11. Biswas D, Wysocki RW, Fernandez JJ, Cohen MS. Local and regional flaps for hand coverage. *J Hand Surg Am.* 2014;39:992-1004.
12. Rezende DMR, Junior MR, Cho AB, Hasegawa OH, Ribak S. Anatomic study of the dorsal arterial system of the hand. *Rev Hosp Clin Fac Med Sao Paulo.* 2004;59:71-6.
13. Satish C, Nema S. First dorsal metacarpal artery island flap: A useful flap for reconstruction of thumb pulp defects. *Indian J Plast Surg.* 2009;42:32-5.
14. Khatib EHA. Clinical experiences with the extended first dorsal metacarpal artery island flap for thumb reconstruction. *J Hand Surg Am.* 1998;23:647-52.
15. Ege A, Tuncay I, Ercetin O. Foucher's first dorsal metacarpal artery flap for thumb reconstruction: evaluation of 21 cases. *Isr Med Assoc J.* 2002;4:421-3.
16. Muyltermans T, Hierner R. First dorsal metacarpal artery flap for thumb reconstruction: a retrospective clinical study. *Strategies Trauma Limb Reconstr.* 2009;4:27-33.
17. Delikonstantinou IP, Gravvanis AI, Dimitriou V, Zogogiannis I, Douma A, Tsoutsos DA. Foucher first dorsal metacarpal artery flap versus little heterodigital neurovascular flap in resurfacing thumb pulp loss defects. *Ann Plast Surg.* 2011;67:119-22.
18. Trankle M, Sauerbier M, Heitmann C, Germann G. Restoration of thumb sensibility with the innervated first dorsal metacarpal artery island flap. *J Hand Surg.* 2003;28:758-66.
19. Eski M, Nisanci M, Sengezer M. Correction of thumb deformities after burn: Versatility of first dorsal metacarpal artery flap. *Burns.* 2007;33:65-71.
20. Ratcliffe RJ, Regan PJ, Scerri GV. First dorsal metacarpal artery flap cover for extensive pulp

- defects in the normal length thumb. *Br J Plast Surg.* 1992;45:544-6.
21. Cil Y, Eski M, Isik S. First dorsal metacarpal artery adipo-fascial flap for thenar burn contracture releasing. *Burns.* 2008;34:127-30.
 22. Sherif MM. First dorsal metacarpal artery flap in hand reconstruction II Clinical application. *J Hand Surg.* 1994;19:32-8.

Cite this article as: Ravada S, Mahipathy SRRV, Durairaj AR, Sundaramurthy N Jayachandiran AP. Functional and aesthetic outcomes of first dorsal metacarpal artery flap for thumb reconstruction: a prospective study. *Int Surg J* 2020;7:2268-74.