

## Case Report

# Pseudomyxoma peritonei: two case study and literatures review

Ibrahim F. Alsubaiee\*

Department of Surgery, Basrah College of Medicine, Basrah University, Basrah, Iraq

**Received:** 06 April 2020

**Revised:** 09 June 2020

**Accepted:** 10 June 2020

**\*Correspondence:**

Dr. Ibrahim F. Alsubaiee

E-mail: [dr.ibraheemfns@gmail.com](mailto:dr.ibraheemfns@gmail.com)

**Copyright:** © the author(s), publisher and licensee Medip Academy. This is an open-access article distributed under the terms of the Creative Commons Attribution Non-Commercial License, which permits unrestricted non-commercial use, distribution, and reproduction in any medium, provided the original work is properly cited.

### ABSTRACT

Pseudomyxoma peritonei (PMP) is a rare neoplastic illness with unique clinical and pathologic patterns. This disease characterized by being chronic, indolent, and relapsing. It is diagnostically challenging and very vague disease. It characterized by huge amounts of thick mucinous ascites with multiple omental and peritoneal implants that is gradually fill the abdominal and pelvic cavities. The most common clinical features are progressive abdominal distention with increase in the abdominal girth. Diagnosis of Pseudomyxoma peritonei (PMP) is usually difficult due to its vague symptoms especially in the early stages. Ultrasound examination is very useful and generally has pictures similar to that of CT scan images. Treatment of Pseudomyxoma peritonei (PMP) is cytoreductive (debulking) surgery to remove the mucin and the tumor implants in the peritoneal cavity. This is followed by intraoperative hyperthermic peritoneal chemotherapy (HIPEC). Recurrence of pseudomyxoma peritonei (PMP) patients is quite common as particularly when the disease is diagnosed and treated in the late stage.

**Keywords:** Pseudomyxoma peritonei, Mucinous ascites, Mucocele of appendix

### INTRODUCTION

Pseudomyxoma peritonei (PMP) a rare and complex condition caused by cancerous cells characterized by production of abundant mucin and gelatinous ascites. It starts in most cases in the appendix or rarely from the other part of bowel, an ovary or the bladder. It affect about two people per million each year, between 20 and 50 years, both men and women but slightly more common in females.<sup>1</sup> The tumor arise first as a polyp which is rarely discovered as it doesn't cause any symptoms. The tumor grows and eventually rupture through the wall of the appendix in to the abdominal cavity where more new tumors then studded and developed.<sup>2</sup> These tumors secrete a jelly-like mucin which accumulates excessively in the peritoneal cavity causing abdominal distention with the characteristic "jelly belly" which compressed the vital organs and leads definitely to bowel obstruction. About 10% of patients

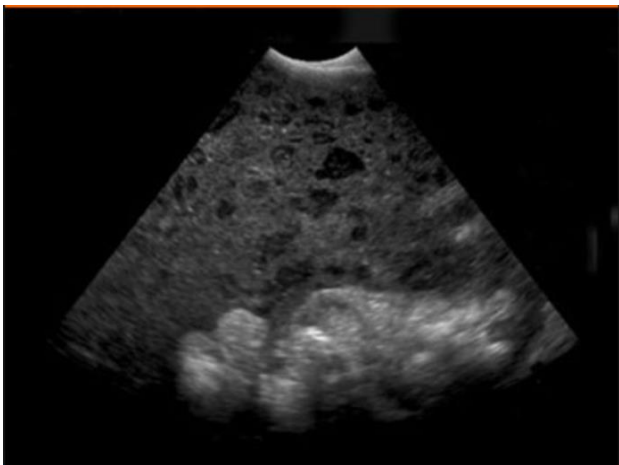
with pseudomyxoma peritonei (PMP) die within 5 to 6 years after their first presentation. Recurrent and advanced abdominal disease causing intestinal obstruction is the leading cause of the morbidity and mortality.<sup>3</sup> This paper described two patients (one male and one female patient) with pseudomyxoma peritonei. Besides, literatures about this disease entity regarding, the incidence, clinical manifestation, diagnosis, management modalities has been reviewed.

### CASE REPORT

#### Case 1

A 50 years old male patient presented with gradual abdominal distention, loss of appetite and weight loss for 6 months associated with mild to moderate abdominal pain, dyspnea especially when lying supine, tiredness and infrequent vomiting. Fever was not recorded. Patient had

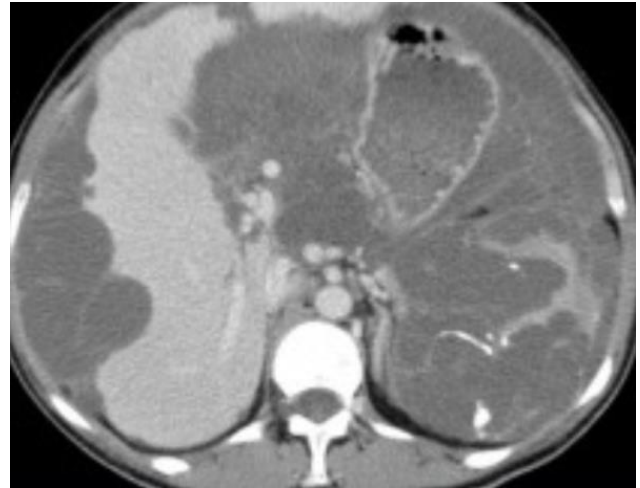
no history of prior laparotomy apart from previous appendectomy 30 years ago for ruptured inflamed appendix. Clinical examination revealed abdominal distention, fullness of flanks with umbilical hernia. Massive non shifting ascites was noticed (Figure 1). No definite abdominal mass was detected by clinical exam and no organomegaly. Routine blood investigations were all normal except for C- reactive protein which was positive. Serum albumin was 3 g/dl. Colonoscopy was normal up to splenic flexure. Abdominal ultrasound revealed ascites which was immobile and loculated with many cystic masses of different sizes. Abdominal CT scan showed multiple solid masses of variable size studded throughout the peritoneal cavity associated with massive ascites (Figure 2). Diagnostic aspiration of ascetic fluid was difficult and revealed thick scanty gelatinous material. Ultrasound guided FNAC of one of peritoneal masses revealed mucinous secreting malignant cells suggested the diagnosis of mucinous adenocarcinoma. Diagnostic laparoscopy was then performed. The peritoneal cavity was filled with mucin in addition to multiple gelatinous masses studded on the intestinal surface and peritoneum. The diagnosis of pseudomyxoma peritonei of appendicular origin was proved by histopathological examination (Figure 3). Debulking surgery with omentectomy, segmental small bowel resection, right hemicolectomy, and adhesiolysis were performed. Patient remained well and symptom free and was followed regularly. Two years later, recurrence of disease occurred. Further debulking surgery was done. Patient is still alive and followed every 3 months interval.



**Figure 1: Abdominal US: thick echogenic ascites.**

**Case 2**

A 61 years old female patient with history of progressive fatigue, tiredness and anemia for 3 months duration presented with sudden onset right lower quadrant severe colicky abdominal cramps accompanied by nausea and vomiting with no fever.

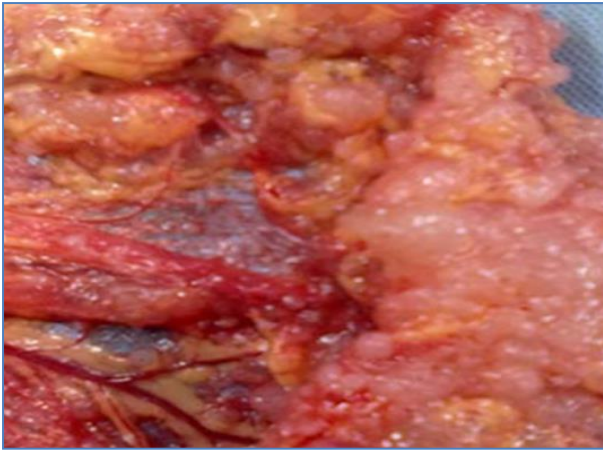


**Figure 2: Abdominal CT: scalloping of liver and spleen.**

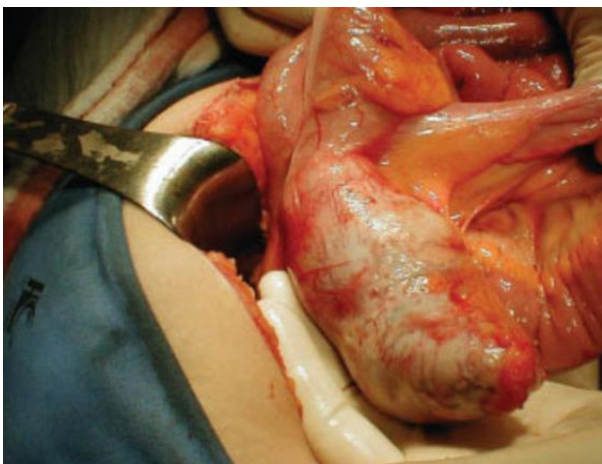
The patient gave a history of similar attacks before of about 30 to 60 minutes duration with last attack was two weeks before this recent severe attack. The other important findings in the history were the presence of asymptomatic paraumbilical hernia, which was present for 5 years.

Initial examination, patient was in pain, afebrile with moderate right lower abdominal tenderness, positive rebound tenderness and guarding with mild symmetrical abdominal distention. There were no palpable masses. Bowel sounds were positive. Routine laboratory investigations were all of normal values. Urinalysis was irrelevant and pregnancy test was also negative. Both chest in erect position and plain abdominal radiographs were normal. Ultrasound scan showed mild to moderate ascites. Soft tissue masses of different sizes studded over the omentum and through the peritoneal and pelvic cavity were also seen by ultrasound, provisional diagnosis of perforated acute appendicitis with local peritonitis was made. Laparotomy via right paramedian incision was planned. During laparotomy, copious amounts of thick mucinous ascites were observed throughout the whole peritoneal and pelvic cavity pouring out from the appendix (Figure 4). The thick gelatinous material observed covering the omentum, small intestine and part of ascending colon. A right hemicolectomy, omentectomy and resection of small bowel that studded with gelatinous masses were performed. The abdominal cavity was washed with povidone iodine diluted with normal saline and closed in layers with corrugated drain.

Histopathological examination showed appendicular mucinous villous adenoma complicated by pseudomyxoma peritonei. Patient was followed up regularly every 6 months and she remains symptoms free for 14 months post surgery.



**Figure 3: Pseudomyxoma involving the omentum.**



**Figure 4: Mucocele of the appendix.**

## DISCUSSION

Pseudomyxoma peritonei is a rare neoplastic illness with unique clinical and pathologic patterns. Pseudomyxoma peritonei was first mentioned in 1884 by Werth who described copious intraabdominal deposit of thick gelatinous pseudomucin due to “ovarian pseudomucinous cystomas” perforation.<sup>4</sup> This disease characterized by being chronic, indolent, and relapsing. It is diagnostically challenging and very vague disease. It is most prevalent in female patients with ages ranges between 50 and 70 years (median age 53 years old). The recorded incidence is about 1 to 2 per million per year and in 2 of every 10,000 laparotomies. It characterized by huge amounts of thick mucinous ascites with multiple omental and peritoneal implants that is gradually fill the abdominal and pelvic cavities<sup>4,5</sup>

Pseudomyxoma peritonei is classified as either low grade malignancy which is deadly disease if not treated properly, high grade which is more aggressive cancer cells and the disease is more difficult to treat and the third type is the hybrid type or intermediate type.

It spreads inside the abdomen when the mucus collects and causes symptoms as it was noted in our cases. It develops very slowly and it may take many years before any symptoms cancer appear.<sup>5</sup>

The pathogenesis of PMP is obscure. The events occurring in PMP is proved to arise from rapid growth of an appendicular mucinous adenoma which increasing in size to obstruct the lumen of the appendix with progressive distention by the accumulating mucus and tumor cells.<sup>6</sup> The appendix ultimately perforates with subsequent leakage of thick mucinous substances from the adenoma into peritoneal cavity. the mucin contains epithelial cells which proliferate progressively within the abdominal cavity leading to production of massive amount of mucus. The movement of peritoneal fluid and its absorption together with gravity effect are the main physical factors that govern the dissemination and distribution of PMP within the abdominal cavity.

Ronnett et al in 1995 proposed that PMP cases can be classified into two diagnostic types: the first type consists of benign tumor represented by an adenoma (peritoneal adenomucinosis, DPAM) and the second type represented by mucinous carcinoma (peritoneal mucinous carcinomatosis, PMCA) with a rare third type limited for intermediate or hybrid pattern.<sup>7</sup> Highly differentiated mucinous adenocarcinoma (low grade features) is commonly used by American Joint Committee of cancer and WHO and it is synonymous with DPAM category designation Low-grade mucinous adenocarcinoma may be classified as "benign" or low grade because this type of the tumors do not have the characteristics of deep invasion into the involved tissue and very rarely metastasize to the other organs. On the other side, poorly differentiated mucinous adenocarcinoma (high grade) has the ability of invasion and remote metastasis. It carries very worse prognosis<sup>7,8</sup>

Clinical manifestations of PMP remains silent and its symptoms take a while to appear. Symptoms of PMP are non specific that results in delay the definite diagnosis and treatment. The main symptoms of our patients were misleading and vague chronic ill-health and tiredness were the main complaints before the disease progress, our patients then complaining from increase in the abdominal girth, loss of appetite, progressive general fatigue and abdominal or pelvic pain.

The most common clinical features are progressive abdominal distention with increase in the abdominal girth (40%), unilateral or bilateral pelvic masses (20%), umbilical hernial sac containing tumors (20%), symptoms mimic that of appendicitis (10%), and infertility especially in female patients (10%).<sup>5-7</sup>

Diagnosis of PMP is usually difficult due to its vague symptoms especially in the early stages. Laboratory investigations are usually non specific. In the late stage of PMP, plain abdominal film used when the abdomen is

swollen by mucinous ascites reveal displacement of small intestine centrally with haziness or obliteration of the psoas muscle border shadow with fine calcifications dispersed throughout the peritoneal cavity.<sup>8</sup> With the advancement of the disease, abdominal plain X-ray films become important in detecting bowel obstruction.

Ultrasound examination is very useful and generally has pictures similar to that of CT scan images showing non shifting ascites, echogenic abdominal masses several, septations, and scalloping of both the liver and spleen.<sup>8,9</sup>

Computed tomography can precisely diagnose PMP if the pathognomic scalloping effect of visceral surface due to compression by thick mucinous secretion and progressive fibrosis is seen as in our cases. CT scan shows four particular features displacement of the bowel posteriorly with multiple hypo-dense lesions and fine scattered calcifications, wide spread infiltration of peritoneum with thick ascites with septated pockets scattered through the whole peritoneal cavity, hypo-dense and attenuated intrahepatic masses and scalloping of solid intra-abdominal organ due to compression of nearby peritoneal studded masses.<sup>9</sup>

MRI imaging is still investigated and evaluated, may prove to be more useful than CT scan particularly in detecting the visceral invasion by mucinous carcinoma although these events are quite rare.<sup>8-10</sup>

Treatment of PMP is cytoreductive (debulking) surgery to remove the mucin and the tumor implants in the peritoneal cavity. This is followed by intraoperative hyperthermic peritoneal chemotherapy (HIPEC). Early postoperative intraperitoneal chemotherapy (EPIC) soon after the surgery is over may also be used. This procedure is collectively called the Sugarbaker technique.

Surgical debulking principally consist of excision of the appendix, right colon and the greater omentum together with the uterus and both ovaries. Recurrence of the tumor is always inevitable due to residual disease<sup>10</sup>. Re-debulking surgery may be feasible only for selected patients and this type of surgery becomes technically demanding, time consuming and carries several complications<sup>10,11</sup>

### ***Sugarbaker technique***

Cytoreductive operation with intra-peritoneal hyperthermic perfusion of chemotherapy (5FU, Mitomycin C at 42 degree C for short period (90 minutes) was reported by Sugarbaker from the Washington Cancer Institute, for cases with extensive PMP.<sup>11</sup> This type of treatment involves an initial attempt of aggressive and generous destruction and excision of all grossly visible tumor masses throughout the whole abdominal cavity. Deraco et al recorded in their study that sugarbaker procedure resulted in complete removal of tumor with effective local control and prolong long-term survival.<sup>12</sup>

The use of heated intra-peritoneal heated chemotherapeutic agents during surgery after complete release of adhesions and just before anastomosis are achieved helps good perfusion of the chemotherapeutic agents into the peritoneal surfaces and involved organs. Mitomycin C and 5FU characterized by a slow clearance from abdominal cavity. The effects of the chemotherapeutic agents are accentuated by the effect of hyperthermia in order to achieve a maximum cancer cell killing. The chemotherapeutic agents that are most frequently used are mitomycin C, 5-FU, cisplatinum and cyclophosphamide<sup>13</sup>

Systemic chemotherapy could be used as adjuvant or additional palliative treatment. In fact systemic chemotherapy is usually ordered for advanced and recurrent cases, or when the disease has been metastasized to the regional lymph nodes or distant organs. A combination of mitomycin C and capecitabine (MCap) is commonly given over a 3 to 6 months period and approximately 40% to 50% of patients get benefit from this type treatment.<sup>9,13</sup>

Recurrence of pseudomyxoma peritonei patients is quite common as particularly when the disease is diagnosed and treated in the late stage. Data obtained from Mayo clinic series depending on their series of 56 patients with PMP observed that 76% of PMP cases definitely recurred and about half of these recurrences noticed between the second and third year after the initial treatment The 5 and 10 year survival rates of their patients were 53% and 32%, respectively with 5.9 year median survival rate.<sup>14</sup>

The prognosis of PMP was a number of prognostic factors have been defined by Sugarbaker.<sup>15</sup> These factors include the primary origin of the tumor, grade of the tumor, preoperative tumor size and extent of cytoreductive procedures. Intestinal obstruction due to advanced abdominal disease accounts for most of morbidity and mortality among patients. Generally, 5 and 10 year survival rates are approximately 50% and 20% respectively.

### **CONCLUSION**

Pseudomyxoma peritoneis a rare and complex condition caused by cancerous cells characterized by production of abundant mucin and gelatinous ascites. The disease has a wide spectrum of presentation and variable outcomes. Diagnosis is challenging and made during laparoscopy and histopathological examination. Cytoreductive (debulking) surgery together with hyperthermic intra-peritoneal chemotherapy (HIPC) significantly increase disease free period and improve survival.

*Funding: No funding sources*

*Conflict of interest: None declared*

*Ethical approval: Not required*

## REFERENCES

1. Hinson FL, Ambrose NS. Pseudomyxoma peritonei. *Br J Surg.* 1998;85:1332-9.
2. Bradley RF, Stewart JH, Russell GB, Levine EA, Geisinger KR. Pseudomyxoma peritonei of appendiceal origin: a clinicopathologic analysis of 101 patients uniformly treated at a single institution, with literatures review. *Am J Surg Pathol.* 2006;30:551-9.
3. Mukherjee A, Cecil TD, Moran BJ. Pseudomyxoma peritonei usually originates from the appendix: a review of evidence. *Eur J Gynaecol Oncol.* 2004;25:411-4.
4. Moran BJ, Cecil TD. The etiology, clinical presentation, and management of pseudomyxoma peritonei. *Surg Oncol Clin N Am.* 2003;585-603.
5. Galani E, Marx GMF, Steer CB, Culora G, Harper PG. Pseudomyxoma peritonei: the controversial disease. *Int J Gynaecol Cancer.* 2003;13:413-8.
6. Sherer DM, Abulafia O, Eliakim R. Pseudomyxoma peritonei: a review of current literature. *Gynecol Obstet Invest.* 2001;51(2):73-80.
7. Ronnett BM, Shmookler BM, Diener-West M, Sugarbaker PH, Kurman RJ. Immunohistochemical evidence supporting the appendiceal origin of pseudomyxoma peritonei in women. *Int J Gynaecol Pathol.* 1997;16:1-9.
8. Ronnett BM, Zahn CM, Kurman RG, Kass mf, Sugarbaker PH, Shmookler BM. Disseminated peritoneal adenomucinosis and peritoneal mucinous carcinomatosis. A clinicopathologic analysis of 109 cases with emphasis on distinguishing pathologic features, site of origin, prognosis, and relationship to "pseudomyxoma peritonei". *Am J Surg Pathol.* 1995;19(12):1390-408.
9. Esquivel FL, Sugarbaker PH. Clinical presentation of pseudomyxoma peritonei syndrome. *Br J Surg.* 2000;(10)1414-1418.
10. Ruths V, Acherman YI, van de Vijver MI, Hart AA, Verwall VJ, Zoetmulder FA. Pseudomyxoma peritonii: a review of 62 cases. *Eur J Surg Oncol.* 2003;29: 682-8.
11. Loungnarath R, Causeret S, Bossoard N, Faheez M, Sayag-Beaujard AC, Brignad C, Gilly F, Glehen O. Cytoreductive surgery with intraperitoneal chemohyperthermia for treatment of pseudomyxoma peritonei: a prospective study. *Dis Colon Rectum.* 2005;48:1372-9.
12. Deraco M, Gronchi A, Mazzaferro V, Inglese MG, Pennacchoili E, Kusamura S, Rizzi M, Anselmi RA, Jr, Vaglini M. Feasibility of peritonectomy associated with intraperitoneal hyperthermic perfusion in patients with Pseudomyxoma peritonei. *Tumori.* 2002;88:370-5.
13. Dhage-Ivatury S, Sugarbaker PH. Update on the surgical treatment of mucocele of the appendix. *J Am Coll Surg.* 2006;202:680-4.
14. Smeenk RM, Verwaal VJ, Antonini N, Zoetmulder FA. Progression of pseudomyxoma peritonei after combined modality treatment: management and outcome. *Ann Surg Oncol.* 2007;14:439-99.
15. Sugarbaker PH. Peritonectomy procedures. *Surg Oncol Clin N Am.* 2003;12:703-27.

**Cite this article as:** Alsubaiee I. Pseudomyxoma Peritonei: Two Cases Study and Literatures Review. *Int Surg J.* 2020;7: 3423-7.