

Case Report

Occult papillary carcinoma of thyroid presenting as cervical lymphadenopathy in a young male: case report

Nida Khan*, Abhishek Mahadik, Meena Kumar, Manish Kumar

Department of General Surgery, Dr. D. Y Patil University School of Medicine, Navi Mumbai, Maharashtra, India

Received: 04 April 2020

Accepted: 08 May 2020

*Correspondence:

Dr. Nida Khan,
E-mail: khannida08@yahoo.com

Copyright: © the author(s), publisher and licensee Medip Academy. This is an open-access article distributed under the terms of the Creative Commons Attribution Non-Commercial License, which permits unrestricted non-commercial use, distribution, and reproduction in any medium, provided the original work is properly cited.

ABSTRACT

Papillary carcinoma of thyroid accounts for 80% of all thyroid malignancies. They tend to have a female preponderance and present in the 4th to 5th decade of life, as a slow growing midline mass. Cervical metastases are common, blood borne being rare. We present a case of a 29 years old who presented with cervical lymphadenopathy that was secondary to an occult papillary carcinoma of thyroid. Patient underwent total thyroidectomy with bilateral neck node dissection for the same.

Keywords: Papillary carcinoma thyroid, Occult primary, Orphan Annie eye nuclei

INTRODUCTION

Thyroid malignancies account for <1% of all cancers in the United States, with 6 deaths per million person per year.¹ Papillary carcinoma is the most common thyroid malignancy and presents as a midline, slow growing neck mass. Cervical metastases are common, giving rise to the theory of 'lateral aberrant thyroid', which is a misnomer, as there is no aberrant thyroid tissue but metastases from a primary malignancy. It may present as an occult primary with normal thyroid gland or non-significant thyroid enlargement.² Diagnosis can be confirmed on fine needle aspiration cytology (FNAC) and ultrasonography (USG) neck should be done to evaluate contralateral lobe and cervical lymph nodes in central and lateral neck compartments. Distant metastases are uncommon but ultimately develop in 20% and are most commonly to lung, followed by brain, bone and liver.³

CASE REPORT

A 29 years old male presented to the outpatient department with a swelling over the right upper side of his neck since, 6 months and a swelling over right

supraclavicular region since, 1 month that was noticed by his wife. Swelling had progressively increased in size over time. He had no history of fever, weight loss, dyspnoea, dysphagia or hoarseness of voice. He had no co morbidities or any significant family history. He had no history of radiation exposure. On examination, he was of average built, well nourished, with a pulse rate of 74 beats/min, and multiple cervical lymph nodes on the right, the largest being a 3×3 cm palpable lymph node in the posterior triangle of neck on the right (level 5) and he had no other palpable lymphadenopathy or any abnormality on neck examination. FNAC of the lymph node was performed, which was inconclusive. USG neck was suggestive of bulky thyroid gland with increased vascularity, right lobe measuring 2×1.5×1.6 cm, left lobe measuring 1.8×2.4×2.1 cm, heterogenous echotexture with increased vascularity, with intact capsule and multiple cervical lymph nodes on right side with loss of hilar fat, increased peripheral vascularity, few foci of calcification increased vertical diameter and distorted architecture, largest noted in right cervical levels 5 and 4. Repeat FNAC was performed for cervical lymph node as well as thyroid gland. It revealed malignant tumour cells in clusters with nuclear and cellular pleiomorphism with

increased nuclear cytoplasmic ratio, hyperchromatism, inconspicuous nucleoli and moderate cytoplasm from right cervical lymph node site, whereas thyroid FNAC was suggestive of follicular cells and colloidophages without any evidence of atypia or malignancy. His hemogram, chest X-ray and neck X-ray were within normal limits and his thyroid profile was as follows; T3- 1.2 ng/ml, T4-7 mcg/dl, TSH- 0.3 uIU/ml. CECT neck was performed, which was suggestive of few sub centimetre sized hypodense non enhancing nodules in right lobe of thyroid, largest measuring 8×7 mm, few of them had tiny calcific foci within. A 3.5×2.4 cm sized predominantly hypodense lesion was seen in right posterior triangle. It had a heterogeneously hyperdense component within with post contrast study showing heterogenous enhancement. Medially the lesion abutted the obliquus capitus superior muscle, laterally sternocleidomastoid muscle, anteriorly the internal jugular vein without involving it. Multiple sub-centimeter to centimeter lymph nodes in right cervical region at levels 3, 4 and 5 with foci of calcification within were seen. Patient was posted for cervical lymph node incisional biopsy to confirm the origin of primary tumour, with a plan to do pan-endoscopy if it was inconclusive. Histopathology of lymph node diagnosed cervical metastases from papillary carcinoma thyroid. Preoperative indirect laryngoscopy was done to confirm position of vocal cords. A total thyroidectomy with dissection of central and both lateral compartment nodes was done (level 2-6). Subcutaneous drain was placed which was removed on post-operative day 3 and patient was discharged on day 5, without any complications. Histopathology confirmed the diagnosis of a well differentiated papillary carcinoma of right lobe of thyroid with positive right sided cervical nodes. Patient was referred for RAIT (radioactive iodine therapy) after starting on suppressive dose of L-thyroxine. Patient was followed up for one year without any recurrence.

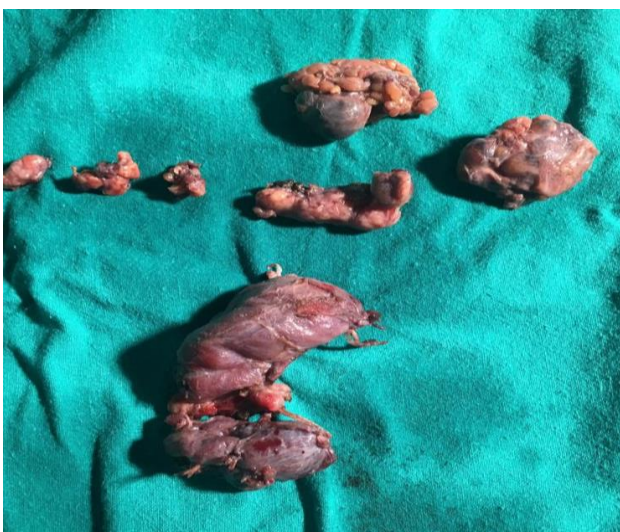

Figure 1: Post-operative specimen, thyroid gland with lymph nodes.

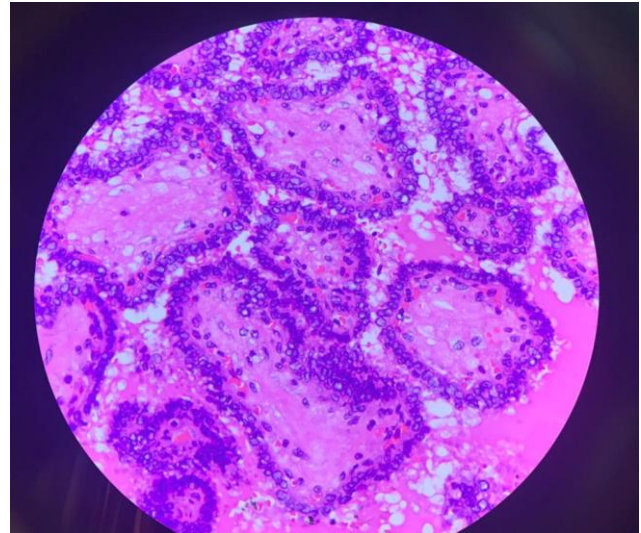


Figure 2: Histopathology of thyroidectomy specimen showing papillary carcinoma.

DISCUSSION

Thyroid malignancies are the one of the commonest endocrine malignancies, however most of them are well differentiated malignancies with excellent prognosis.⁴ Radiation exposure increases risk of thyroid malignancy, particularly papillary carcinoma.⁵ Pre-existing multinodular goitre may turn into follicular thyroid cancer.⁶ A family history of thyroid cancer is a risk factor for both papillary and non-papillary thyroid cancers. Cowden syndrome, Familial adenomatous polyposis, Werner's syndrome, Carney complex type 1, McCune Albright syndrome all are associated with non-medullary thyroid cancers. Papillary carcinomas are the commonest, and are seen more often in females, and rarely in children. Grossly the lesions are often 2-3cms in size although they may be smaller or larger in size. They are firm, white, show calcification and may even be cystic and thereby confound the diagnosis.⁷ Microscopically, the neoplastic papillae have a central core of fibrovascular tissue.⁸ Psammoma bodies are seen in 50% cases, 'Orphan Annie eye' nuclei are intracytoplasmic inclusions, also seen are nuclear pseudo inclusions. About 50% have regional lymph node metastases at the time of presentation. It may also present as a cervical lymph node without any obvious thyroid swelling. It is commonly multicentric. Distant metastases are uncommon. If they occur, lungs followed by bone, brain and liver are affected.⁹ Clinically it may be a firm or hard, thyroid swelling, without any signs of compression usually. Lymph nodes are usually palpable in the neck or patient may present with a neck node with an occult primary. Lymph node metastasis first involves pre and paratracheal lymph nodes, followed by para glandular, deep upper cervical, deep lower and lateral cervical and submandibular nodes.¹⁰ Diagnosis is made on FNAC, cold nodule on radioisotope scan, high TSH level in blood, USG neck for both thyroid and lymph node status.

CT scan of neck are indicated only in specific circumstances and not routinely. Features of greatest prognostic value include patient's age at presentation, small tumour size, total encapsulation, extra thyroid extension, multicentricity and presence of distant metastases.¹¹ Treatment is near total or total thyroidectomy with central node compartment dissection. Depending on involvement of cervical lymph nodes, lateral cervical or modified radical neck dissection is done.¹² Total thyroidectomy has the advantage that it allows monitoring of post-operative thyroglobulin levels, post-operative radioiodine can be used to detect residual disease, residual normal tissue and local or distant metastases.¹³

CONCLUSION

Papillary carcinoma of the thyroid, although the gland's most common malignancy, may present as cervical lymphadenopathy without a significant thyroid enlargement. Diagnosis is based on FNAC and ultrasound neck findings. Treatment is surgical, near total or total thyroidectomy with central node compartment dissection with or without lateral compartment dissection followed by RAIT and suppressive dose of L-thyroxine.

ACKNOWLEDGEMENTS

Authors would like to thank Dr. Rubina Hitawala for pathology image.

Funding: No funding sources

Conflict of interest: None declared

Ethical approval: Not required

REFERENCES

1. Schwartz's Principles of Surgery, 10th edition, pg. 1542.
2. Monchik, Jack M, Petris GD, Crea CD. Occult papillary carcinoma of the thyroid presenting as a cervical cyst. Surg. 2001;129(4):429-32.
3. Strate, Susan M, Lee EL, Childers JH. Occult papillary carcinoma of the thyroid with distant metastases. Cancer. 1984;54(6):1093-100.
4. Kilfoy AB, Ward MH, Sabra MM, Devesa SS. Thyroid cancer incidence patterns in the United States by histologic type, 1992-2006. Thyroid. 2011;21(2):125-34.
5. Albi E, Cataldi S, Lazzarini A. Radiation and Thyroid Cancer. Int J Mol Sci. 2017;18(5):911.
6. Gullo I, Batista R, Pereira PR, Soares P, Barroca H, Sucesso MDB, et al. Multinodular Goiter Progression Toward Malignancy in a Case of DICER1 Syndrome: Histologic and Molecular Alterations. Am J Clin Pathology. 2018;149(5):379-86.
7. Rosai J, Carcangui ML, Lellis DRA. Tumors of the Thyroid Gland. Atlas of Tumor Pathology, Fascicle 5. Armed Forces Institute of Pathology: Washington, DC; 1992.
8. Carcangui ML, Zampi G, Pupi A. Papillary carcinoma of the thyroid: a clinico-pathologic study of 241 cases treated at the University of Florence, Italy. Cancer. 1985;55:805-28.
9. Hoie J, Stenwig AE, Kullmann G. Distant metastases in papillary thyroid cancer. A review of 91 patients. Cancer. 1988;61:1-6.
10. Noguchi, Shiro, Noguchi A, Murakami N. Papillary carcinoma of the thyroid I. Developing pattern of metastasis. Cancer. 1970;26(5):1053-60.
11. Carcangiu, Luisa M. Papillary carcinoma of the thyroid. A clinicopathologic study of 241 cases treated at the University of Florence, Italy. Cancer. 1985;55(4):805-28.
12. Rotstein, Lorne. The role of lymphadenectomy in the management of papillary carcinoma of the thyroid. J Surg Oncology. 2009;99(4):186-8.
13. Kebebew, Electron, Clark OH. Differentiated thyroid cancer: complete rational approach. World J Surg. 2000;24(8):942-51.

Cite this article as: Khan N, Mahadik A, Kumar M, Kumar M. Occult papillary carcinoma of thyroid presenting as cervical lymphadenopathy in a young male: case report. Int Surg J 2020;7:2009-11.