

Original Research Article

Resectable locally advanced gastric adenocarcinoma: interim analysis

Subbiah Shanmugam*, Prem Kishore

Department of Surgical Oncology, Government Royapettah Hospital, 1 Westcott Road, Royapettah, Chennai, Tamil Nadu, India

Received: 02 April 2020

Revised: 10 June 2020

Accepted: 11 June 2020

*Correspondence:

Dr. Subbiah Shanmugam,

E-mail: subbiahshanmugam67@gmail.com

Copyright: © the author(s), publisher and licensee Medip Academy. This is an open-access article distributed under the terms of the Creative Commons Attribution Non-Commercial License, which permits unrestricted non-commercial use, distribution, and reproduction in any medium, provided the original work is properly cited.

ABSTRACT

Background: The MAGIC and ACCORD 07 trials have established the role of perioperative chemotherapy in locally advanced gastric adenocarcinoma. A more recent study has demonstrated the superiority of the FLOT perioperative regimen. The best strategy to improve outcomes has yet to be determined. Aims of the study were to evaluate perioperative chemotherapy in terms of morbidity and tolerance of FLOT regimen with modification and histopathological response

Methods: This prospective study was started after ethical committee approval in February 2019 at a tertiary cancer center in South India for a period of 1 year up till February 2020. Patients fulfilling inclusion criteria were enrolled. Perioperative chemotherapy was given as scheduled regimen and adverse effects and response to preoperative chemotherapy were recorded. Radical D2 gastrectomy and histopathology assessed analysed by using IBM SPSS statistics ver. 21 and descriptive statistics used.

Results: From February 2019 till February 2020, a total of 24 patients of newly diagnosed adenocarcinoma of the stomach of which 18 patients were nonmetastatic on workup. Moderately different (38.8%), well-differentiated in 11.2%, poorly differentiated in 50%. Total 66.7% were diagnosed as metastatic on staging laparoscopy, peritoneal wash cytology in 50% was negative. The cardiopulmonary resuscitation was seen in two patients.

Conclusions: Even though it is an interim analysis with less number of patients enrolled, so far it can be concluded that all patients where surgery is planned should undergo peritoneal lavage cytology and FLOT regimen can be practised with acceptable morbidity. Long term results after completion of study will definitely throw more light.

Keywords: 5-FU, Cardiopulmonary resuscitation, Docetaxel, D2 Gastrectomy, Gastric adenocarcinoma, Leucovorin, Oxaliplatin

INTRODUCTION

In locally advanced gastric cancer, it is crucial to recognize tumor T staging, lymph node status, the plane with adjacent structures and the presence of peritoneal carcinomatosis before initiation of perioperative chemotherapy. Contrast-enhanced CT (CECT) scan helps to evaluate T stage, nodal status, planes with adjacent structures distant visceral metastasis, ascites, large peritoneal and omental nodules. However small peritoneal nodules are difficult to pick up on a CT scan. Staging laparoscopy allows us to directly see the

peritoneal and visceral surface, to take ascitic or peritoneal washing fluid cytology and biopsy of suspected lesions. It has been estimated that occult M1 is detected by staging laparoscopy in about 30-40% of patients.¹

Surgical resection is the only curative treatment option for gastric cancer. Despite widespread adoption of multimodality perioperative treatment strategies, 5-year overall survival rates remain low. Peri-operative chemotherapy may be useful to downstage the tumor, increase R0 resection rate, treat micrometastatic disease

and improve overall survival in potentially resectable locally advanced stomach adenocarcinoma.

Objective of the study

To evaluate perioperative chemotherapy in terms of morbidity and tolerance of FLOT regimen with modification and histopathological response

METHODS

This prospective study was started after ethical committee approval in February 2019 at a tertiary cancer center in South India. The data collected up till February 2020 is presented here for interim analysis. For each patient, informed consent was taken and data collection including age, sex, performance status, lesion details like site of the lesion, histology, and grade; stage on CECT. Staging laparoscopy and peritoneal washing cytology was performed whenever indicated.

The potentially resectable gastric adenocarcinoma patients presenting to our hospital meeting the inclusion criteria were enrolled for the study. Perioperative chemotherapy was given every two weeks as follows- 4 cycles of modified FLOT regimen preoperatively, surgery after four weeks and 4 cycles of chemotherapy postoperatively were given starting 4 weeks after surgery. Chemotherapy adverse effects, if any, were recorded. Response to preoperative chemotherapy was assessed by clinical examination, upper GI endoscopy, contrast-enhanced CT scan abdomen and pelvis, and preoperative laparoscopy. Laparoscopy-assisted open radical D2 distal or total gastrectomy was performed based on the site of the lesion. Intraoperative and postoperative events were documented. Postoperative histopathology assessment in terms of surgical margins, number of retrieved and positive nodes, and a pathological response to chemotherapy of tumor was done.

Peritoneal washing was performed by instilling 200 mL of normal saline into the different quadrants of the abdominal cavity. The fluid was dispersed by the gentle stirring of the area and then was aspirated from different portions of the peritoneal cavity. Areas typically included were the right and left subphrenic space and the pouch of Douglas. We aimed to retrieve >50 ml of washings for cytologic assessment.

Inclusion criterion

Patients of any age who had a World Health Organization (WHO) performance status of 0 or 1; histologically proven adenocarcinoma of the stomach; stage II or III disease

Exclusion criterion

Poor performance status (PS2 or higher); Deranged renal, liver and bone marrow function; patients who have previously received cytotoxic chemotherapy or

radiotherapy; patients with an acute condition (hemorrhage, perforation) associated with carcinoma; patients with complete gastric outlet obstruction; presence of peritoneal carcinomatosis, positive peritoneal washing cytology, and metastatic disease; tumors involving esophagogastric junction with the tumor epicenter no more than 2 cm into the proximal stomach are staged as esophageal cancers.

Descriptive statistical analyses was done using IBM SPSS Statistics ver. 21.

RESULTS

Since February 2019 till February 2020, a total of 2476 patient were admitted in the surgical oncology department, out of these 24 patients was newly diagnosed adenocarcinoma of the stomach. In this group, 8 patients were diagnosed metastatic on clinical, radiological and pathological examination. Remaining 18 patients were evaluated - these consisted of male 72%, female 28%.

On clinical examination 5 (4 distal +1 proximal stomach) (27.7%) presented with epigastric mass. The site of lesion in 61% (11) was distal stomach, in 33% (6) proximal stomach and 6% (1) involved the whole stomach. Distal stomach carcinoma predominantly was present in males (90.7%) and in the case of proximal stomach carcinoma, males and females were equally affected.

Table 1: Histopathology.

Location of lesion	Gender	Abdominal mass	Histopathology
Distal stomach=11	M=10; F=1	4	MD=5; PD=4; WD=2
Proximal stomach=6	M=3; F=3	1	MD=2; PD=4
Whole stomach=1	M=0; F=1	0	PD=1

Adenocarcinoma with different grades was as follows- moderately differentiated in 38.8% (7) being dominant histology in distal stomach carcinoma, well-differentiated in 11.2% (2) seen only in distal stomach, and poorly differentiated in 50% (9) being the predominant histology in the proximal stomach (Table 1).

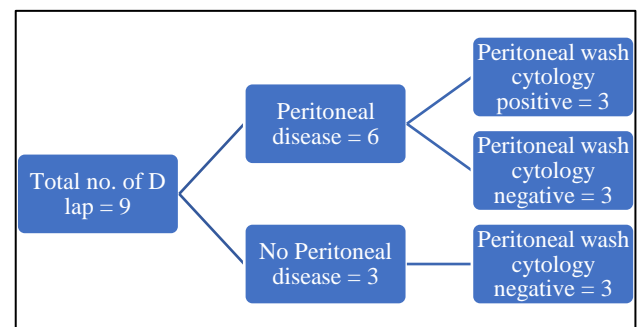


Figure 1: Outcomes of peritoneal wash cytology.

Table 2: Details of perioperative chemotherapy, surgery.

Perioperative chemotherapy	Surgery	Postoperative histopathology	Node ratio (positive /examined nodes)
Carbo+Pacli	D2 distal gastrectomy	pT3N2 (5/18)	5/18
Carbo+Pacli	D2 distal gastrectomy	CPR (13/13)	0/13
Cisp+5FU+LV	D2 distal gastrectomy	pT4aN0 (8/8)	0/8
FLOT	D2 distal gastrectomy	CPR (12/12)	0/12
FLO	D2 distal gastrectomy	pT3N0 (10/10)	0/10
FLOT	D2 distal gastrectomy	pT2N0 (11/11) only small foci of disease present.	0/11

A total of nine patients underwent staging laparoscopy (Figure 1), of which 6 (66.7%) were diagnosed as metastatic disease (peritoneal/liver surface nodules). However, out of these six patients, peritoneal wash cytology was negative for malignancy in 3 (50%) cases. On staging laparoscopy, in three cases findings were non-metastatic disease and all of these peritoneal wash cytology also turned out to be negative for malignant cells.

A total of six patients (Table 2) completed treatment, out of which one patient developed significant vomiting and features of bone marrow suppression on chemotherapy and one patient developed bleeding during laparoscopic dissection of the stomach due to coronary vein injury. The postoperative period was uneventful, Ryle's tube removed on 3rd, and orally allowed on 5th, the drain was removed on the 7th postoperative day. The mean postoperative day of discharge was 12th post-op day. The complete pathological response was seen in two patients (carbo + pacli, FLOT), progressive disease was seen in two patients (FLO, PF), one patient expired (2PF+day one FLOT) due to CVA, one defaulted treatment (Figure 2).

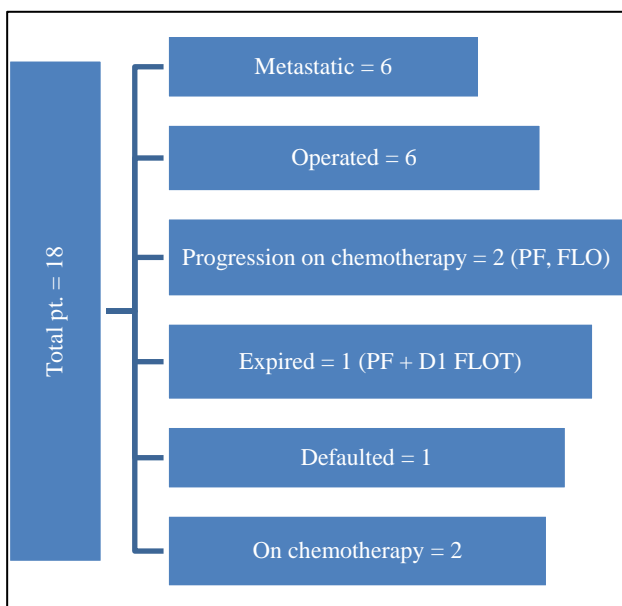


Figure 2: Final short-term outcomes.

DISCUSSION

Gastric cancer is the fifth most common malignancy worldwide and the third leading cause of related cancer death in males.² There is significant global variation in prevalence and mortality rate of gastric cancer, influenced by regional variations in risk factors such as Helicobacter pylori infection and diet.² More than 70% of gastric cancer cases occur in developing countries, and approximately 50% of all cases occur in eastern Asian countries.² Similarly, mortality rates are highest in eastern Asia and lowest in North America.²

Surgical resection in patients with the nonmetastatic disease remains the only curative treatment option for gastric cancer.³ However, recurrence rates after resection remain high, and multimodality treatment strategies incorporating perioperative chemotherapy or chemoradiation are generally recommended.⁴⁻¹⁰ The goal of neoadjuvant therapy is to reduce tumor burden and increase the possibility of R0 resection and to enhance maximum pathological remission because pathological complete response has been shown to correlate with overall survival (OS).⁵ The goal of adjuvant therapy is to reduce microscopic disease and prevent recurrence.³ There is no universally accepted standard regimen for adjuvant therapy. Preferred strategies are typically perioperative chemotherapy in Europe, adjuvant chemoradiation in the USA and adjuvant chemotherapy in Asia.⁶ In European studies, perioperative chemotherapy with triplet or doublet regimens that include a fluoropyrimidine and a platinum agent before and after surgery has been shown to improve R0 resection rates and OS compared with surgery alone. More recently, the AIO FLOT4 study showed the superiority of a perioperative regimen over with epirubicin plus cisplatin plus 5-fluorouracil or capecitabine (ECF/ECX) concerning R0 resection rate, progression-free survival and OS.¹¹ Perioperative chemotherapy therapy is still considered investigational.

Interim analysis of the ongoing trial in our institute reveals the following points.

Patients present with advanced disease in most of the cases in the absence of screening of the population at risk; initially we have given different regimen but now

we have started FLOT regimen for all enrolled patient; Peritoneal wash cytology is significant only when it is positive with low negative predictive value. Negative cytology was associated with a significant number (50%) of patients with metastatic disease; good response and less morbidity to the FLOT regimen reveal that it can be practiced easily in developing countries. Nearly 50% of patients showed an excellent response and probably it may have a positive impact on results when the study is complete and final results are published.

CONCLUSION

This study shows that use of perioperative chemotherapy (FLOT regimen) has positive results in achieving negative resection margin and good pathological response with acceptable morbidity in locally advanced gastric adenocarcinoma. So, addition perioperative FLOT regimen can achieve long term outcome.

ACKNOWLEDGEMENTS

Authors wish to acknowledge the guidance of their teachers, seniors and colleagues of the department of surgical oncology and pathology.

Funding: No funding sources

Conflict of interest: None declared

Ethical approval: The study was approved by the Institutional Ethics Committee (No.296/2019)

REFERENCES

1. Irino T, Sano T, Hiki N, Ohashi M, Nunobe S, Kumagai K, et al. Diagnostic staging laparoscopy in gastric cancer: a prospective cohort at a cancer institute in Japan. *Surg Endosc*. 2018;32:268-75.
2. Ferlay J, Steliarova-Foucher E, Lortet-Tieulent J, Rosso S, Coebergh JW, Comber H, et al. Cancer incidence and mortality patterns in Europe: Estimates for 40 countries in 2012. *Eur J Cancer*. 2013;49:1374-403.
3. Smith DD, Schwarz RR, Schwarz RE. Impact of total lymph node count on staging and survival after gastrectomy for gastric cancer: data from a large US-population database. *J Clin Oncol*. 2005;23:7114-24.
4. Macdonald JS, Smalley SR, Benedetti J, Hundahl SA, Estes NC, Stemmermann GN, et al. Chemoradiotherapy after surgery compared with surgery alone for adenocarcinoma of the stomach or gastroesophageal junction. *N Engl J Med*. 2001;345(10):72530.
5. Cunningham D, Allum WH, Stenning SP, Thompson JN, Van de Velde CJ, Nicolson M, et al. Perioperative chemotherapy versus surgery alone for resectable gastroesophageal cancer. *N Engl J Med*. 2006;355(1):11-20.
6. Chiu CF, Yang HR, Yang MD, Jeng LB, Sargeant AM, Yeh SP, et al. The role of adjuvant chemotherapy for patients with stage II and stage III gastric adenocarcinoma after surgery plus D2 lymph node dissection: a real-world observation. *Springer Plus*. 2016;5:9.
7. Your M, Boige V, Pignon JP, Conroy T, Bouche O, Lebreton G, et al. Perioperative chemotherapy compared with surgery alone for resectable gastroesophageal adenocarcinoma: an FNCLCC and FFCD multicenter phase III trial. *J Clin Oncol*. 2011;29(13):1715-21.
8. Yang YN, Yin X, Sheng L, Xu S, Dong LL, Liu L. Perioperative chemotherapy more of a benefit for overall survival than adjuvant chemotherapy for operable gastric cancer: an updated meta-analysis. *Sci Rep*. 2015;5:12.
9. Al-Batran S-E, Homann N, Schmalenberg H, Kopp H-G, Haag GM, Luley KB, et al. Perioperative chemotherapy with docetaxel, oxaliplatin, and fluorouracil/leucovorin (FLOT) versus epirubicin, cisplatin, and fluorouracil or capecitabine (ECF/ECX) for resectable gastric or gastroesophageal junction (GEJ) adenocarcinoma (FLOT4-AIO): a multicenter, randomized phase 3 trial. *J Clin Oncol*. 2017;35(15 suppl):4004.
10. Cats A, Jansen EPM, van Grieken NCT, Sikorska K, Lind P, Nordmark M, et al. Chemo-therapy versus chemoradiotherapy after surgery and preoperative chemotherapy for resectable gastric cancer (CRITICS): an international, open-label, randomized phase 3 trial. *Lancet Oncol*. 2018;19(5):616-28.
11. Al-Batran SE, Homann N, Pauligk C, Illerhaus G, Martens UM, Stoehlmacher J, et al. Effect of neoadjuvant chemotherapy followed by surgical resection on survival in patients with limited metastatic gastric or gastroesophageal junction cancer: the AIO-FLOT3 trial. *JAMA Oncol*. 2017;3:1237-44.

Cite this article as: Shanmugam S, Kishore P. Resectable locally advanced gastric adenocarcinoma: interim analysis. *Int Surg J* 2020;7:2231-4.