

## Case Report

# Contained rupture of a large right hepatic artery aneurysm: the ticking bomb within!

Byju Kundil<sup>1</sup>, Mano Zac Mathews<sup>2\*</sup>, Tina Tony<sup>2</sup>, Robin Kurian<sup>2</sup>

<sup>1</sup>Department of Surgical Gastroenterology, <sup>2</sup>Department of General Surgery, Pushpagiri Medical College Hospital, Thiruvalla, Kerala, India

**Received:** 21 March 2020

**Accepted:** 24 April 2020

### \*Correspondence:

Dr. Mano Zac Mathews,

E-mail: [dr.manozac@gmail.com](mailto:dr.manozac@gmail.com)

**Copyright:** © the author(s), publisher and licensee Medip Academy. This is an open-access article distributed under the terms of the Creative Commons Attribution Non-Commercial License, which permits unrestricted non-commercial use, distribution, and reproduction in any medium, provided the original work is properly cited.

## ABSTRACT

Hepatic artery aneurysms (HAAs) are rare and represents one fifth of visceral aneurysms. We report a case of a 75 year old female who presented to the outpatient department with complaints of abdominal pain and anorexia for 2 weeks. On examination the patient was stable, she had mild tenderness in the right hypochondrial region. Ultrasound abdomen showed an intrahepatic cystic area with both arterial and venous flow, suggesting the possibility of an intrahepatic arteriovenous malformation. Contrast-enhanced computed tomography abdomen showed a large right HAA with contained rupture and intra hepatic extension. She was posted for emergency laparotomy and was found to have a contained rupture a contained rupture of the right HAA of size 10×8 cm with intra hepatic extension. Right hepatectomy was done and the resected margin of liver showed a dilated cystic space with blood clot. Histopathological examination showed intrahepatic aneurysm with atherosclerosis and laminated luminal thrombus. Contained rupture of HAAs with intrahepatic extension are rare. Even though the prevalence of HAAs is low, the risk of rupture is reported to be as high as 20-80% and the mortality following spontaneous rupture is 40%. Hence an aggressive approach to the management of HAA is required whenever detected.

**Keywords:** Hepatic artery aneurysm, Contained rupture, Right hepatectomy, Atherosclerosis

## INTRODUCTION

True visceral artery aneurysm (VAA) and visceral artery pseudoaneurysm are rare and uncommon with an estimated incidence in autopsies and angiographic series between 0.1% and 2%.<sup>1</sup> Hepatic artery aneurysm (HAA) was first reported in 1809 at an autopsy.<sup>2</sup>

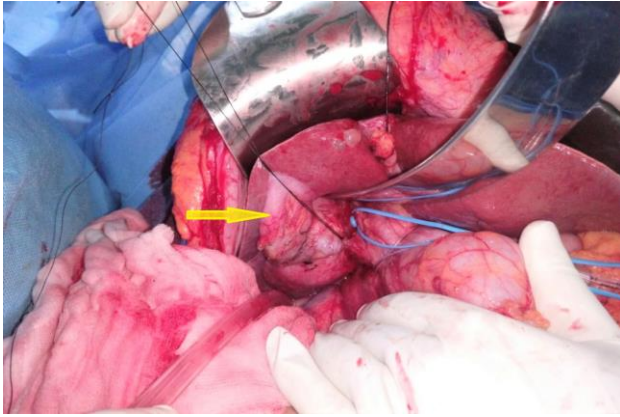
HAAs are rare and represent approximately 20% of all visceral aneurysms with nearly half of all HAAs are pseudo aneurysms resulting from percutaneous biliary interventions.<sup>3</sup> True HAAs are more common in men than in women (male/female ratio of 3:2). Intrahepatic aneurysms are most frequently a result of iatrogenic injury or trauma, whereas extrahepatic aneurysms are usually the result of degenerative or dysplastic diseases.

True aneurysms occur four times more frequently in the extrahepatic arteries, usually involve the common hepatic artery. True visceral artery aneurysms are most commonly associated with atherosclerosis. Splenic artery is the most common site of VAA (60%) followed by hepatic artery (20%), gastroduodenal and pancreaticoduodenal arteries (6%), superior mesenteric artery (SMA 5%), and celiac artery (4%).<sup>3-4</sup>

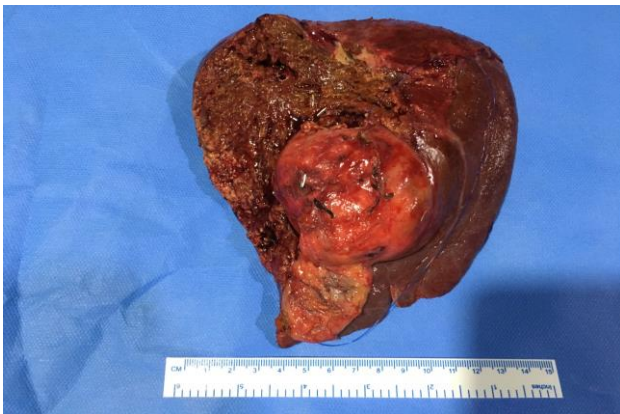The widespread use of ultrasonography and computed tomography has led to increased detection of asymptomatic aneurysms. HAAs can be treated surgically and by endovascular techniques. Treatment depends on the location, size and type of aneurysm. We present a case of large right HAA with contained rupture and intra hepatic extension, which was successfully managed with surgery.



Right lobe appeared to be congested and there was no hemoperitoneum. Right Hepatectomy was done after achieving proximal control and the resected margin of liver showed a dilated cystic space with blood clot (Figure 4). CUSA was used for liver resection. Post-operative period was uneventful and the patient got discharged on post-operative day 7. She is doing well on follow up.



**Figure 3: Intraoperative picture showing the right HAA.**



**Figure 4: Right hepatectomy specimen showing the aneurysm.**

## DISCUSSION

HAAs are the second most common type of VAA (20%), most common being splenic artery aneurysm (60%), with nearly half of all HAAs are pseudo-aneurysms resulting from percutaneous biliary interventions.<sup>5</sup> HAAs include aneurysms of the common, proper, left and right hepatic arteries. It was first described by Wilson in 1809. Reported incidence of HAA is between 0.002-0.4%.<sup>6-7</sup> Currently, the more widespread use of CT angiography and MR angiography has permitted an early diagnosis and thus allowing for the treatment of a large number of asymptomatic lesions and reducing urgent treatment of ruptured aneurysms.<sup>8</sup> The natural history of HAA is poorly understood however the mortality following spontaneous rupture is as high as 40%.<sup>7-8</sup> HAAs are more

commonly associated with atherosclerosis in elderly and congenital syndromes in young patients. Other etiologies include poly arteritis nodosa, mycotic aneurysm, disorders such as Takayasu arteritis, Kawasaki disease, Von Recklinghausen disease, and Wegener granulomatosis.<sup>9,10</sup> Incidence of pseudoaneurysms are increasing, often following percutaneous therapeutic and diagnostic biliary procedures or laparoscopic procedures.<sup>11</sup> Congenital causes include Marfan syndrome, Klippel-Trenaunay syndrome, Ehlers-Danlos syndrome, Osler-Weber Rendu syndrome, and hereditary hemorrhagic telangiectasia.<sup>12</sup>

Intrahepatic aneurysms are most frequently a result of iatrogenic injury or trauma, whereas extrahepatic aneurysms are usually the result of degenerative or dysplastic diseases. HAAs are not initially diagnosed in many cases because the most patients with HAA are asymptomatic until rupture. The most common presenting symptom is epigastric or right upper quadrant pain. Around one third of patients will present with Quinke's triad: abdominal pain, jaundice and haemobilia. Rupture risk of HAAs are as high as 44% and the reported mortality rate following spontaneous rupture is 40-70%.<sup>13,14</sup> Risk factors for complications include multiple HAA or nonatherosclerotic origin, in particular, poly arteritis nodosa.

Ultrasound scan can identify the aneurysm and demonstrate the blood flow within it. CT angiography is useful for detecting small aneurysms and assessing anatomical details. The technique can confirm the diagnosis of HAA, delineates the feeding vessels, depicts collateral blood flow and anatomical variations.<sup>15</sup> Another non-invasive imaging technique is three-dimensional dynamic contrast-enhanced MRI angiography. However selective angiography is the considered as the gold standard, as it provides definitive diagnosis and scope for intervention.<sup>16</sup> Indications for treatment include all symptomatic and ruptured HAAs. Asymptomatic patients with aneurysms larger than 2cm or a rapid growth of more than 0.5cm per year in a patient who is at reasonable operative risk and has a life expectancy of more than 2 years should be intervened.<sup>7,17</sup>

The traditional treatment of HAA has been resection of the aneurysm with preservation of hepatic arterial flow, typically with bypass. With the development of modern endovascular technologies, endovascular treatment has become increasingly popular and they are emerging as an alternative to open surgical repair. Appropriate therapy depends primarily on location of the aneurysm, presence of collateral flow, operative risk, and clinical status. Open surgical treatment options for HAA include ligation, excision, venous grafting, synthetic grafting, and hepatic resection.<sup>7,18</sup> Aneurysms of the common hepatic artery may be safely ligated provided the gastroduodenal artery or pancreaticoduodenal artery is patent providing collateral blood supply to the liver. Aneurysms distal to the common hepatic artery can be treated by



revascularization.<sup>7,13,19</sup> Aneurysms of the common hepatic artery can also be treated by excluding the aneurysm with proximal and distal embolization (isolation with coils). Intra hepatic aneurysms can be treated with resection, ligation, or embolization. With the advent of endovascular techniques intrahepatic branch aneurysms are generally treated with coils, particular embolics, glue, or onyx without serious regard to parenchymal ischemia because of the dual blood supply to the liver. It is of particular value in high risk patients because it limits hepatic devascularization and is associated with lower morbidity. Overall success rates are reported to be between 70 and 100%.<sup>19</sup> Regular follow up is recommended in view of potential complications like hepatic ischemia, hepatic abscess, cholecystitis, and recanalization of the aneurysm.<sup>19</sup> In our case mentioned above, it was a large right HAA with contained rupture and intra hepatic extension. In view of the size and communication with right portal vein branches and decreased enhancement of right lobe liver parenchyma, right hepatectomy was done.

## CONCLUSION

HAAs are rare but may present incidentally or as a cause of severe abdominal pain. So, early diagnosis is essential because the natural tendency of the lesion is to rupture into peritoneal cavity or surrounding organs. Treatment has to be tailored to each patient because of the variability in location. Contained rupture with intrahepatic extension is a rare presentation of HAAs which would have led to a life-threatening situation at any time. Hence an aggressive approach to the management of HAA is required whenever detected. Treatment options include open surgery or endovascular treatment techniques.

*Funding: No funding sources*

*Conflict of interest: None declared*

*Ethical approval: Not required*

## REFERENCES

- Carr SC, Pearce WH, Vogelzang RL, Carthy MWJ, Nemcek AA, Yao JS. Current management of visceral artery aneurysms. *Surgery*. 1996;120(4):627-34.
- Guida PM, Moore SW. Aneurysm of the hepatic artery. Report of five cases with a brief review of previously reported cases. *Surgery*. 1966;60(2):299-310.
- Belli AM, Markose G, Morgan R. The role of interventional radiology in the management of abdominal visceral artery aneurysms. *Cardiovasc Intervent Radiol*. 2012;35:234-43.
- Pulli R, Dorigo W, Troisi N. Surgical treatment of visceral artery aneurysms: a 25 years experience. *J Vasc Surg*. 2008;48:334-42.
- Woj WT. Managing visceral artery aneurysms; Current endovascular techniques and technologies for treating this increasingly encountered presentation. *Endovascular Today*. 2013;77-81.
- Arneson MA, Smith RS. Ruptured hepatic artery aneurysm: case report and review of literature. *Ann Vasc Surg*. 2005;19:540-5.
- Abbas MA, Fowl RJ, Stone WM, Panneton JM, Oldenburg WA, Bower TC, et al. Hepatic artery aneurysm: Factors that predict complications. *J Vasc Surg*. 2003;38:41-5.
- Marone EM, Mascia D, Kahlberg A, Brioschi C, Tshomba Y, Chiesa R. Is open repair still the gold standard in visceral artery aneurysm management. *Ann Vasc Surg*. 2011;25(7):936-46.
- Bakker DMA, Tangkau PL, Steffens TW, Tjiam L, Loo VEM. Rupture of a hepatic artery aneurysm caused by Wegener's granulomatosis. *Pathol Res Pract*. 1997;193:61-6.
- Khodja HR, Declémy S, Batt M, Castanet J, Perri C, Ortonne JP, et al. Visceral artery aneurysms in von Recklinghausen's neurofibromatosis. *J Vasc Surg*. 1997;25:572-5.
- Tulsyan N, Kashyap VS, Greenberg RK. The endovascular management of visceral artery aneurysms and pseudoaneurysms. *J Vasc Surg*. 2007;45(2):276-83.
- Cooper SG, Richman AH. Spontaneous rupture of a congenital hepatic artery aneurysm. *J Clin Gastroenterol*. 1988;10:104-7.
- Baggio E, Migliara B, Lipari G, Landoni L. Treatment of six hepatic artery aneurysms. *Ann Vasc Surg*. 2004;18:93-9.
- Wagner WH, Allins AD, Treiman RL, Cohen JL, Foran RF, Levin PM, et al. Ruptured visceral artery aneurysms. *Ann Vasc Surg*. 1997;11:342-7.
- Shanley CJ, Shah NL, Messina LM. Common splanchnic artery aneurysms: splenic, hepatic, and celiac. *Ann Vasc Surg*. 1996;10(3):315-22.
- Arneson MA, Smith RS. Ruptured hepatic artery aneurysm: case report and review of literature. *Ann Vasc Surg*. 2005;19:540-5.
- Regus S, Lang W. Rupture Risk and Etiology of Visceral Artery Aneurysms and Pseudo aneurysms: A Single-Center Experience. *Vascular Endovascular Surg*. 2016;50(1):10-15.
- Andrew DR, Vive JU, Macpherson DS. Successful resection of a massive hepatic artery aneurysm. *J R Army Med Corps*. 1994;140:138-40.
- Lumsden AB, Mattar SG, Allen RC, Bacha EA. Hepatic artery aneurysms: the management of 22 patients. *J Surg Res*. 1996;60:345-50.

**Cite this article as:** Kundil B, Mathews MZ, Tony T, Kurian R. Contained rupture of a large right hepatic artery aneurysm: the ticking bomb within!. *Int Surg J* 2020;7:2403-6.