

Original Research Article

Stump appendicitis single centre experience: a retrospective study

Imran A. Khan*, Parthasarathi Ramakrishnan, Rajapandian Subbaiah,
Senthilnathan Palanisamy, Nalankilli Palanisamy, Senthil K. Ganapathi,
Bharath K. Murugan, Chinnusamy Palanivelu

Department of GI and Minimal Access Surgery, Gem Hospital and Research Centre, Coimbatore, India

Received: 18 March 2020

Revised: 14 April 2020

Accepted: 15 April 2020

***Correspondence:**

Dr. Imran A. Khan,

E-mail: drimran0918@yahoo.in

Copyright: © the author(s), publisher and licensee Medip Academy. This is an open-access article distributed under the terms of the Creative Commons Attribution Non-Commercial License, which permits unrestricted non-commercial use, distribution, and reproduction in any medium, provided the original work is properly cited.

ABSTRACT

Background: Appendectomy is the most common surgical procedure done for acute appendicitis worldwide. However, one among 50000 appendectomy patients may present with recurrent abdominal pain, requiring hospitalization as stump appendicitis and may need completion appendectomy. There are a few reports addressing management of stump appendicitis in the literature. Here we present our experience of laparoscopic completion appendectomy over ten-year duration.

Methods: A retrospective evaluation of records of appendectomy from January 2008 to December 2018. All patients who had stump appendicitis as diagnosis and those who underwent completion appendectomy were included. There were no exclusions. Details pertaining to presentation, duration of symptoms, records of previous surgery, perioperative and postoperative data was recorded, including follow-up of at least six months.

Results: All 15 patients were managed by laparoscopic completion appendectomy. Patients age range from 12 to 58 years, 12 were males and 3 female, duration of symptoms was from two to ten days, previous appendectomy was done 4 to 84 months before, nine were diagnosed by ultrasonography of abdomen and six by CT scan, stump size ranged from 1 to 3.6 cm, mean operating time was 86.4 mins (range, 60-120 minutes). Duration of hospital stay was 3 to 5 days. There were no perioperative morbidity or mortality.

Conclusions: Laparoscopic approach of completion appendectomy is safe for management of stump appendicitis.

Keywords: Stump, Appendicitis, Completion appendectomy, Remnant appendix

INTRODUCTION

Stump appendicitis is defined as the inflammation of remnant appendix after incomplete appendectomy.¹ A common reason for incomplete appendectomy is a failure to identify the base of the appendix. This residual appendiceal tissue remains as a potential region for inflammation and even can lead to complications like abscess formation, peritonitis, and intestinal obstruction. The diagnosis is usually delayed in view of prior history of appendectomy, which contributes to increased morbidity. Stump appendicitis is rare and occurs in about

1 per 50000 cases.² We offer to share our experience of this relatively uncommon disorder over a decade.

METHODS

This was a retrospective study of all patients who underwent completion appendectomy from January 2008 to December 2018, performed at a tertiary care teaching hospital. All patients who had stump appendicitis as diagnosis and those who underwent completion appendectomy were included. Details of patient's presentation, duration of symptoms, records of previous surgery, investigations, imaging, type of

surgical procedure done, perioperative and postoperative complications, including follow-up of at least six months was collected from institutional registry. After proper preoperative preparation surgery was done.

In all cases pneumoperitoneum created with Veress needle at epigastrium, initially 5 mm optical port was placed at same site and diagnostic laparoscopy was done, 7mm optical port at the umbilicus and 5 mm working ports each at suprapubic region and right iliac fossa were placed, in some patients bilateral subcostal ports were placed for adhesiolysis before conventional ports. Adhesiolysis was done using a harmonic scalpel (Figure 1 and 2), pus collections were drained (Figure 3), the stump of the appendix identified (Figure 4), mesentery of stump divided with harmonic and completion appendicectomy done after ligating base of the appendix with two self-made 1-0 chromic endoloops (Figure 5), the specimen was taken out through umbilical port.

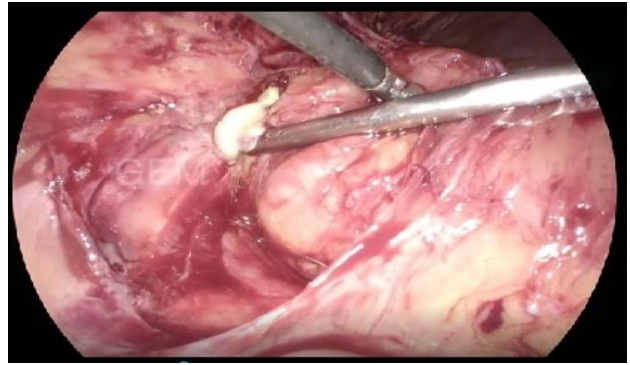


Figure 3: Pus collection being drained.

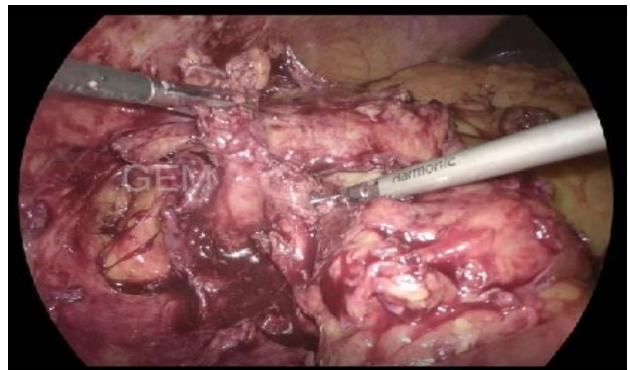


Figure 4: Identifying appendicular stump.

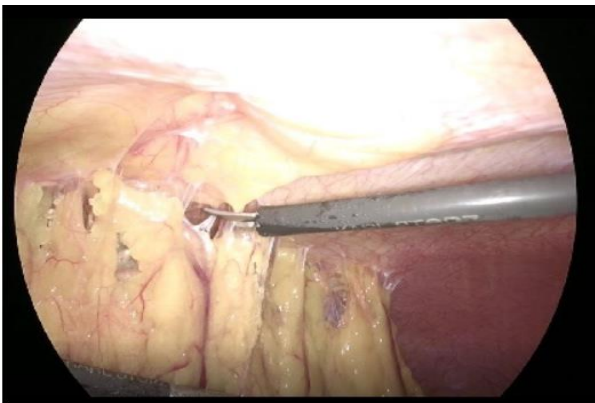

Figure 1: Omental adhesiolysis.

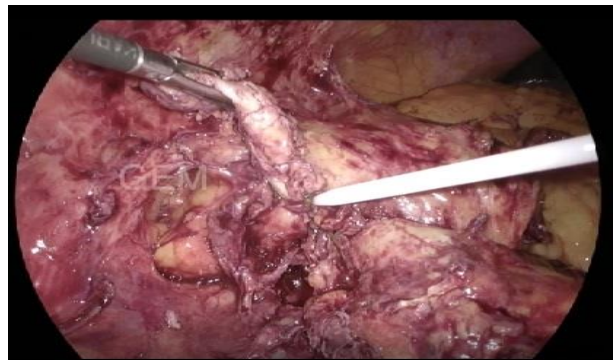

Figure 5: Stump ligation being done.

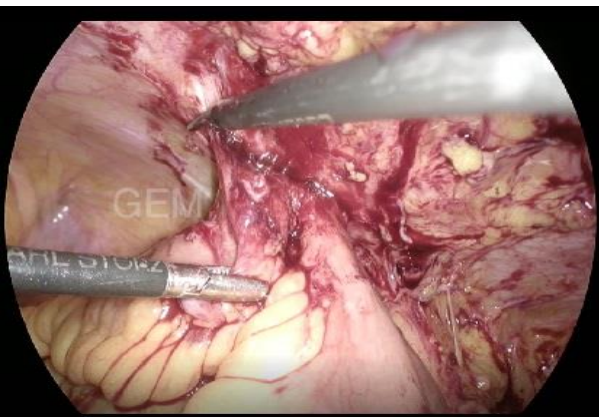


Figure 2: Bowel adhesiolysis.

Statistical analysis

The recorded data was compiled and entered in a spreadsheet (microsoft excel) and then exported to data editor of SPSS version 20.0. Continuous variables were expressed as mean \pm SD and categorical variables were summarized as frequencies and percentages.

RESULTS

Patient’s age ranges from 12 to 58 years, there were more males than females. All patients had undergone appendicectomy at other institutions before our review (Table 1).

Table 1: Patients demographics.

Number of patients	15
Age	12-58 years
Sex	Males=12, Females=3
Appendicectomy	4-84 months before
Surgical approach	Laparoscopic=11, Open=4

Table 2: Investigations.

Investigation	Findings	Number of patients
Total leucocyte count	5010-21500 cells/mm ³	
Ultrasonography	Thickened inflamed appendicular stump	9
	Appendicular stump not seen	6
	Collection in right iliac fossa and pelvis	7
CECT Abdomen and Pelvis	Inflamed and thickened appendicular stump	6

Patients presented to us with pain abdomen ranging from 2 to 10 days. Blood and radiological investigations (Table 2) were suggestive of stump appendicitis and its complications (Figure 6 and 7).

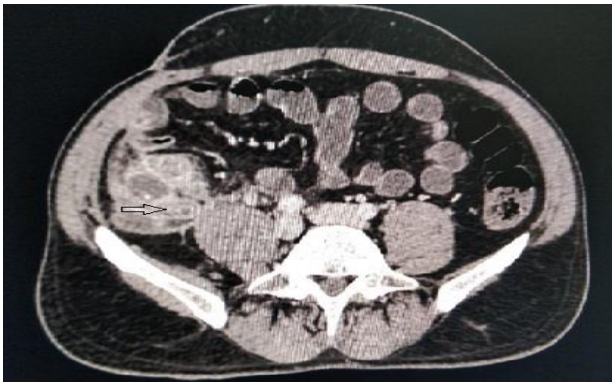

Figure 6: Axial view CECT abdomen showing inflamed appendicular stump.

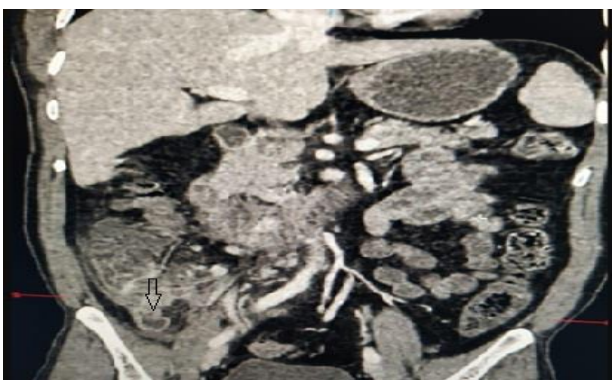


Figure 7: Coronal view CECT abdomen showing inflamed appendicular stump.

All cases underwent laparoscopic completion appendicectomy. In seven patients drain was placed in pelvis. There were adhesions of omentum and small bowel to previous appendicectomy scar, pus collection in right iliac fossa and pelvis, stump size was significant and

mean operating time was 86.4 minutes (range, 60-120 minutes) (Table 3). There were no perioperative morbidity or mortality. Drain was removed over an average of 2.5 days. Duration of hospital stay was 3 to 5 days. Histopathology revealed a different degree of inflammation in the stump, varying from submucosal inflammation to appendicitis with serositis. All patients were doing well at 1 and six months.

Table 3: Pre-operative findings.

Findings	Number of patients/stump size in cms/operative time in minutes
Adhesions	5
Pus collection in right iliac fossa and pelvis	7
Stump size	1-3.6 cm
Mean operating time	86.4 minutes

DISCUSSION

Laparoscopic appendicectomy is the most common emergency procedure done for acute appendicitis, and most of such procedures have an uneventful postoperative period.¹ Postoperative complications of appendicectomy may include wound infection, pelvic abscess, peritonitis, fecal fistulas and adhesive obstruction. However, if the appendicular stump is longer, it can get inflamed in future and result in what is known as stump appendicitis. Stump appendicitis is rare and occurs in about 1 per 50000 cases.² It can be seen after both open and laparoscopic appendicectomy.^{3,4} The reasons for leaving a longer stump could be either anatomical (retro-cecal or subserosal appendix, or developmental like a duplicated appendix) or surgical (difficulty to find base due to severe local inflammation, difficult dissection or fear of bowel injury).⁵⁻⁷ There is a challenge in diagnosis once patient present with features of appendicitis, with the previous history of appendectomy, that results in delayed diagnosis and increased morbidity and mortality.⁸ One should have a high degree of suspicion in such cases, to get them diagnosed and operated at earliest.

Manoglu et al described a patient with cecal necrosis secondary to stump appendicitis who was referred to the hospital twice with complaints of abdominal pain.⁹ In our study patients were diagnosed and operated within 48 hours (5 patient was operated on the day of admission, 7 patients within 24 hours and 3 patient within 48 hours). In seven of our cases there were pus collections in right iliac fossa and pelvis, however no significant complications were encountered.

Kanona et al found that the time taken for stump appendicitis to develop in patients with inadequate appendectomy ranged from 9 weeks to 50 years.¹⁰ Under

et al, conducted two case studies and found that a history of appendectomy was four months back in one patient and four years in the other patient.¹¹ In our research earliest time to develop stump appendicitis was four months, and the longest was seven years.

Symptoms and signs of stump appendicitis are same as that of acute appendicitis. It is radiological investigations that help us in reaching a diagnosis. USG can detect remnant appendix as a tube extending from the right iliac fossa or retro-cecal region.^{12,13} CT would reveal inflammation in the peri-cecal region, abscesses, thickening of the cecum or terminal ileum, and free-floating fluid at the peri-cecal or paracolic region.¹⁴⁻¹⁶ In our study, nine patients were diagnosed by USG and rest six by CT abdomen and findings were a varied length of the appendicular stump with inflammation along with iliac fossa and pelvic collections in some patients. There is no standardized surgical approach for stump appendectomy; both open and laparoscopic methods can be done however the laparoscopic approach provides a better viewing angle.¹⁷ All our patients underwent laparoscopic completion appendectomy with uneventful perioperative and postoperative period and were doing well on follow up.

CONCLUSION

Laparoscopic approach of completion appendectomy is safe for management of stump appendicitis and can be done, however it needs surgical expertise.

Funding: No funding sources

Conflict of interest: None declared

Ethical approval: Not required in view of retrospective study

REFERENCES

- Anderson KD, Parry RL. Appendicitis. In: O'Neill JA, Rowe MI, Grosfeld JL, Fonkalsurd EW, Coran AG, editors. Pediatric surgery. 5th ed. London: Mosby; 1998:1369-1379.
- Liang MK, Lo HG, Marks JL. Stump appendicitis: a comprehensive review of literature. Am Surg. 2006;72:162-6.
- Greenberg JJ, Esposito TJ. Appendicitis after laparoscopic appendectomy: A warning. J Laparoendosc Surg. 1996;6:185-7.
- Uludag M, Isgor A, Basak M. Stump appendicitis is a rare delayed complication of appendectomy: A case report. World J Gastroenterol. 2006;12:5401-3.
- Clark J, Theodorou N. Appendicitis after appendectomy. J R Soc Med. 2004;97:543-4.
- Durgun AV, Baca B, Ersoy Y, Kapan M. Stump appendicitis and generalized peritonitis due to incomplete appendectomy. Tech Coloproctol. 2003;7:102-4.
- Mangi AA, Berger DL. Stump appendicitis. Am Surg. 2000;66:739-41.
- Truty MJ, Stulak JM, Utter PA, Solberg JJ, Degnim AC. Appendicitis after appendectomy. Arch Surg. 2008;143:413-5.
- Manoglu B, Niflioglu GG, Uysal E. A rare case: appendectomy after connected stump appendicitis perforation of the cecum. J Clin Anal Med. 2015;6(4):539-41.
- Kanona H, Samarae AA, Nice C, Bhattacharya V. Stump appendicitis: a review. Int J Surg. 2012;10(9):425-8.
- Onder A, Kapan M, Boyuk A, Tekbas G, Gumus M. Stump appendicitis after appendectomy. Kolon Rektum Hast Derg. 2010;20(4):188-91.
- Leary ODP, Myers E, Coyle J, Wilson I. Case report of recurrent acute appendicitis in a residual tip. Cases J. 2010;3:14.
- Baldisserotto M, Cavazzola S, Cavazzola LT, Lopes MHI, Mottin CC. Acute edematous stump appendicitis diagnosed preoperatively on sonography. AJR Am J Roentgenol. 2000;175:503-4.
- Shin LK, Halpern D, Weston SR, Meiner EM, Katz DS. Prospective CT diagnosis of stump appendicitis. AJR Am J Roentgenol. 2005;184:62-4.
- Erzurum VZ, Kasirajan K, Hashmi M. Stump appendicitis: a case report. J Laparoendosc Adv Surg Tech A. 1997;7(6):389-91.
- Rao PM, Sagarin MJ, Cabe MCJ. Stump appendicitis diagnosed preoperatively by computed tomography. Am J Emerg Med. 1998;16(3):309-11.
- Roberts K, Starker L, Duffa A, Bell R, Bohkari J. Stump appendicitis: a surgeon's dilemma. JSLS. 2011;15(3):373-8.

Cite this article as: Khan IA, Ramakrishnan P, Subbaiah R, Palanisamy S, Palanisamy N, Ganapathi SK, et al. Stump appendicitis single centre experience: a retrospective study. Int Surg J 2020;7:1899-902.