

## Original Research Article

# Video assisted thoracoscopic surgery in the management of acute fibrinopurulent empyema in paediatric patients

Arti S. Mitra<sup>1</sup>, Nilesh G. Nagdeve<sup>2\*</sup>, Simran R. Khatri<sup>1</sup>, Unmed A. Chandak<sup>1</sup>

<sup>1</sup>Department of Surgery, Government Medical College Nagpur, Maharashtra, India

<sup>2</sup>Department of Paediatric Surgery, Government Medical College Nagpur, Maharashtra, India

**Received:** 04 March 2020

**Accepted:** 09 April 2020

**\*Correspondence:**

Dr. Nilesh G. Nagdeve,

E-mail: [nileshngn74@yahoo.co.in](mailto:nileshngn74@yahoo.co.in)

**Copyright:** © the author(s), publisher and licensee Medip Academy. This is an open-access article distributed under the terms of the Creative Commons Attribution Non-Commercial License, which permits unrestricted non-commercial use, distribution, and reproduction in any medium, provided the original work is properly cited.

### ABSTRACT

**Background:** Empyema is the presence of pus in the pleural space that usually follows an episode of pneumonia in pediatric age group. The aim of this study was to assess the efficacy of management of acute fibrinopurulent stage of empyema by early video assisted thoracoscopic surgery (VATS) in paediatric patients.

**Methods:** The study was carried out at a tertiary care hospital in India. It was a prospective interventional observational study. The study included 40 children between age group 0-12 years attending the surgery in-patient department referred for further management of parapneumonic effusions who had clinical and radiological evidence of empyema and thoracentesis confirmed purulent exudate in pleural cavity, were subjected to early VATS after thorough pre-operative workup.

**Results:** The mean age was 7.22 years. Average operative time was 135.5 minutes. The mean duration of hospital stay was 7.5 days. Few complications were bleeding, superficial wound infection, bronchopleural fistula, pneumothorax, recurrence of empyema and incomplete expansion of lung.

**Conclusions:** VATS facilitates the management of fibrinopurulent and organised pyogenic pleural empyema with less post-operative discomfort and complications and reduced hospital stay. However larger sample size study is required to come to a definitive conclusion.

**Keywords:** Empyema, Hospital stay, Paediatric, VATS

### INTRODUCTION

Empyema is the presence of pus in the pleural space that usually follows an episode of pneumonia in pediatric age group. The reported incidence of this condition is 3.3 per 100,000 children.<sup>1</sup> Empyema has classically been divided into 3 stages.<sup>2</sup>

Stage 1 (exudative phase) generally responds to antibiotic therapy.<sup>3</sup> Stage 3 (organization phase) is managed by open thoracotomy and decortication in most cases.<sup>4</sup> Stage 2, the fibrino purulent phase: antibiotics penetrates the empyema cavity poorly due to loculations and are of little

use without adequate drainage and debridement. Various modalities of treatment include tube thoracostomy with or without fibrinolytic injection into the pleural cavity, video assisted thoracoscopic surgery (VATS) for drainage or open thoracotomy and decortication.<sup>5,6</sup> It is likely that thoracoscopic decortication has its most appropriate role in early surgery as the failure rate is higher in advanced organized empyema, which then leads to the need for later open thoracotomy and drainage.

With this background, the present study was planned to assess the efficacy of VATS in fibrinopurulent stage of acute empyema in paediatric patients.

## METHODS

The study was a prospective observational interventional study which included children from 0-12 years of age, attending surgery OPD or casualty for further management of parapneumonic effusions with clinical history suggestive of acute lower respiratory tract infections along with radiographic evidence of empyema (on chest X-ray and ultrasound) and symptoms persisting even after receiving 24 hours of parenteral antibiotic treatment and findings on thoracocentesis confirmed purulent exudate in pleural cavity. The study was conducted for 2 years from 2017-2019. The ethical approval was granted by institutional ethics committee. A total of 40 study participants were selected based on the inclusion/ exclusion criteria. Patients were subsequently enrolled in this study only after obtaining consent from the patient's parents /guardian.

### Inclusion criteria

Patients under the age of 12 years, Patients with clinical history suggestive of acute lower respiratory tract infections and symptoms persisted even after receiving 24 h of parenteral antibiotic treatment, patients having radiographic evidence of empyema (i.e., pleural fluid on chest X-ray) with sonographic findings of hyperechoic fluid with or without thin septation and thoracocentesis suggestive of purulent exudate and findings of exudate on microscopy and biochemical analysis.

### Exclusion criteria

Cases of organized empyema diagnosed on the basis of duration and radiographic and sonographic evidence of well-formed loculations, known immunodeficiency, recurrent empyema, patients with associated known complications like bronchopleural fistula, patients above 12 years of age and with tuberculous empyema were excluded.

### Preoperative work up

Each patient had blood culture, haemoglobin, white blood cell (WBC) and differential counts, platelet count, coagulation profile, C-reactive protein (CRP), electrolytes, albumin, X-ray chest, and chest ultrasound scan (USS)

*X-ray chest:* Chest X-rays were assessed for the following four parameters: pleural thickening, parenchymal changes, lung expansion and scoliosis.


*USS:* Empyema was categorized into three grades based on the appearance of pleural fluid on ultrasonography.

- Grade 1- Anechoic nonseptated fluid
- Grade 2- Hyperechoic fluid with fibrinous septation
- Grade 3- Hyperechoic loculations with or without thick parietal peel.

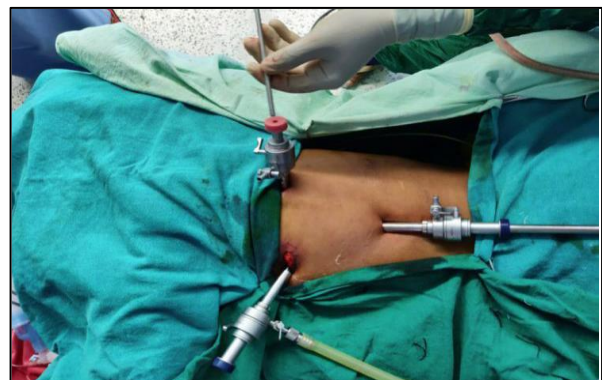Diagnostic thoracocentesis was done in all children after written informed consent.

### Operative procedure

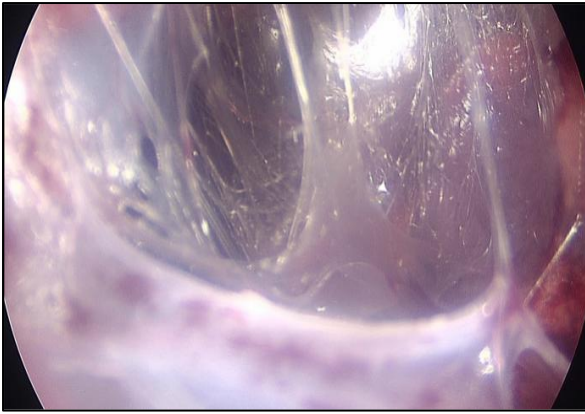
VATS was performed under general anaesthesia, with dual lung ventilation and with the patient in a lateral position. Two 5 mm ports were used in all patients. A primary port was placed through the fifth or sixth intercostal space (ICS) in the mid-clavicular line, through which a zero degree wide angle scope was introduced. The CO<sub>2</sub> insufflation pressure was maintained between 3-6 mmHg at a flow rate of 1 l/min. The placement of a second port was based on thoracoscopic findings. Initial dissection and creation of space was achieved by CO<sub>2</sub> insufflation and adhesions were released with the tip of the scope or tip of the suction cannula under vision. The fluid was sucked out and the peel was removed with a Maryland dissector. Sometimes long open surgical instruments were passed directly through the ports and aided in the removal of the peel. An ICD was placed through the camera port before closure of the ports. Postoperatively the patients were monitored in the recovery ward for 6-12 hours (Figures 1-4).



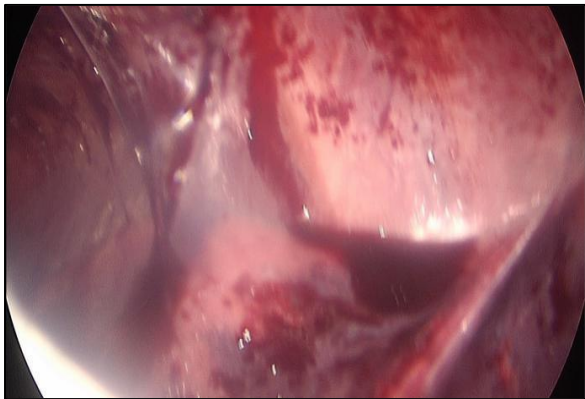
**Figure 1: The laparoscopy (thoracoscopy) trolley.**



**Figure 2: Port position in VATS.**



**Figure 3: Thoracoscopic view before decortication.**



**Figure 4: Thoracoscopic view after decortication.**

Once enrolled in the study, the subjects were subjected to VATS and were observed for post-operative improvement and clinical course. Each patient was assessed for symptoms of fever, cough, breathlessness, exercise intolerance, poor appetite, abdominal pain, fetor oris (halitosis), lethargy and malaise. Each of the symptoms was assessed in detail with emphasis on exact duration of that symptom.

#### **Outcome measures**

The main outcome studied was the number of days in hospital, was calculated from the date of procedure to the date of discharge. Secondary end points were number of days with chest drainage, failure rate of assigned treatment, complications, chest X- ray (CXR) changes at 3 months after intervention. CXRs (postero-anterior views) were performed at 3 months after intervention.

## **RESULTS**

The study subjects belonged to 0-12 years of age, with maximum incidence in 6-8 years of age. Clinically the children presented with features of pneumonia such as fever, cough and difficulty in breathing. They also had features like exercise intolerance, poor appetite, abdominal pain, fetor oris (halitosis), lethargy and

malaise. Older children complained of chest pain on the side of effusion. Refusal to feed was commonly observed in young children (Table 1). It was observed that the mean duration of illness of the participants before surgery was  $7.97 \pm 2.33$  days.

**Table 1: Distribution of study subjects according to clinical presentation.**

Symptoms	Frequency	Percentage
<b>Fever</b>	33	82.5
<b>Dyspnoea</b>	36	90
<b>Cough</b>	25	62.5
<b>Chest pain</b>	17	42.5
<b>Abdominal pain</b>	7	17.5
<b>Refusal to feed</b>	12	30

It was observed that majority of the study subjects presented with grade II empyema (70%), followed by 27.5% cases presented with grade III empyema (as seen on USS). Only 2.5% cases presented with grade I empyema. The pleural fluid aspirated was subjected to microscopy, majority of the study subjects presented with pus cells (97.5%) (Table 2). Majority (50%) of cases were negative on microbiological analysis of pleural fluid (Table 3).

**Table 2: Pre-operative diagnostic pleural fluid microscopic analysis.**

Microscopic features	Frequency	Percentage
<b>Pus cells</b>	39	97.5
<b>Red blood cells</b>	25	62.5
<b>Gram positive cocci in cluster</b>	14	35
<b>Gram positive cocci in chains</b>	7	17.5
<b>Gram negative cocci</b>	3	7.5
<b>Gram negative rods</b>	2	5

**Table 3: Microbiological analysis of pleural fluid.**

Culture	Frequency	Percentage
<b>Negative</b>	20	50
<b>Coagulase +Ve Staph</b>	6	15
<b>Strep. Pyogens</b>	4	10
<b>Pneumococci</b>	3	7.5
<b>H. influenza</b>	2	5
<b>Other</b>	2	5

In present study, the intra operative period was uneventful. No major intra-operative complications were seen. Average operative time was 135.5 minutes. No blood transfusions were required in the intra-operative period. Amount of pus and debris drained was 175 ml on an average. Average duration of hospital stay was 7.5 days. Other parameters were as shown in Table 4.

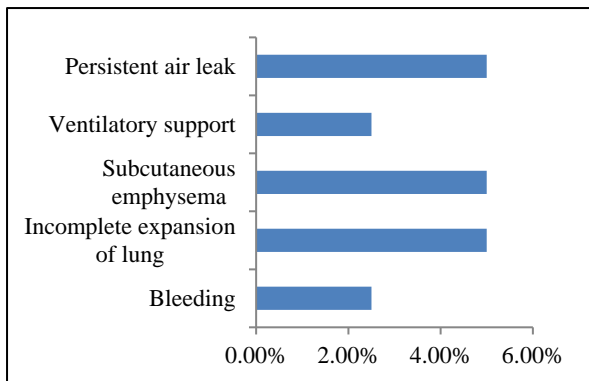
**Table 4: Post-operative ventilatory support.**

Post-operative findings	Mean value (in days)	Standard deviation
Oxygen need	2.15	0.66
Duration to normalise fever	3.07	1.66
Duration to normalise TLC	5.35	1.56
Duration of analgesic required	4.52	1.39
Asymptomatic period	4.1	1.56
Duration of ICD	5.55	1.58
Hospital stay	7.57	1.35

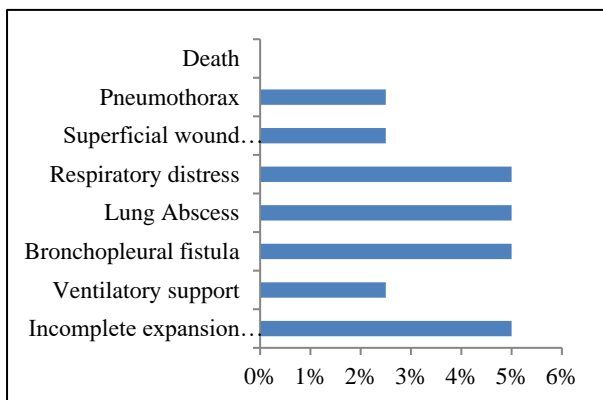
**Post-operative complications**

*Early post-operative complications:* This duration is considered as the duration up to three days (72 hours) post intervention (Figure 5).

*Late post-operative complications:* This duration is considered as the duration after three days (72 hours) post intervention (Figure 6). On follow up, chest X-ray (antero-posterior views) were done on post-operative day 15, 1 month and 3 months. There was significant improvement in Chest X-ray findings as depicted (Table 5).



**Figure 5: Early complications.**



**Figure 6: Late complications.**

**Table 5: Chest X-ray findings on follow up.**

Resolution of CXR findings	On day 15	At 1 month	At 3 month
Pleural effusion	0	0	1
Parenchymal changes	5	6	1
Pleural thickening	12	8	3
Lung expansion	14	5	2
Scoliosis	16	4	1

**DISCUSSION**

The mean age of the study subjects in the present study was 7.22±2.64 years. The commonest clinical presentation was dyspnea, followed by fever and cough. Our findings were consistent with the observations of Arya et al who reported fever (94%), cough (96%), breathlessness (48%) and chest pain (27%) as the presenting complaints.<sup>10</sup> The most common findings on clinical examinations were crepitations (80%) and diminished respiratory movements (100%). In the study of Obanoglu et al most common symptom was respiratory distress 87%, cough 83% and fever was present in 64% children.<sup>7</sup> The mean duration of illness before surgery of study participants was 7.97±2.33 days. In a study done by Sonnappa et al, the mean duration of illness prior to admission in VATS group was 9 (2-37) days.<sup>9</sup>

The majority of the study subjects presented with grade II empyema, followed by grade III empyema. It was observed that majority of the cases were negative bacteriologically, 15% cases presented with coagulase positive *staphylococci*, while 10% cases presented with *Streptococcus pyogenes*. These results were slightly different than the microbiological data of previous study done by Sonnappa et al which showed seven (23%) patients in each of the groups had positive blood or pleural fluid cultures.<sup>8</sup> 47 (78%) of the pleural fluid samples were analyzed and cultured. Of these 27 (45%) were positive for fully penicillin- sensitive *Streptococcus pneumoniae*. In a study of 150 cases of empyema done by Das et al, pus culture was positive in 32% (48 cases) with *Streptococcus pneumoniae*- commonest organism isolated (31 cases, 64.6%) followed by *Staphylococcus aureus* (11 cases, 22.9%), *Klebsiella pneumonia* (3 cases, 6.3%), *Haemophilus influenzae* type b (2 cases, 4.2%) and *Enterococcus* (1 case, 2%).<sup>9</sup>

In follow up chest X-ray findings, pleural thickening, lung expansion and scoliosis was corrected considerably among the cases at the end of 3 months follow up.

In a study of Sonnappa et al total of 16 patients were lost to follow-up at 6 months, and CXRs at 6 months after intervention were performed in 44 patients (24 in the VATS arm). Thirty-nine (88.6%) of the patients had abnormal CXRs.<sup>8</sup>

## CONCLUSION

The study demonstrates VATS as a feasible approach for the management of stage II empyema. VATS facilitates the management of fibrinopurulent and organized pyogenic pleural empyema with less post-operative discomfort and complications and reduced hospital stay. However, a larger sample size study is required to come to a definitive conclusion.

*Funding: No funding sources*

*Conflict of interest: None declared*

*Ethical approval: The study was approved by the Institutional Ethics Committee*

## REFERENCES

1. Menon P, Kanojia RP, Rao KLN. Empyema thoracis: surgical management in children. *J Indian Asso Pedia Surg.* 2009;14(3):85-93.
2. Gocmen A, Kiper N, Toppare M, Ozcelik U, Cengizlier R, Cetinkaya F. Conservative treatment of empyema in children. *Respiration.* 1993;60:182-5.
3. Satish B, Bunker M, Seddon P. Management of thoracic empyema in childhood: does the pleural thickening matter? *Arch Dis Child.* 2003;88:918-21.
4. Coote N, Kay E. Surgical versus non-surgical management of pleural empyema. *Cochrane Database Syst Rev.* 2005;4:CD001956.
5. Aydogan M, Aydogan A, Ozcan A, Tugay M, Gokalp AS, Arisoy ES. Intrapleural streptokinase treatment in children with empyema. *Eur J Pediatr.* 2008;167:739-44.
6. Fuller MK, Helmrath MA. Thoracic empyema, application of video-assisted thoracic surgery and its current management. *Curr Opin Pediatr.* 2007;19:328-32.
7. Cobanoglu U, Sayir F, Bilici S, Melek M. Comparison of the methods of fibrinolysis by tube thoracostomy and thoracoscopic decortication in children with stage II and III empyema: a prospective randomized study. *Pediatr Rep.* 2011;3(4):29.
8. Sonnappa S, Cohen G, Owens CM. Comparison of urokinase and video-assisted thoracoscopic surgery for treatment of childhood empyema. *Am J Respir Crit Care Med.* 2006;174:221-7.
9. Hazarika D, Deka R, Barman N, Duwarah H, Khyriem S, Saikia A, et al. Empyema thoracis: analysis of 150 cases from a tertiary care centre in north east India. *Indian J Pediatr.* 2011;78:1371-7.
10. Arya LS, Khalqyi AZ, Fazel MI. A study of empyema thoracis in children. *Ind Pediatr.* 1982;19:917-21.

**Cite this article as:** Mitra AS, Nagdeve NG, Khatri SR, Chandak UA. Video assisted thoracoscopic surgery in the management of acute fibrinopurulent empyema in paediatric patients. *Int Surg J* 2020;7:1847-51.