

## Original Research Article

# Single centre randomized comparative trial of lateral internal sphincterotomy versus 2% diltiazem in chronic anal fissure

**Hariharan Sritharan\***, Naren Kumar Ashok Kumar, Mohamed Ismail Syed Ibrahim M. S.

Department of General Surgery, Shri Sathya Sai Medical College & Research Institute, Sri Balaji Vidyapeeth (Deemed to be University), Tirupurur, Ammapettai, Kancheepuram District, Tamil Nadu, India

**Received:** 28 February 2020

**Revised:** 07 May 2020

**Accepted:** 08 May 2020

### \*Correspondence:

Dr. Hariharan Sritharan,

E-mail: [haridsurgeon@gmail.com](mailto:haridsurgeon@gmail.com)

**Copyright:** © the author(s), publisher and licensee Medip Academy. This is an open-access article distributed under the terms of the Creative Commons Attribution Non-Commercial License, which permits unrestricted non-commercial use, distribution, and reproduction in any medium, provided the original work is properly cited.

## ABSTRACT

**Background:** Anal fissures are often encountered in surgical practice with surgery the gold standard management for chronic anal fissures. Recently the widespread use of pharmacologic agents for chronic fissures has increased. In our study we compare topical 2% diltiazem with lateral sphincterotomy with respect to symptoms such as relief of pain, ulcer healing, and side effects of treatments.

**Methods:** A prospective comparative study, a total of 80 patients were randomized into 2 groups 40 each. Group A patients were subjected to open internal lateral sphincterotomy and group B to 2% topical diltiazem. The patients in both groups were followed up at 1<sup>st</sup>, 4<sup>th</sup>, 14<sup>th</sup> weeks and 6 months in OPD and were assessed for pain, sphincter tone and complications.

**Results:** In group A (lateral anal sphincterotomy), patients achieved a good pain relief with a mean pain score of 1.98 by one week post procedure whereas group B (2% diltiazem) had taken 14 weeks to achieve similar pain relief (pain score of 1.5). At the end of 6 months, healing of fissure was noted in 100% of group A and in 90% of group B. 4 patients (10%) had recurrences in group B. Flatus incontinence was reported in 2 patients (5%) in group A although transient.

**Conclusions:** Lateral anal sphincterotomy is superior to 2% diltiazem especially in healing of fissure, pain relief, quality of life and recurrence. Pharmacologic agents should be reserved for patients who are unfit or unwilling for surgery or can be used as a bridge therapy till sphincterotomy can be planned.

**Keywords:** Anal fissure, Diltiazem, Sphincterotomy

## INTRODUCTION

Anal fissure is a common disorder of anorectal region encountered in our surgical practice. Anal fissure is a linear ulceration of the squamous lining of the distal anal canal producing pain in the anal region during defecation.<sup>1</sup> Acute anal fissures usually heal spontaneously within 4-6 weeks. Chronic fissures on the other hand are those which persist beyond 6 weeks causing chronic pain and showing secondary changes such as skin tag or sentinel pile and hypertrophic papilla.

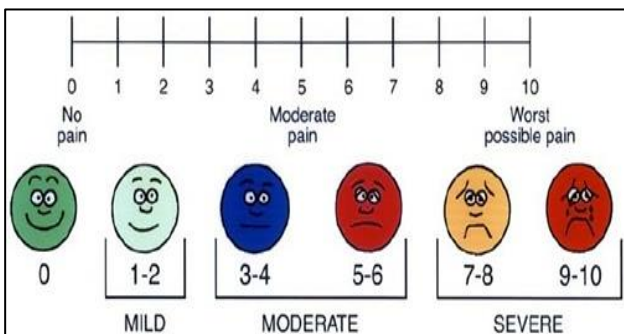
Etiopathogenesis of fissure in ano is not well understood but commonly attributed to increase in the sphincter tone with passage of hard stools causing a linear ulcer. The vicious cycle of healing by contracture and increased resting anal pressure causes chronic inflammation thereby resulting in chronic anal fissure with secondary changes such as a sentinel tag.<sup>2</sup> Thus relieving the sphincter spasm is the ultimate aim of treatment and this can be achieved either by surgery or by medical management. The American Society of Colon and Rectal Surgeons recommend conservative management with stool

softeners, high fibre diet and sitz bath as the initial line of management.<sup>3</sup> However surgery has been the main stay of treatment over the decades.<sup>4,5</sup> With better understanding of the internal anal sphincter mechanism and owing to the advancement in pharmacotherapy, chemical sphincterotomy with drugs such as GTN, ISDN, botulinum toxin, diltiazem local applications have been tried.<sup>6</sup>

The aim of this randomized comparative study was to compare the efficacy of lateral anal sphincterotomy with 2% diltiazem cream topical application in the treatment of chronic fissure in ano.

**METHODS**

This prospective comparative study was conducted in the department of General Surgery Shri Sathya Sai Medical College and Research Institute, Ammapettai, Tamil Nadu over a period of one year from November 2017 to November 2018 after getting approval from the Institute ethical committee. 80 Patients with chronic anal fissure were randomized into 2 groups group A and B with 40 patients each by table of randomized numbering. All the patients of age more than 20 years with anal fissure, with symptoms persisting more than 6 weeks and per-rectal examination showing features of chronicity such as sentinel piles and exposure of the internal anal fibres were included in the study. Those patients with fissures complicated with fistula and anal stenosis, with previous ano-rectal surgery, other co-morbid conditions, bleeding diathesis and bedridden patients were excluded from the study. The study group were explained in detail about the procedure and informed consents were obtained. Group A patients were subjected to surgery lateral internal anal sphincterotomy under spinal anesthesia, while group B patients received treatment with 2 to 2.5 cm of length of 2% diltiazem hydrochloride cream three time daily for 8 weeks. All the patients in both groups were given stool softeners, high fibre diet and sitz bath.



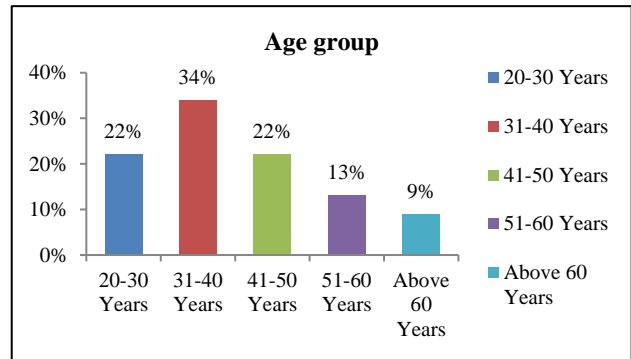
**Figure 1: Visual analogue scale.**

Patients were asked to review in OPD at 1<sup>st</sup>, 4<sup>th</sup>, 14<sup>th</sup> weeks and at 6 months. During the visits, pain relief was assessed by asking the patient to fill the VAS (visual analogue scale) (Figure 1) for pain and the degree of healing was assessed by digital rectal examination and any complication like incontinence and recurrence were

probed by relevant questionnaire and recorded.<sup>7</sup> SPSS 25 software was used for statistics.

**RESULTS**

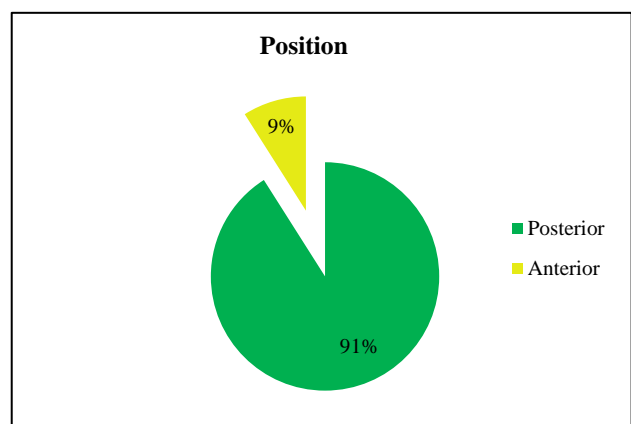
Among the 80 patients included in the study, 24 were male and 56 were female, which shows slight female preponderance.



**Figure 2: Study population among different age group.**

Pertaining to age, patients of 31 to 40 years contributed to 40% of the study population, while 20 to 30 years contributed to 22.5 %, 41 to 50 years making up to another 22.5%, 51 to 60 years for 12.5% and above 60 years contributed to 8.5% of the study population which shows that chronic anal fissure is more common in middle age (Figure 2).

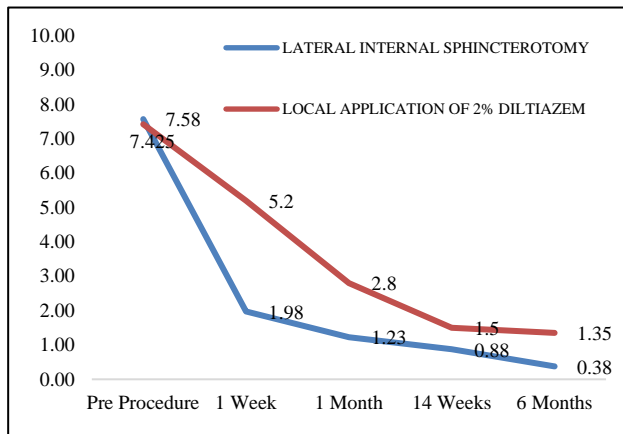
With respect to symptoms, out of 80 patients who were included in the study everyone had pain per anum, constipation and 72 patients had bleeding per anum on presentation at the OPD. None of them had pruritus or discharge.



**Figure 3: Percentage of presentation with different midline position.**

With respect to position, 73 patients had posterior midline fissure while 7 had anterior midline fissure (Figure 3).

Both the groups (group A and group B) had similar mean pain scores of 7.43 and 7.58 respectively prior to procedure. 1-week post procedure the mean pain score of both the reduced significantly, the mean VAS score being 1.98 (mild) for group A and 5.2 for group B. Even though both the groups had significant decrease in pain, the patients of group A had more pain relief when compared to those of group B. The mean pain score of group A and B at 4 weeks post intervention was 1.23 and 2.8 respectively, at 14 weeks it was 0.88 and 1.5 respectively and at 6 months it was 0.38 and 1.35 respectively.



**Figure 4: Comparison of VAS- mean pain score of two groups of patients.**

Study population in group A achieved pain relief with a mean pain score of 1.98 by one-week post-surgery whereas group B has taken 14 weeks to achieve similar (1.5) mean pain score (Figure 4).

At the end of 6 months healing of fissure was noted in 100% patients in group A and 90% patients in group B. With regards to complication flatus incontinence was reported in 5% (2 patients) patients of group A and none in group B. Head ache was reported in 5% of group A (2 patients) and none in group B.

At the end of follow up for 6 months there was no recurrence in group A whereas 5% of patients in group B had recurrence.

**DISCUSSION**

Anal fissure is a painful disorder of the anal canal commonly encountered in surgical practice. It affects the quality of life adversely and hence demands a promising mode of treatment. Chronic anal fissures do not heal spontaneously with dietary modifications and stool softeners.<sup>6,7</sup>

The change in dietary habit adding to the major pathology of spasm of internal anal sphincter resulting in hypertonia and raised anal canal resting pressure leads to ischemia of anoderm over the posterior of anal canal causes an anal fissure.<sup>3,8</sup> Posterior midline fissure are

more common than anterior midline fissure due to lack of muscular support of the anal canal epithelium posteriorly and has poor blood supply.<sup>9</sup>

In present study, among 80 patients 73 (91%) had posterior midline fissure and 7 (9%) had anterior midline fissure (Figure 3).

Chronic fissure is a middle age disease with high incidence between 30 to 50 years of age affecting both men and women equally.<sup>10</sup> In present study 54% belong to this age group of 30 to 50 years. Though this study shows female preponderance literature and similar studies with a larger sample size show no such preponderance.

With respect to symptoms, out of the 80 patients who underwent the study, everyone had pain per anum, constipation and 72 had bleeding per anum on presentation at OPD that accounts for 90% of the study population. None of them had pruritus or discharge.

Surgery has been the mainstay of treatment for chronic fissure.<sup>4,5</sup> Both open and closed sphincterotomy are equally efficacious.<sup>11</sup> In present study the procedure done was open method of lateral internal sphincterotomy. A narrative review shows that Manual anal dilatation is no longer recommended.<sup>12</sup>

Various pharmacological agents are used as chemical sphincterotomy such as GTN, CCB, botulinum toxin.<sup>6</sup> But randomised trials show that diltiazem is superior to other pharmacological agents.<sup>13,14</sup> Calcium channel blockers such as nifedipine and diltiazem help in reducing resting anal pressure and thus promoting healing of fissure.<sup>15</sup> In present study medical management used is 2% diltiazem cream local application.

In present study, among the total sample population of 80 with 40 in each group, both group A and group B had similar mean pain scores 7.425 and 7.58 respectively before initiation of treatment in the first visit.

At 1<sup>st</sup> week of review, the mean pain score of both the groups reduced statistically significantly, the mean score being 1.98 (mild) for group A and 5.2 for group B i.e., moderate. Even though the patients of both the groups have statistically significant decrease in the pain score, the patients in group A had mild degree of pain whereas the group B still had moderate pain.

At 4<sup>th</sup> week of review, the mean pain score of group A and B were mild, group A mean pain score of 1.23 and group B of 2.8.

At 14<sup>th</sup> week of review, group A had mean pain score of 0.88 and group B of 1.5.

At 6<sup>th</sup> month of review, the mean pain score of group A and B were mild, group A showing 0.38 and group B had mean pain score of 1.35.

100% patients who underwent (surgery) lateral internal anal sphincterotomy showed healing of fissure with excellent pain relief (mean VAS- 0.38) and 90% patients who applied 2% diltiazem showed healing of fissure (mean VAS- 1.35) at the end of study.

In group A 2 patients, i.e., 5% of group A had flatulent incontinence and it was transient. None had faecal incontinence. In group B (local application of 2% Fazem) 4 patients, i.e., 10% of group B had recurrence within 6 months.

Considering pain relief, study population in group A (lateral anal sphincterotomy) achieved pain relief with a mean pain score of 1.98 (mild) by 1-week post procedure whereas group B has taken 14 weeks to achieve similar (1.5) mild pain score. Thus, rate of healing is slower with diltiazem group with 10% chance of recurrence.

Similar studies comparing surgery and 2% diltiazem in management of chronic anal fissure. Vaithianathan et al randomised 90 patients with 45 in each. In diltiazem group, 71 % had complete healing of fissure at 6 weeks, with fair amount of pain relief (mean VAS- 3.38), and in surgery group, 96% showed healing of fissure, with excellent pain relief (mean VAS- 1.87). Headache and flushing were noted in two patients who applied 2% diltiazem while no patients who had surgery developed incontinence.<sup>16</sup>

Giridhar et al randomised 60 patients in two groups, group 1 (2% diltiazem gel) and group 2 (internal sphincterotomy) at Bangalore medical college, from September 2009 to September 2011, in 4 weeks 85% of patients who underwent surgery were pain free and 78% of patients who applied diltiazem were pain free.<sup>17</sup>

Popat et al randomised 100 patients into two groups 50 each and underwent the study, 89.36% of patients who applied 2% diltiazem and 100% who underwent surgery had pain relief at the end of 14 weeks. 10.6% had no pain relief. Mild head ache was noted in 3 (10%) of patients who applied 2% diltiazem. Flatus incontinence was complained by 1 (2.1%) patient who underwent surgery.<sup>18</sup>

## CONCLUSION

We conclude that, lateral internal sphincterotomy is superior to 2% topical diltiazem for treating chronic anal fissure considering the rate of pain of relief, rate of healing, quality of life and no chance of recurrence (0% in present study), except for (5%) flatus incontinence (2 patients among 40 patients) which is usually transient. In chemical sphincterotomy with local application of 2% diltiazem, rate of healing is slow, except that (10%) 4 patients had recurrence among 40 patients.

Thus, surgery remains the gold standard treatment of chronic anal fissure and chemical sphincterotomy can be considered good first line treatment option for patients

who are unfit or unwilling for surgery, with no need for in hospital stay and very cost effective.

*Funding: No funding sources*

*Conflict of interest: None declared*

*Ethical approval: The study was approved by the Institutional Ethics Committee*

## REFERENCES

1. Leong APK. The pharmacological treatment of anal fissures- a future role in the primary care. *Singapore Med J.* 2003;44:136-7.
2. Jensen SL. Diet and other risk factors for fissure-in-ano. A prospective case control study. *Dis Colon Rectum.* 1988;31:770-3.
3. Perry WB, Dykes SL, Buie WD, Rafferty JF. Standards practice task force of the American Society of Colon and Rectal Surgeons Practice parameters for the management of anal fissures (3rd. Revision). *Dis Colon Rectum* 2010;53:1110-5.
4. Schouten WR, Briel JW, Auwerda JJ, De Graaf EJ. Ischemic nature of anal fissure. *Br J Surg.* 1996;83:63-5.
5. Tocchi A, Mazzoni G, Miccini M, Cassini D, Bettelli E, Brozzetti S. Total lateral sphincterotomy for anal fissure. *Int J Colorect Dis.* 2004;19(3):245-9.
6. Marion J, Scholefield JH. Anal fissure and chemical sphincterotomy. In: Taylor I, Johnson CD, eds. *Recent advances in Surgery.* 24<sup>th</sup> Edn. Churchill Livingstone; 2001: 115.
7. Griffin N, Acheson AG, Tung P, Sheard C, Glazebrook C, Scholefield JH. Quality of life in patients with chronic anal fissure colorectal disease. 2004;6(1):39-44.
8. Nelson RL, Thomas K, Morgan J, Jones A. Non surgical therapy for anal fissure. *Cochrane database Syst Rev.* 2012(2).
9. Jennifer K. Lowney, James W. Fleshman, Jr., Benign disorders of the ano rectum, Michael J. Zinner MJ, Ashley SW, eds. *Maingot's Abdominal Operations.* 11th edn. Tata McGraw Hill; 2007: 680-684.
10. Mazier WP. An evaluation of the surgical treatment of anal fissure. *Dis Colon Rectum.* 1975;47:33-9.
11. Wiley M, Day P, Rieger N. Open vs. closed lateral internal sphincterotomy for indio-pathic fissure-in-ano. A prospective, randomized, controlled trial. *Dis Colon Rectum.* 2004;47:847-52.
12. Sritharan H, Kumar NKA, Ibrahim MIS. Management of chronic anal fissures: a narrative review. *Int Surg J.* 2020;7:1327-31.
13. Shrivastava UK, Jain BK, Kumar P. A comparison of the effects of diltiazem and glyceryl trinitrate ointment in the treatment of chronic anal fissure: a randomized clinical trial. *Surg Today.* 2007;37:482-5.
14. Ala S, Saeedi M, Hadianamrei B. Topical diltiazem vs. topical glyceryl trinitrate in the treatment of

- chronic anal fissure: a prospective, randomized, double-blind trial. *Acta Gastroenterol Belg.* 2012;75:438-42
15. Carapeti E, Kamm M, Evans B, Phillips R. Topical Diltiazem and Bethanechol decrease anal sphincter pressure and heal anal fissures without side effects. *Dis Colon Rectum.* 1999;43(10):1359-62.
  16. Vaithianathan R, Panneerselvam S. Randomised prospective controlled trial of topical 2% diltiazem versus lateral internal sphincterotomy for the treatment of chronic fissure in ano. *Indian J Surg.* 2015;77(3):1484-7.
  17. Giridhar CM, Babu P, Rao KS. A comparative study of lateral sphincterotomy and 2% diltiazem gel local application in the treatment of chronic fissure in ano. *J Clin Diagn Res.* 2014;8:1-2.
  18. Popat A, Pandey CP, Agarwal K, Srivastava VP, Sharma SM, Dixit A. A comparative study of role of topical diltiazem 2% organo gel and lateral internal sphincterotomy for the management of chronic fissure in ano. *Int J Contemp Med Res.* 2016;3(5):1363-5.

**Cite this article as:** Sritharan H, Kumar NKA, Mohamed ISIMS. Single centre randomized comparative trial of lateral internal sphincterotomy versus 2% diltiazem in chronic anal fissure. *Int Surg J* 2020;7:1723-7.