

Case Report

Management of pseudo tumour in haemophilia patients

Sherlyn Ambrose^{1*}, Giridhar Ashwath¹, Sreekar Balasundaram², Suresh Kumar²,
Cecil Ross³, Anthony Prakash Rozario¹

¹Department of General Surgery, ²Department of CTVS, ³Department of General Medicine and Hematology, St. John's Medical College and Hospital, Bangalore, Karnataka, India

Received: 27 February 2020

Accepted: 08 April 2020

*Correspondence:

Dr. Sherlyn Ambrose,

E-mail: dr.sherlynambrose@gmail.com

Copyright: © the author(s), publisher and licensee Medip Academy. This is an open-access article distributed under the terms of the Creative Commons Attribution Non-Commercial License, which permits unrestricted non-commercial use, distribution, and reproduction in any medium, provided the original work is properly cited.

ABSTRACT

A hemophilic pseudotumor is one of the rare complications of hemophilia that results from repetitive bleeding, forming an expanding destructive encapsulated hematoma and necrosed tissue. It has a considerable amount of morbidity. These have become rare over the years with better treatment modalities like factor replacement. Presently, excision is the preferred treatment by many authors. There are instances where surgical excision is not feasible. In such situations, radiotherapy and arterial embolization should be considered either alone or as an adjunct to surgery. A 32 years old male patient, with severe hemophilia A diagnosed with an abdominal tumour 7 years ago during routine screening, that progressively grew to encompass the lower abdominal area. A 44 years old male patient with hemophilia A presented with slow growing swelling over the left gluteal region since, 10 years associated with ulceration and bleeding since, 3 days. The management of a patient with a haemophilic pseudo tumour is complex, with a high rate of potential complications. Surgical excision is the treatment of choice but can only be carried out by a multidisciplinary surgical team. The main postoperative complications are rebleed, infection, fistula and pathological fractures. Pelvic pseudo tumours can even become complicated by fistula formation to the large bowel and by obstruction of the ureters. Untreated pseudo tumours will ultimately destroy soft tissues, erode bone, and may produce neurovascular complications. The hemophilic pseudo tumour is a rare entity which is slow growing painless tumour, with few reports worldwide in the management of this rare complication.

Keywords: Pseudo tumour, Haemophilia A, Abdominal tumour

INTRODUCTION

Hemophilia A and B are caused by a deficiency of factors VIII and IX, respectively.¹ Hemophilia A is a congenital disease transmitted by the X chromosome with a recessive trait, characterized by a deficiency in the production of factor VIII.² The incidence is 10-20 cases per 100,000 people.³ Clinical manifestations vary depending on the severity of the disease.

The haemophilic pseudotumor affects 1-2% of patients with a severe disease, frequently associated with a traumatic injury.⁴ The haemophilic pseudotumor develops from repeated episodes of bleeding, either from

fracture sites or bleeding into any soft tissue.¹The inadequately reabsorbed blood becomes an encapsulated mass of blood and necrotic tissue. The interior of the pseudotumor consists of hematoma at different stages of development, surrounded by a fibrous capsule containing hemosiderin-laden macrophages.⁴

It appears as a slow growing painless tumour that can compress organs causing bone destruction, muscle and skin necrosis. There are very few cases reported in the literature involving the abdomen. Most studies describe those involving the musculoskeletal system.

CASE REPORTS

Case 1

A 31 years old male, diagnosed with hemophilia from 6th month of age and treated periodically with factor VIII. In 2012, abdominal mass was diagnosed during routine screening that progressively grew to encompass the entire lower abdominal area causing on and off pain abdomen and vomiting. A CECT abdomen showed bilateral heterodense iliopsoas hematoma left>right. Left side hematoma was encasing the mid and distal ureter. It was noted extending into the left iliac bone and ischium causing destruction. Also, the left common and internal iliac artery/vein and distal ileal and large bowel loops were pushed to the right. An exploratory laparotomy with pseudo tumour excision and bilateral femoro-femoral grafting (6 mm) was done. Prior to this he underwent bilateral stenting for hydronephrosis. The surgical findings were the sigmoid colon was stretched over the tumour and shifted to right. The left ureter and the left external artery were shifted to right, coursing over the tumour. The tumour wall was opened and evacuated the cavity. Accessible part of the tumour wall was excised.

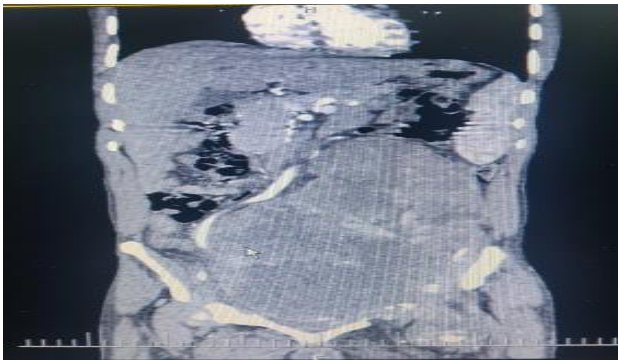


Figure 1: CECT showing left sided pseudo tumour.

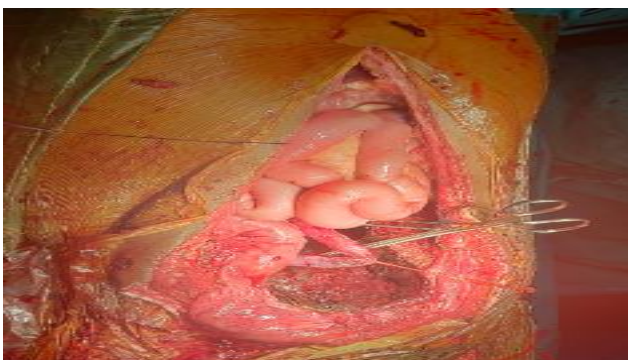

Figure 2: Post excision.

Case 2

A case of 44 years old male, diagnosed with haemophilia A presented with complaints of left gluteal swelling since 10yrs, gradually increasing in size associated with bleeding and wound over the swelling for 3 days. Prior to

admission, a CECT showed pseudo tumour in subcutaneous plane of left gluteal region. He underwent excision with V-Y advancement flap cover and split skin grafting. The surgical plane of pseudo tumour was below the subcutaneous plane and above the gluteus maximus.

DISCUSSION

Haemophilia A is a disease with an incidence of 1 in 25,000 males and perioperative management can often be challenging.^{6,7} The most common symptoms at presentation are bleeding into the joints with inflammation leading to deformities.⁶ The abdominal pseudotumor is rare but often disabling condition, potentially fatal in severe haemophilic patients.⁸ Diagnosing with invasive techniques such as, aspiration and biopsy are not advisable due to increased risk of hemorrhage and infection.⁴ MRI allows recognition of blood products in various stages of evolution. USG shows a central anechoic region with increased echoes behind the lesion due to enclosed fluid in the pseudotumor. CT identifies the thick pseudo capsule, but cannot differentiate a hematoma from a chronic abscess. Surgical excision is the preferred treatment by many authors. However, surgical excision of the lesion is not feasible always. In such situations, radiotherapy and arterial embolization should be considered either alone or in conjunction to surgery.⁵ Surgical excision after performing arterial embolization to reduce the vascularization of the pseudo tumour is a good alternative, thereby reducing the size of the pseudo tumour and the risk of bleeding during surgery, at best about 2 weeks prior to surgery. This time lapse will allow for mass shrinkage but is insufficient for vessel restoration.^{9,10} Pseudo tumour is a rare pathological entity, but it must be considered in the hemophilic patient with a long-standing abdominal tumour.

Decision to operate on these patients was based on massive tumour size causing compressive symptoms. The surgery was performed without major intraoperative complication. Surgery is associated complications such as bleeding, bowel perforation, and damage to nearby structures due to adhesions. In case 1, patient's left external iliac artery was running over the tumour, had an iatrogenic rent which was repaired and femoral cross over 6mm graft was placed. Post-operatively patient developed paralytic ileus which was managed conservatively. In case 2, patient underwent excision of the tumour with VY advancement flap for closure of the large defect.

CONCLUSION

Haemophilic pseudo tumors are a well-documented complication of bleeding disorders that clinicians should be aware of while caring for such patients. Signs and symptoms of compression should be evaluated early on with CT and then MRI. Early surgical consultation along with factor replacements are essential steps after

diagnosis is made. There is no standard treatment protocol for management of pseudo tumors. Therapy for haemophilic pseudo tumor should be selected on a case-by-case basis along with the full involvement of a multidisciplinary team including haematologist, vascular and plastic surgeon.

Funding: No funding sources

Conflict of interest: None declared

Ethical approval: Not required

REFERENCES

1. Pakala A, Thomas J, Comp P. Hemophilic pseudotumor: a case report and review of literature. *Int J Clin Med.* 2012;3:229-33.
2. Mathew M, Goel G, Kurien A. Digital pseudotumor associated with Von Wille-brand disease. *Internet J Hematol.* 2009;5:2.
3. Bom VJG, Avest TP, Berg VHM, Psaty BM, Weiss NS. Assessment of incidence of inhibitors in patients with haemophilia. *Haemophilia.* 2009;15:707-11.
4. Stafford JM, James TT, Allen AM, Dixon LR. Hemophilic pseudotumor: radiologic-pathologic correlation. *Radiographics.* 2003;23:852-6.
5. Espandar R, Heidari P, Merchan RC. Management of haemophilic pseudo tumors with special emphasis on radiotherapy and arterial embolization. *Haemophilia.* 2009;15:448-57.
6. Jayandharan GR, Srivastava A. Hemophilia: Disease, Diagnosis and Treatment. *J Genet Syndr Gene Ther.* 2011;59(7):462-5.
7. Tagariello G, Iorio A, Santagostino E, Morfini M, Bisson R, Innocenti M, et al. Comparison of the rates of joint arthroplasty in patients with severe factor VIII and IX deficiency: An index of different clinical severity of the 2 coagulation disorders. *Blood.* 2009;114:779-84.
8. Merchan REC. Haemophilic cysts (pseudo tumours). *Haemophilia.* 2002;8:393-401.
9. Merchan REC, Yuste JV. The role of selective angiographic embolization of the musculo-skeletal system in haemophilia. *Haemophilia.* 2009;15:864-8.
10. Ahuja SP, Sidonio R, Raj AB, Bertolone SJ, Silverman C, Antekeier DP, et al. Successful combination therapy of a proximal haemophilic pseudo tumour with surgery, radiation and embolization in a child with mild haemophilia A. *Haemophilia.* 2007;13:209-12.

Cite this article as: Ambrose S, Ashwath G, Balasundaram S, Kumar S, Ross C, Rozario AP. Management of pseudo tumour in haemophilia patients. *Int Surg J* 2020;7:2033-5.