

Original Research Article

A clinical study on varicose veins of lower limb, surgical management and functional outcome at a tertiary care hospital of South India

Bandaru Nageswara Rao, Ramachandra Pusphalatha*

Department of General Surgery, ACSR Medical College and Hospital, Nellore, Andhra Pradesh, India

Received: 15 February 2020

Accepted: 03 March 2020

*Correspondence:

Dr. Ramachandra Pusphalatha,

E-mail: sujithbhanu1212@gmail.com

Copyright: © the author(s), publisher and licensee Medip Academy. This is an open-access article distributed under the terms of the Creative Commons Attribution Non-Commercial License, which permits unrestricted non-commercial use, distribution, and reproduction in any medium, provided the original work is properly cited.

ABSTRACT

Background: Varicose veins defined as dilated, tortuous, subcutaneous veins ≥ 3 mm in diameter, measured in the upright position with demonstrable reflux. Though the history of varicose veins dates prehistorically, the advances in diagnosis and new management modalities gained attention recently. The aim of the present study was to study the clinical profile, risk factors and their association, different types of surgical procedures employed and complications associated with varicose veins.

Methods: A one year observational after ethical committee approval was conducted by department of general surgery at ACSR Medical College. Cases fulfilling the inclusion criteria were clinically examined and duplex ultrasound colour Doppler was performed for diagnosing the varicose veins and findings of site of incompetence was noted. All the cases were operated and followed up for six months period. The results were tabulated and analyzed in Microsoft Excel for any corrections.

Results: Eighty cases with 66.25% males and 33.75% females with mean age of 40.24 years and majority (40%) were in 41 to 50 years group. 60% of cases had varices in right limb and long saphenous vein was involved in 52.5% of cases. 85% had dilated veins, perforator incompetence was noted below the knee in 30% of cases. 41.25% of cases saphenofemoral flush ligation with stripping of long saphenous vein. Wound infection was the common postoperative complication.

Conclusions: Operative line of management should be the first line of treatment even though conservative management relieves the symptoms but always requires a definitive management.

Keywords: Varicose veins, Colour Doppler, Long saphenous vein, Wound infection

INTRODUCTION

Varicose veins defined as dilated, tortuous, subcutaneous veins ≥ 3 mm in diameter, measured in the upright position with demonstrable reflux. This is not a condition which causes mortality but a disorder which causes severe morbidity and loss of working hours. This condition was more observed in western countries with a prevalence of 15-20% but in India it affects only 5% of the population.¹ varicose veins and their associated symptoms, complications constitute one of the most common chronic vascular disorders of the lower limb.

Though the history of varicose veins dates prehistorically, the advances in diagnosis and new management modalities gained attention recently. Various predisposing factors have been identified in development of varicose veins which include pregnancy, prolonged standing, obesity, old age, intra-abdominal pressure and heredity also identified as a predominant risk factor in many published studies.²

The mechanism in occurrence of varicose veins is development of defects in the valves or walls of the superficial venous system or perforating veins.

Pathophysiology of the venous system from the hemodynamic point of view and the consequences of valvular dysfunction in superficial, deep, and perforating veins have confirmed in causation of varicose veins and skin trophic changes among the chronic cases of varicose veins. Prehistorically management of varicose veins were by bandaging techniques, stripping of veins and ligation. Now duplex imaging and Doppler ultrasound has become the mainstay of investigations in diagnosis of chronic venous insufficiency disorders. The various surgical management techniques for varices include Trendelenburg operation, stripping, subfascial ligation of perforators, laser, sclerotherapy and radiofrequency ablation. The search for effective means of diagnosis and treatment and prevention and management with reduction in development of postoperative complications continues.³

The aim of the present study was to study the clinical profile, risk factors and their association, different types of surgical procedures employed and complications associated with varicose veins.

METHODS

A prospective observational study was conducted at ACSR medical college and hospital a tertiary care hospital for a period of one year from September 2018 to August 2019. The study was conducted by department of General surgery. All the cases attending the OPD or referred to the department with symptoms of varicose veins were included in the study. The study was presented before the ethical committee and approved. The study was conducted as per the guidelines of the committee. Study protocol was clearly explained and a written informed consent was obtained from all the participants of the study. The socio demographic data with age, sex, occupation, family history was noted by interviewing the cases and entered in a separate predesigned questionnaire sheet.

Inclusion criteria

Varicose veins with symptoms of aching, heaviness and cramps also with complications such as pigmentation, dermatitis, ulceration and superficial thrombophlebitis and large varicosities subject to trauma and cosmetic concern were included.

Exclusion criteria

Patients treated on outpatient basis, with secondary varicose veins, with deep vein thrombosis, peripheral vascular disease and pregnancy were excluded from the study.

All the cases were examined clinically and signs and symptoms were noted and all the cases were confirmed by performing duplex ultrasound colour Doppler and the site of incompetence was noted. Brodie Trendelenburg

test, multiple tourniquet test and Perthe's clinical tests were performed on all the cases in the study.

Surgical management

Trendelenburg's operation, stripping of long saphenous vein, subfascial or extra facial ligation of perforators, multiple stab avulsion of long saphenous vein and saphenopopliteal junction ligation procedures were performed.

All the cases that underwent surgical procedure were followed postoperatively for any complications every 1 month for development of surgical site infections, after 3 months for healing of ulcer and symptomatic relief and six months for any signs of recurrence.

Statistical analysis

The collected data was entered in Microsoft Excel spread sheet and analyzed.

RESULTS

In the present prospective study, a total of eighty cases who fulfilled the inclusion criteria and consented for the study were enrolled. Male predominance with 53 cases (66.25%) and females with 27 cases (33.75%) were observed with a male female ratio of 1.95:1. With regard to distribution of age, 40% (32 out of 80) of cases were in between 41 to 50 years, 26.25% (21 out of 80) between 51 to 60 years, 11.25% (9 out of 80) above 60 years, 15% (12 out of 80) between 31 to 40 years and 7.5% (6 out of 80) in between 21-30 years. None of the cases observed were less than 20 years (Table 1). The range of age distribution of the cases in the study was 24 to 74 years. In our study, varicosities were observed in right limb in 60% of cases, 25% in left and bilateral in 15% of cases. In our cases, 30% had a definitive history of varicose veins in the family and 51.25% of cases were having an occupation with long duration of standing. 55% of the cases were smokers and 47.5% were alcoholics. The long saphenous vein bears the entire brunt of entire posture as it extends the whole length of the lower limb. The long saphenous vein was involved in 52.5% of all cases, short saphenous in 27.5% and both in 20% of cases (Table 2).

Signs and symptoms

The predominant symptom in majority of the cases was pain in 52.5% of cases followed by heaviness in 48% of cases. Dilated veins were observed in 85% of cases, skin changes like pigmentation, dermatitis etc in 47.5%, edema of the affected limb in 27.5% and ulcerations in 25% of the cases (Table 3).

Long saphenous system was involved in 47.5% of cases, long saphenous along with incompetent perforators in 23.75%, short saphenous system in 13.75% and both in 15% of cases in the present study. In 30% of the cases,

site of perforator incompetence was noted in below knee position, 27.5% above the ankle, 20% in the thigh region and 8.75% unnamed (Table 4).

Table 1: Age distribution of cases in the study.

Age distribution (in years)	No	%
10-20	0	0
21-30	6	7.5
31-40	12	15
41-50	32	40
51-60	21	26.25
>60	9	11.25

Table 2: Risk factors and associated factors of the cases in the study.

Factor	No	%
Side affected		
Right	48	60
Left	20	25
Bilateral	12	15
Venous system		
Long saphenous	42	52.5
Short saphenous	22	27.5
Both	16	20
Risk factors		
Family history	24	30
Agricultural workers	10	12.5
Sedentary activity	41	51.25
Smoking	44	55
Alcoholism	38	47.5

Table 3: Signs and symptoms of cases.

Signs and symptoms	No	%
Pain	42	52.5
Dilated veins	68	85
Edema of limb	22	27.5
Ulcerations	20	25
Skin changes (pigmentation etc)	38	47.5

Table 4: Distribution of venous system and site of perforator incompetence among the cases.

Variable	No	%
Venous system involved		
Long saphenous system	38	47.5
Long saphenous + incompetent perforators	19	23.75
Short saphenous system	11	13.75
Both	12	15
Perforator incompetence		
Thigh	16	20
Below knee	24	30
Above ankle	22	27.5
Unnamed	7	8.75

Table 5: Surgical procedures performed among the cases in the study.

Surgical procedures performed	No	%
SSFFL+stripping	33	41.25
SSFFL+ligation+multiple avulsion	6	7.5
SSFFL+stripping+subfascial ligation	16	20
SPL	6	7.5
SPL+stripping	2	2.5
Multiple stab avulsion	3	3.75

SSFL: saphenofemoral flush ligation; SPL: sapheno popliteal ligation.

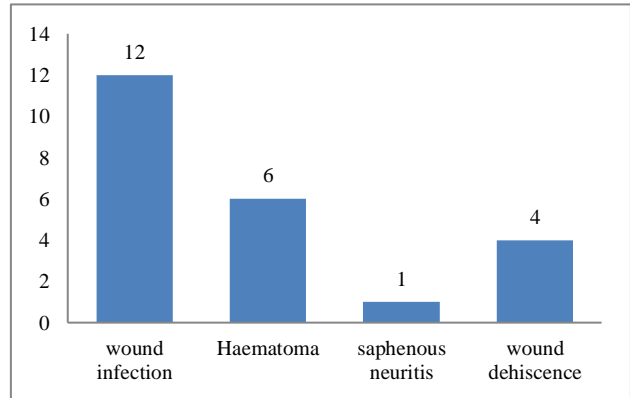


Figure 1: Complications of surgery among the cases in the study.

In the present study all the cases were managed surgically and in 41.25% of cases saphenofemoral flush ligation (SSFL) with stripping of long saphenous vein were performed, in 20% of cases SSFL along with stripping and subfascial ligation was performed, saphenopopliteal ligation alone was performed in 7.5% of cases, sapheno popliteal ligation with stripping in 2.5% of cases. Multiple stab avulsion was performed in 3.75% of cases (Table 5). Wound infection was the common postoperative complication in our study with 12 cases and other minor were haematoma in 6 cases, wound dehiscence in 4 cases and saphenous neuritis in one case (Figure 1).

DISCUSSION

A varicose vein is one of the common clinical disorders encountered by the surgeons in regular practice. This is a silent disease which develops in early life and assumes a silent course in the life time. This condition is not associated with mortality but with high morbidity and associated complications due to development of venous hypertension.

Male predominance with 66.25% of males in our study was observed which is similar to the findings of many Indian studies, but studies conducted in western countries report female dominance which is due to the scenario that females in india are not exposed to high risk of work which involve prolonged standing and physical stress due

to cultural and socioeconomic conditions.⁴ In the present study, majority of the cases (40%) were in the age group of 41 to 50 years with a mean age of 43.40 years which is on par with the findings in the study of Mishra et al from India and McGuckin et al.^{5,6} As most of the studies universally reported, dilated veins was the most common symptom in our study also with 85% of cases as compared to Rudofsky et al with 90% and Shankar et al with 94% in their studies.^{7,8} Observation of varicose veins in several members of the same family suggest a clear hereditary factor as cause of varicose veins, in our study 30% of the cases had a definitive family history which is similar to the reports of Staniszewska et al who conducted a study among the European population and reported significant association between varicose veins and family history.⁹

In the present study, skin changes like lipodermatosclerosis, pigmentations and eczema were observed in 47.5% of cases which is quite higher when compared with the studies in western population which may be due to less cosmetic importance among the Indian population and neglected nature of the minor ailments like swelling without any pain. Agarwal in his study reported an incidence of 52% of skin changes among the cases in his study which is on par with the present study.¹⁰ Right limb was involved in 60%, left in 25% and bilateral involvement in 15% of cases in the study. Many studies reported an increased involvement of left limb which is contrary in our present study. The explanation of left limb involvement may be due to compression of left iliac veins by left loaded colon, left common iliac vein crossing over left iliac artery, and the longer course travelled by left iliac veins.

In the present study, no significant association was found between smoking and alcoholism and the occurrence of varicose veins. Findings of our study were comparable with the reports of Carpentier et al.¹¹

In our present study, the long saphenous vein was involved in 52.5% of all cases, short saphenous in 27.5% and both in 20% of cases. Findings of our study were on par with the findings of many studies conducted universally and also in Indian scenario. In a study by Vashist et al, 60% of patients had involvement of great saphenous vein (GSV), 17% patients had small saphenous vein (SSV) while 23% patients had involvement of both GSV and SSV.¹² In the present study, in 30% of the cases, site of perforator incompetence was noted in below knee position, 27.5% above the ankle, 20% in the thigh region and 8.75% unnamed findings of our study were on par with the findings of Marrocco et al.¹³

Wound infection was the most common postoperative complication observed in all the cases managed surgically. SSFL with stripping of long saphenous vein was performed in 41.25% of the cases.

CONCLUSION

In the present study, varicose veins are commonly seen in males, maximum in the age group of 30 to 50 years. Most common presenting symptom is visible dilated veins over lower limb but more than half of the patients present with one or more complications. Most commonly venous system involved is great saphenous vein system and most commonly involved perforators are below knee perforators. SSFL with stripping of long saphenous was the most common procedure performed. None of the cases had recurrence after one year of follow-up. Operative line of management should be the first line of treatment even though conservative management relieves the symptoms but always requires a definitive management.

Funding: No funding sources

Conflict of interest: None declared

Ethical approval: The study was approved by the Institutional Ethics Committee

REFERENCES

1. McCollum P, Chapter I. Venous disorders. In: Bailey H, Love McN, editors. *Bailey and Love's Short Practice of Surgery*. 26th ed. Boca Raton, FL: CRC Press; 2013: 903.
2. Mirji P, Emmi S, Joshi C. Study of clinical features and management of varicose veins of lower limb. *J Clin Diagn Res*. 2011;5(7):1416-20.
3. Bradbury A, Evans C, Allan P, Lee A, Ruckley CV, Fowkes FG. What are the symptoms of varicose veins? Edinburgh Vein Study cross sectional population survey. *BMJ*. 1999;318:353-6.
4. Yun MJ, Kim YK, Kang DM, Kim JE, Ha WC, Jung KY, et al. A Study on Prevalence and Risk Factors for varicose Veins in Nurses at a University Hospital. *Saf Health Work*. 2018;79(1):79-83.
5. Mishra S, Ali I, Singh G. A study of epidemiological factors and clinical profile of primary varicose veins. *Med J DY Patil Univ*. 2016;9:617-21.
6. McGuckin M, Waterman R, Brooks J, Cherry G, Porten L, Hurley S, et al. Validation of venous leg ulcer guidelines in the United States and United Kingdom. *Am J Surg*. 2002;183:132-7.
7. Rudofsky G. Epidemiology and pathophysiology of primary varicose veins. *Langenbecks Arch Chir*. 1988;2:139-44.
8. Shankar KH. Clinical study of varicose veins of lower limbs. *Int Surg J*. 2017;4(2):633-6.
9. Staniszewska A, Tambyraja A, Afolabi E, Bachoo P, Brittenden J. The Aberdeen varicose vein questionnaire, patient factors and referral for treatment. *Eur J Vasc Endovasc Surg*. 2013;46:715-8.
10. Agarwal V, Agarwal S, Singh A, Nathwani P, Goyal P, Goel S. Prevalence and risk factors of varicose veins, skin trophic changes, and venous symptoms

among northern Indian population. *Int J Res Med Sci.* 2016;4(5):1678-82.

11. Carpentier PH, Maricq HR, Biro C, Makinen COP, Franco A. Prevalence, risk factors, and clinical patterns of chronic venous disorders of lower limbs: A population-based study in France. *J Vasc Surg.* 2004;40:650-9.
12. Vashist M, Godara R, Sen J, Panwar S. Management of varicose veins: Status of clinical examination and colour Doppler in the present Indian scenario. *Int J Surg.* 2008;20:1-4.
13. Marrocco CJ, Atkins MD, Bohannon WT, Warren TR, Buckley CJ, Bush RL. Endovenous ablation for the treatment of chronic venous insufficiency and venous ulcerations. *World J Surg.* 2010;34:2299-304.

Cite this article as: Rao BN, Pusphalatha R. A clinical study on varicose veins of lower limb, surgical management and functional outcome at a tertiary care hospital of South India. *Int Surg J* 2020;7:1051-5.