

Case Report

Recurrent ruptured ectopic pregnancy: a case report

Cipta Pramana^{1*}, Alicia Angelina², Najwa Sufa Hilwa³, Avicennia Nandira Munandar⁴,
Ario Lukas², Ivan Hosein²

¹Department of Obstetrics and Gynecology, K.R.M.T. Wongsonegoro General Hospital Semarang/Medical Faculty Tarumanagara University Jakarta, Indonesia

²Medical Faculty, Tarumanagara University, Jakarta, Indonesia

³Medical Faculty, Trisakti University, Jakarta, Indonesia

⁴Medical Faculty Sultan Agung Islamic University, Semarang, Indonesia

Received: 12 February 2020

Accepted: 06 April 2020

*Correspondence:

Dr. Cipta Pramana,

E-mail: pramanacipta@yahoo.com

Copyright: © the author(s), publisher and licensee Medip Academy. This is an open-access article distributed under the terms of the Creative Commons Attribution Non-Commercial License, which permits unrestricted non-commercial use, distribution, and reproduction in any medium, provided the original work is properly cited.

ABSTRACT

Ruptured ectopic pregnancy is an emergency obstetric case which requires fast and correct management. Authors report an interesting case of a 27-years-old with recurrent ruptured ectopic pregnancy and underwent a laparoscopy and salpingostomy operation. The operation outcome was good with no perioperative complications and operating results. Ectopic pregnancy requires fast and correct management because this case is an emergency and can lead to mortality.

Keywords: Ectopic pregnancy, Emergency, Laparoscopy, Salpingostomy

INTRODUCTION

Ruptured ectopic pregnancy (REP) represents a potentially serious medical and surgical condition for women during the reproductive age, with the possibility to evolve in an emergency obstetrical situation caused by the rupture and internal bleeding leading to hypovolemic shock and maternal death during the first trimester of gestation.^{1,2}

The vast majority of ectopic pregnancies (90%) implant occurs in the tubal ampulla, while 2.5% of cases are identified in the tubal interstitial portion. In the vast majority of the cases, the embryo prematurely implants itself in the fallopian tube before arriving in the uterine cavity.³

CASE REPORT

A 27-years-old in her 8-weeks 1 day-pregnancy, accompanied by her husband came to our obstetric emergency department at 9.37 a.m., complained severe

pain in all quadrants abdominal since last night. She frequently feels the pain since this pregnancy. She looked weak, and her eyes conjunctiva was anemic.

Her vital sign was stable, blood pressure 113/73 mmHg, heart rate 86 beats/min, respiratory rate 20 times/min, and temperature 36.6°C. When authors were doing a physical examination, authors found a surgical scar on the lower abdomen, and when authors asked, she told me that she had a history of abdomen surgery in 2014 because of an ectopic pregnancy. Authors suspected that was a laparotomy scar for her first ectopic pregnancy. On gynecological examination, the external ostium cervix was closed, corpus uterine size is normal, the parametrium adnexa is also normal, slinger pain is found, the Douglas pouch is bulging. The β hCG test is positive.

An emergency abdominal sonography examination is performed (Figure 1). It is shown that the uterus size is normal. The bladder is filled enough, there was a mass resembling gestational sac in the left adnexa, and there was retro-uterine fluid, probably on the Douglas pouch. These

findings confirmed that the patient has an ectopic pregnancy.

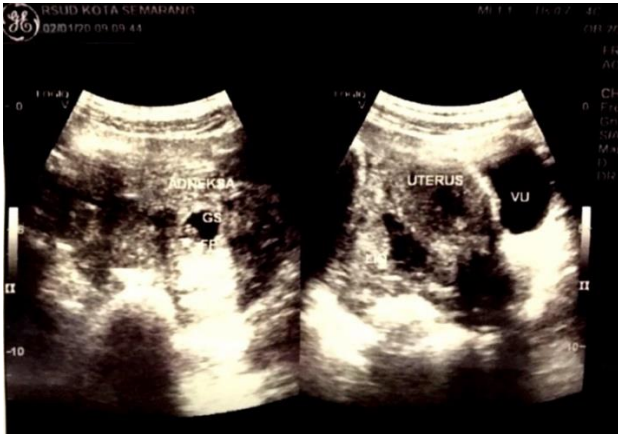

Figure 1: Abdominal sonography examination.

Authors are suggested to conduct an emergency laboratory blood test. Based on the laboratory test, laparoscopy is done because the patient was hemodynamically stable with Hb 12.8 g/dl. Urine catheter and 1 bore IV line are given on the left hand, consists of ringer lactate, cefotaxime IV 2×1 gr, and ketorolac IV 2×30 mg.

After the pre-operation preparation has completed, authors transferred the patient, half running, to the operation room. The laparoscopy performed with general anesthesia with the patient lying in a supine position. On exploration, the uterus was normal in size. The right tubal unidentified due to the history of previous ruptured ectopic pregnancy and salpingectomy in 2014. On the left adnexa, the distal of left tubal size enlarge about 2×3 cm in size and there were blood clots and gestation stick on infundibulum and fimbria, diagnosed a ruptured ectopic pregnancy in infundibulum and fimbria region (Figure 2), with active on-going bleeding from the fimbria end.

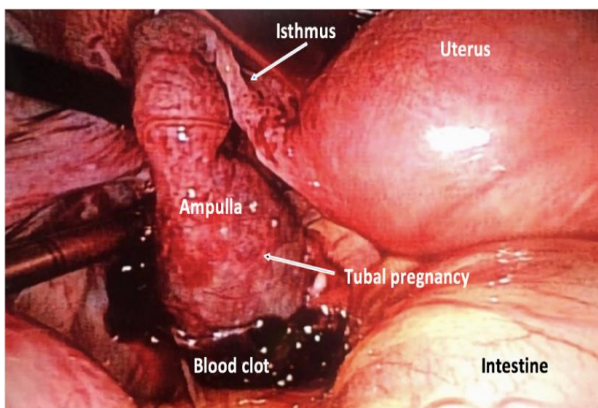


Figure 2: Ruptured ectopic pregnancy in the infundibulum.

Authors chose laparoscopy-salpingostomy in this case because there's no sign of rupture in the sinistral tube and the patient still hasn't got any child even though in

reproduction age. At laparoscopy, there were 70 ml of haemoperitoneum, and total operation time was 50 minutes.

The patient then observed postoperatively for 3 days. There was no complication during the operation and postoperation. A patient has a stable and good outcome.

DISCUSSION

An ectopic pregnancy occurs when a fertilized egg implants and grows outside the main cavity of the uterus. Approximately 1 in 100 pregnancies are ectopic, with the embryo usually implanting in the fallopian tube. Some tubal ectopic pregnancies resolve spontaneously, but others continue to grow and can lead to rupture of the tube. Risks for ectopic pregnancy are higher in women with damage to the fallopian tubes because of pelvic infections, pelvic surgery, or previous ectopic pregnancy, and in smokers.^{4,5}

Throughout this case, authors learned and understand what to do when authors met patients with ruptured ectopic pregnancy, supported by signs and symptoms from history taking, physical examination, vaginal gynecologic examination, and additional sonography examination.

A lot of patients have several symptoms that mimic the ectopic pregnancy, so both knowledge and experience to differentiate these emergency cases are needed. A correct diagnosis is needed so authors can prevent mortality in the patients.

CONCLUSION

Laparoscopic surgery is the first choice in cases of ruptured ectopic pregnancy, especially if the conditions are good. There's no complication during and after an operation. The patient's condition is stable. This is an interesting case to learn. Ruptured ectopic pregnancy itself is a rare case, however, this patient had to through twice.

Funding: No funding sources

Conflict of interest: None declared

Ethical approval: Not required

REFERENCES

1. Ko PC, Liang CC, Lo TS, Huang HY. Six cases of tubal stump pregnancy: complication of assisted reproductive technology?. *Fertil Steril.* 2011;95(7):2432-e1.
2. Perkins KM, Boulet SL, Kissin DM, Jamieson DJ, National ART Surveillance (NASS) Group. Risk of ectopic pregnancy associated with assisted reproductive technology in the United States, 2001-2011. *Obstet Gynecol.* 2015;125(1):70.
3. Takeda A, Hayashi S, Imoto S, Sugiyama C, Nakamura H. Pregnancy outcomes after emergent laparoscopic surgery for acute adnexal disorders at

less than 10 weeks of gestation. *J Obstetr Gynaecol Res.* 2014;40(5):1281-7.

4. American College of Obstetricians and Gynecologists. ACOG Practice Bulletin No. 193: tubal ectopic pregnancy. *Obstet Gynecol.* 2018;131(3):e91-103.
5. Jena SK, Singh S, Nayak M, Das L, Senapati S. Bilateral simultaneous tubal ectopic pregnancy: a

case report, review of literature and a proposed management algorithm. *J Clini Diag Res: JCDR.* 2016;10(3):QD01.

Cite this article as: Pramana C, Angelina A, Hilwa NS, Munandar AN, Lukas A, Hosein I. Recurrent ruptured ectopic pregnancy: a case report. *Int Surg J* 2020;7:1641-3.