

Original Research Article

Retrospective study of mesenteric ischemia

Mallikarjuna Reddy Mandapati, Sanjeev Kumar Jukuri*,
Nageswara Rao Nasika, Haleema Neshat

Department of General Surgery, NRI General Hospital, Chinakakani, Guntur, Andhra Pradesh, India

Received: 05 February 2020

Revised: 08 July 2020

Accepted: 10 July 2020

***Correspondence:**

Dr. Sanjeev Kumar Jukuri,

E-mail: drsanjeevjukuri@gmail.com

Copyright: © the author(s), publisher and licensee Medip Academy. This is an open-access article distributed under the terms of the Creative Commons Attribution Non-Commercial License, which permits unrestricted non-commercial use, distribution, and reproduction in any medium, provided the original work is properly cited.

ABSTRACT

Background: Acute mesenteric ischemia (AMI) is typically defined as a group of diseases characterized by an interruption of the blood supply to varying portions of the small intestine, leading to ischemia and secondary inflammatory changes.

Methods: A monocentric retrospective study was conducted between 01 August 2013 and 31 December 2019; 24 AMI patients underwent surgery (17 men and 7 women). Retrospectively, the risk factors, management until diagnosis and mortality were evaluated.

Results: Patients present with an acute pain of the abdomen. Diagnosis was provided by CT with contrast medium. The 30-day mortality was 45.8%, the late mortality was 25% and the overall mortality was 70.8%. For the <12 hours delay group, the mortality was 33.3%, and the mortality in the group with 12-24 hours delay was 80% and was 87.5% in the >24 hours after admission group.

Conclusions: If untreated, this process will eventuate in life threatening intestinal necrosis. The incidence is low, estimated at 0.09-0.21% of all acute surgical admissions.

Keywords: Mesenteric embolism, Mesenteric infarction, Mesenteric ischemia, Mesenteric thrombosis

INTRODUCTION

Mesenteric ischemia is an uncommon condition with high morbidity and mortality that results from inadequate blood flow in the mesenteric circulation for the metabolic needs of the visceral organs, and if untreated, eventually leads to necrosis of the bowel wall. AMI may be non-occlusive (NOMI) or occlusive, mainly due to mesenteric arterial embolism (50%), mesenteric arterial thrombosis (15-25%), or mesenteric venous thrombosis (5-15%).^{1,2}

Acute mesenteric arterial embolism

Roughly, 50% of all cases of AMI are due to acute mesenteric embolism.^{1,2} Emboli typically lodge at the

normal anatomic narrowing, and the SMA is vulnerable because of its large diameter and low take off angle from the aorta. In most of the cases, the emboli lodge 3 to 10 cm distal to the origin of the SMA, sparing the proximal jejunum and colon.

Acute mesenteric arterial thrombosis

Thrombosis of the SMA (approximately 25% of cases) is usually associated with pre-existing chronic atherosclerotic disease leading to stenosis. Symptoms in chronic cases include postprandial pain, or 'food fear', weight loss, and thus a systematic history is required when evaluating a suspected AMI patient. Symptomatic SMA thrombosis often accompanies celiac occlusion.³

Non-occlusive mesenteric ischemia

NOMI occurs in about 20% of cases and is usually a result of SMA vasoconstriction associated with poor splanchnic blood flow.⁴ Patients typically have severe coexisting illness, commonly cardiac failure which may be precipitated by sepsis. Hypovolemia and use of vasoconstrictive agents may precipitate NOMI.

Mesenteric venous thrombosis

Mesenteric venous thrombosis (MVT) accounts for less than 10% of cases of mesenteric infarction, approximately 20% are idiopathic. Hypercoagulability may be due to inherited disease such as Factor V Leiden, protein S deficiency, protein C deficiency, antithrombin deficiency, prothrombin mutation and antiphospholipid syndrome. Other significant risk factor for hypercoagulability is fibrinolysis shutdown (resistance to tissue plasminogen activator (tPA)).⁵ The presentation of a patient with excruciating abdominal pain and an unrevealing abdominal examination is classic for early AMI.⁶ In a study about AMI, 95% of patients presented with abdominal pain, 44% with nausea, 35% with diarrhoea, 35% with vomiting, and 16% with blood per rectum.⁷ Plain radiography may help, becomes positive when bowel infarction with intestinal perforation manifests as free intraperitoneal air. The second most common abnormal finding is the metabolic acidosis with elevated lactate level, which occurred in 88%.⁸ Elevated serum lactate levels of more than 2 mmol/l was associated in irreversible intestinal ischemia in established diagnosis of AMI.⁹ An elevated amylase has been reported in roughly a half of patients with AMI.¹⁰ Delay in diagnosis is the major factor that accounts for high mortality rates of 30-70% despite having vast clinical experience and recognition of this entity.^{11,12}

Aims and objectives

Evaluating the cases of mesenteric ischemia- risk factors, management, diagnosis, outcome, morbidity and mortality.

METHODS

This was a retrospective analysis, conducted at NRI Medical College and General Hospital, Guntur district, Andhra Pradesh, a total of 24 patients with AMI between August, 2013 and December, 2019 were evaluated. During the surgery, resection of the ischemic segment and end ostomy was created.

Inclusion criteria

All cases diagnosed as mesenteric ischemia.

Exclusion criteria

Patients who developed AMI as a complication of other operations or interventions were excluded from the study.

Ethical approval

The study was approved by the Institutional Ethics Committee.

Statistical analysis

Logistic regression for risk factors analysis was performed. The level of significance was defined at $p < 0.05$. The relationships between delay interval and survival were assessed using the Kruskal-Wallis- and χ^2 -tests, as well as by cross tables.

RESULTS

In our study of 6 years, patients presented with an acute pain in the abdomen. Diagnosis was provided by CT with contrast medium. Altogether, a total of 19 out of 24 patients (79%) had leukocytosis ($>10\,000/\mu\text{l}$), 20 out of 24 patients (83%) had an increase of C-reactive protein ($>0.5\text{ mg/dl}$) and 15 out of 20 patients (75%) had an increase of L-lactate ($>1.6\text{ mmol/l}$). Risk factors are summarized in Table 1.

Table 1: Risk factors (n=24).

Variable	N (%)	P value
Age (years)		
< 50	7 (29.1)	0.039
>50	17 (70.8)	
Gender		
Male	17 (70.8)	0.423
Female	7 (29.1)	
Hypertension	11 (45.8)	0.213
Coronary heart disease	8 (33.3)	0.799
Diabetes mellitus	11 (45.8)	0.249
Hyperlipidemia	7 (29.1)	0.376
Smoking history	8 (33.3)	0.135
Alcohol consumption	7 (29.1)	0.416
Peripheral vascular disease	6 (12.5)	0.041

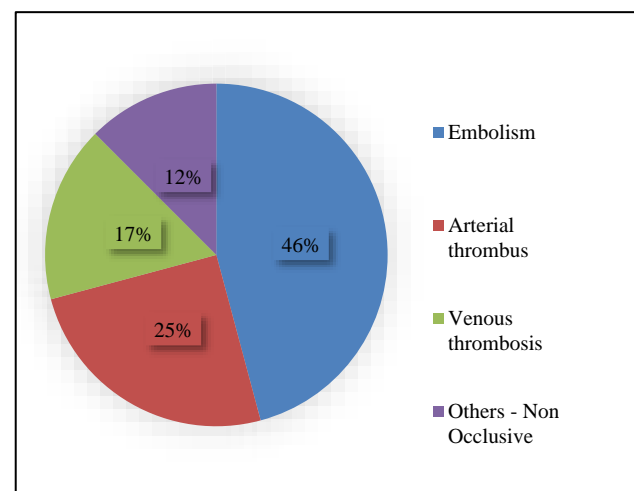


Figure 1: Causes of occlusion.

During the surgery, resection of the ischemic segment and end ostomy was created. The 30-day mortality was 45.8%, the late mortality was 25% and the overall mortality was 70.8%. For the presentation in <12 hours delay group, the mortality was 33.3%, and the mortality in the group with presentation 12-24 hours delay was 80% and was 87.5% in the >24 hours after admission group. Causes of death in the early phase (<30 days) included necrosis of the gut, multi-organ failure. While in the late phase (>30 days), the causes of death included ischemia of the gut, and unclear cause of death. 7 patients survived the AMI, during follow-up, one patient complained about diarrhea and another patient suffered from nausea.

Causes of occlusion and mortality depending on age and time of presentation are depicted in Figures 1, 2, and 3.

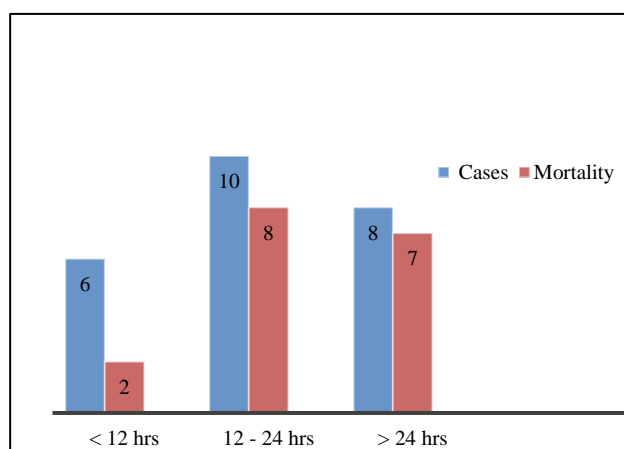


Figure 2: Mortality depending on time of presentation.

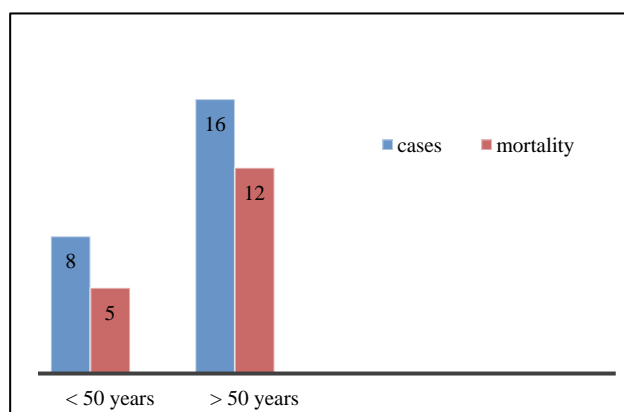


Figure 3: Mortality depending on age.

DISCUSSION

In mesenteric ischemia, the vascular insufficiency can be acute or chronic, arterial or venous insufficiency, occlusive or non occlusive. Predisposing factors include the pre-existing cardiovascular disease, recent abdominal vascular surgery, hypercoagulable states, diabetes

mellitus, vasculitis, medications (vasopressins, digoxin), smoking and alcohol. Symptoms are out of proportion to signs. Post prandial abdominal pain, distension, vomiting, blood in stools, weight loss. In >75% of cases, the ischemia is self-limiting and resolves without any incident, some may develop stricture. In 15 to 20% of cases, features of progressive ischemia and gangrene. CECT abdomen is the investigation of choice, shows a thickened bowel wall along with mucosal changes and ischemic changes with collaterals, mesenteric edema and stranding. Marked leukocytosis, acidosis with elevated lactic acid levels. Fever, tachycardia and hypotension, features of peritonitis indicate a failure of the ischemia to resolve and the need for surgical intervention. During the surgery, resection of the ischemic segment and end ostomy is created. Arriving at an early diagnosis, prior to the development of bowel necrosis with peritonitis, is one of the most important prognostic factors.¹³ In suspected AMI cases, the emergency diagnosis should include the biphasic contrast computed tomography (CECT) with multi-planar reconstruction. The venous phase of CT is necessary for the diagnosis of mesenteric vein thrombosis.¹⁴ In this study, CT with contrast agents was the gold standard, having replaced conventional angiography as the imaging modality of choice. Serum lactate is often helpful in the diagnosis. An elevated lactate level (>2.2 mmol/l) reflects the late phase of AMI with a transmural bowel infarction. The endovascular treatment option is advised only in patients without peritonitis.¹⁵ Open surgery can be used in patients with peritonitis in the late phase of AMI. In cases of advanced AMI, the CTA findings reflect irreversible ischemia (intestinal dilatation and wall thickness, reduction or absence of the visceral enhancement, pneumatosis intestinalis, and portal venous gas) and free intraperitoneal air.¹⁶ In MVT, the most common positive radiological finding on the venous phase CTA is thrombus in superior mesenteric vein on venous phase CTA, described as the target sign.¹⁷ Right-sided abdominal pain associated with passage of maroon or bright red blood in the stool is highly suggestive of NOMI in these patients. When the diagnosis of AMI is made, adequate fluid resuscitation should commence immediately to enhance visceral perfusion. Assessment of electrolyte levels and acid-base status should be done. Broad-spectrum antibiotics should be administered immediately. The goal of surgical intervention for the AMI include: 1) Re-establishment blood supply to the ischemic bowel. 2) Resection of all non-viable regions. 3) Preservation of all viable bowel. Endovascular revascularization procedures may have a role in partial arterial occlusion. Only patients who did not require open emergency intervention are suitable for this technical approach to revascularization. Damage control surgery is the surgical modality of choice in the critically ill patient with AMI for physiological and technical reasons. The first-line treatment for the mesenteric venous thrombosis is anticoagulation. Studies have shown that early use of heparin has been associated with improved survival.¹⁸ A second-look procedure is mandatory in the patients who

have extensive bowel involvement. Systemic intravenous tPA has been successfully reported.¹⁹ A preoperative discussion with the patient and also with the patient's family concerning these issues is required and often necessary peri-operatively so that an agreeable plan can be reached.²⁰

CONCLUSION

Mesenteric ischemia is a relatively uncommon cause of abdominal pain, but with a significant morbidity and mortality. In the proper clinical setting, a high index of suspicion to be maintained so that a correct diagnosis may be made and treatment is initiated at the earliest. Employment of the damage control techniques and continued critical care resuscitation are crucial. Planned re-assessment of the bowel is done with further resection or anastomosis and the stoma as needed is integral. Close cooperation between acute care surgeons, radiologists, anaesthetists, and the vascular surgeons is essential.

ACKNOWLEDGEMENTS

Authors are thankful to MRD department for providing valuable inputs related to these cases.

Funding: No funding sources

Conflict of interest: None declared

Ethical approval: The study was approved by the Institutional Ethics Committee

REFERENCES

1. Acosta S. Mesenteric ischemia. *Curr Opin Crit Care*. 2015;21:171-8.
2. Clair DG, Beach JM. Mesenteric ischemia. *N Engl J Med*. 2016;374:959-68.
3. Kärkkäinen JM, Acosta S. Acute mesenteric ischemia (part I)- incidence, etiologies, and how to improve early diagnosis. *Best Pract Res Clin Gastroenterol*. 2017;31:15-25.
4. Aschoff AJ, Stuber G, Becker BW, Hoffmann MH, Schmitz BL, Schelzig H, et al. Evaluation of acute mesenteric ischemia: accuracy of biphasic mesenteric multi-detector CT angiography. *Abdomin Imag*. 2009;34:345-57.
5. Moore HB, Moore EE, Lawson PJ, Gonzalez E, Fragoso M, Morton AP, et al. Fibrinolysis shutdown phenotype masks changes in rodent coagulation in tissue injury versus haemorrhagic shock. *Surgery*. 2015;158:386-92.
6. Carver TW, Vora RS, Taneja A. Mesenteric ischemia. *Crit Care Clin*. 2016;32: 155-71.
7. Park WM, Gloviczki P, Cherry KJ Jr, Hallett JW Jr, Bower TC, Panneton JM, et al. Contemporary management of acute mesenteric ischemia: Factors associated with survival. *J Vasc Surg*. 2002;35:445-52.
8. Kougiass P, Lau D, El Sayed HF, Zhou W, Huynh TT, Lin PH. Determinants of mortality and treatment outcome following surgical interventions for acute mesenteric ischemia. *J Vasc Surg*. 2007;46:467-74.
9. Nuzzo A, Maggiori L, Ronot M, Becq A, Plessier A, Gault N, et al. Predictive factors of intestinal necrosis in acute mesenteric ischemia: prospective study from an intestinal stroke center. *Am J Gastroenterol*. 2017;112:597-605.
10. Wilson C, Imrie CW. Amylase and gut infarction. *Br J Surg*. 1986;73:219-21.
11. Bradbury AW, Brittenden J, McBride K, Ruckley CV. Mesenteric ischaemia: a multidisciplinary approach. *Br J Surg*. 1995;82:1446-59.
12. Kassahun WT, Schulz T, Richter O, Hauss J. Unchanged high mortality rates from acute occlusive intestinal ischemia: six year review. *Langenbeck's Arch Surg*. 2008;393:163-71.
13. Aliosmanoglu I, Gul M, Kapan M, Arikanoğlu Z, Taskesen F, Basol O, et al. Risk factors effecting mortality in acute mesenteric ischemia and mortality rates: a single centre experience. *Int Surg*. 2013;98:76-81.
14. Kellow ZS, MacInnes M, Kurzenecwyg D, Rawal S, Jaffer R, Kovacina B, et al. The role of abdominal radiography in the evaluation of the non-trauma emergency patient. *Radiology*. 2008;248:887-93.
15. Klar E, Rahmanian PB, Bucker A, Hauenstein K, Jauch KW, Luther B. Acute mesenteric ischemia: a vascular emergency. *Deutsches Arzteblatt Int*. 2012;109(14):249-56.
16. Kirkpatrick ID, Kroeker MA, Greenberg HM. Biphasic CT with mesenteric CT angiography in the evaluation of acute mesenteric ischemia: initial experience. *Radiology*. 2003;229:91-8.
17. David RA, Erben Y, Kalra M. Clinical presentation, etiology, and diagnostic considerations. In: Oderich G, editor. *Mesenteric Vascular Disease*. New York: Springer; 2015:199-209.
18. Acosta S. Surgical management of peritonitis secondary to acute superior mesenteric artery occlusion. *World J Gastroenterol*. 2014;20:9936-41.
19. Hmoud B, Singal AK, Kamath PS. Mesenteric venous thrombosis. *J Clin Exp Hepatol*. 2014;4:257-63.
20. Lilley EJ, Cooper Z, Schwarze ML, Mosenthal AC. Palliative care in surgery: defining the research priorities. *J Palliat Med*. 2017;20:702-9.

Cite this article as: Mandapati MR, Jukuri SK, Nasika NR, Neshat H. Retrospective study of mesenteric ischemia. *Int Surg J* 2020;7:2544-7.