

## Case Report

# A giant thrombosed isolated femoral artery aneurysm: a rare entity

Gajulapalli Prudhvi Vardhan Reddy<sup>1</sup>, Siddhant Shrotriya<sup>1</sup>, Nitin J. Pathak<sup>2\*</sup>

<sup>1</sup>Department of General Surgery, <sup>2</sup>Department of Vascular Surgery, Bharati Vidyapeeth Deemed University Medical College, Pune, Maharashtra, India

**Received:** 18 January 2020

**Accepted:** 06 March 2020

**\*Correspondence:**

Dr. Nitin J. Pathak,

E-mail: nitpat18@gmail.com

**Copyright:** © the author(s), publisher and licensee Medip Academy. This is an open-access article distributed under the terms of the Creative Commons Attribution Non-Commercial License, which permits unrestricted non-commercial use, distribution, and reproduction in any medium, provided the original work is properly cited.

### ABSTRACT

A 70-year-old woman was admitted to the hospital due to a swelling on her right inner thigh that was evident for six months. She had a history of trauma few months back, also history of stroke on anti-platelet treatment. Ultrasound of thigh suggestive of thrombosis in right femoral artery. Doppler suggestive of aneurysm of right femoral artery with thrombus. Right femoral artery aneurysm excision and thrombectomy done.

**Keywords:** Aneurysm, Arteries, Femoral

### INTRODUCTION

A vessel is considered to be aneurysmal when it enlarges to about one and a half to two times the size of the normal vessel. True femoral artery aneurysms are rare and include dilation of all the layers of the vessel wall. They may mimic as groin hernia or lymphadenopathy. Most of the femoral artery aneurysms are seen in male and older than 70 years.<sup>1</sup> Hardy and Eadie first reported an SFA aneurysm in a 70-year-old man in 1972.<sup>2</sup> Studies of aneurysms of the SFA have shown a rupture rate of 35% to 48%, a thrombosis rate of 13% to 18%, an embolism rate of 9% to 12%, and limb salvage in 94% of cases.<sup>3</sup>

Risk factors for femoral artery aneurysms include smoking, arteriosclerosis, high blood pressure, and systemic connective tissue disorders. Ultrasound is a noninvasive first line of investigation for aneurysms. CT is an accurate and effective diagnostic tool for defining the size, configuration, internal nature of the aneurysm, and the condition of adjacent vessels other than the SFA.

### CASE REPORT

A 70-year-old woman presented in the OPD with chief complaints of swelling in right inner thigh which was

progressive in nature. She had a history of trauma 6 months back. She had a co morbidities of hypertension and history of stroke for which she was on regular treatment.

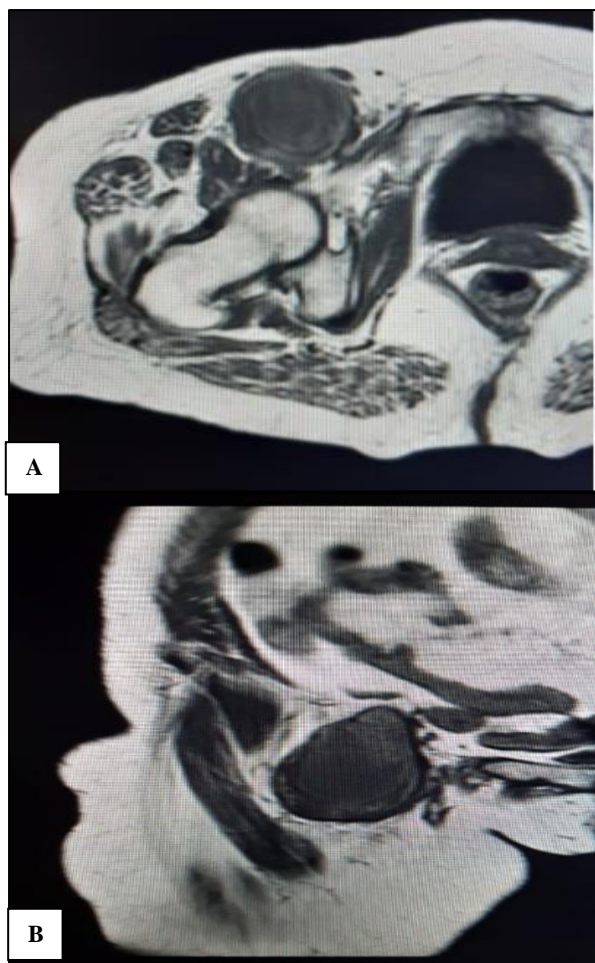
General examination revealed no significant findings. Peripheral pulsation of right lower limb could not be palpated. She had 8cmx8cm swelling in groin and limb was cold with blackish discoloration of left great toe

#### Image findings

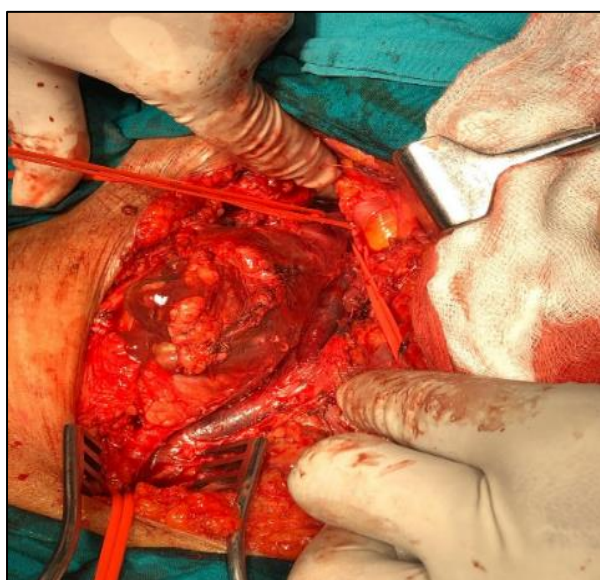
MRI of right inguinal region. The common femoral artery shows aneurysm in the right inguinal region measuring 4.5x4.6 cm in size. The external iliac and superficial femoral arteries are normal.

Arterial doppler of right lower limb: There is thrombosed aneurysm of common femoral artery measuring 7.7x4.1x5.6 cm. Proximally it is extending into external iliac artery. There is occlusion of superficial femoral, popliteal arteries and the anterior tibial artery showing no flow (Figure 1).

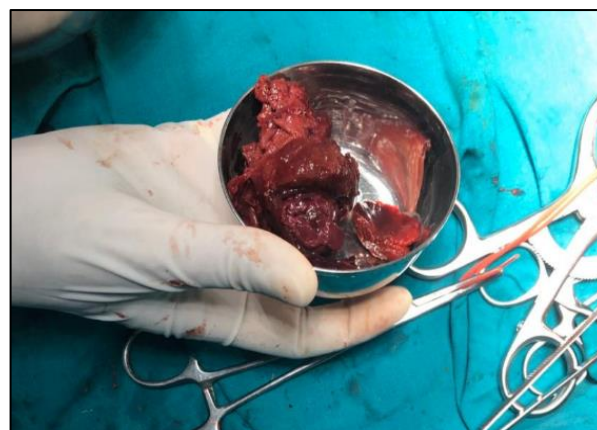Figures 2 and 3 shows important findings.



**Figure 1 (A and B): Images of MRI showing right femoral artery aneurysm with large thrombus in situ.**



**Figure 2: The picture of right inguinal region shows laterally a giant femoral artery aneurysm around 7 cm×4 cm and medially normal femoral vein**



**Figure 3: Excised giant thrombus from femoral artery aneurysm.**

### DISCUSSION

Femoral aneurysms can reach a large size and via thrombosis can create symptoms such as limb-threatening ischemia, embolization, or tissue loss; however, rupture is rarely encountered.

Femoral aneurysm after groin procedures like cardiac catheterization (0.1-5%), vascular reconstruction 1-10% is quite common, but not reported after hernia repair.<sup>4,5</sup> Despite their rarity and the frequent presentation in an emergency context with rupture or thrombosis, outcomes are typically favorable; the resection of the SFA aneurysm is easily accomplished in most of the cases, and the reconstruction can often be performed with a prosthetic graft but in our case we didn't use graft because of good collaterals.

### CONCLUSION

In conclusion, a case report was presented of an isolated common femoral artery aneurysm as unusual groin lump. Duplex scan is the investigation of choice. Surgery is recommended in aneurysm greater than 2.5 cm in view of high rate of complications.

*Funding: No funding sources*

*Conflict of interest: None declared*

*Ethical approval: Not required*

### REFERENCES

1. Dimakakos PB, Tsiligiris V, Kotsis T, Papadimitriou JD. Atherosclerotic aneurysms of the superficial femoral artery: report of two ruptured cases and review of the literature. *Vasc Med.* 1998;3:275-9.
2. Hardy DF, Eadie DGA. Femoral aneurysms. *Br Surg.* 1972;59:614-6.
3. Atallah C, Hassan HK, Negleu P. Superficial femoral artery aneurysm-an uncommon site of

aneurysm formation. *Eur J Vasc Endovasc Surg.* 1995;10:502-4.

4. Sawyers JL, Jacobs JK, Sutton JP: Peripheral anastomotic aneurysms. Development following arterial reconstruction with prosthetic grafts. *Arch Surg.* 1967;95:802.
5. Agarwal BB, Gupta MK, Agarwal S, Mahajan KC: Spontaneous rupture of iatrogenic (postinguinal herniorrhaphy) venovenous malformation managed

endoscopically. *J Laparoendosc Adv Surg Tech A.* 2008;18:80-3.

**Cite this article as:** Reddy GPV, Shrotriya S, Pathak NJ. A giant thrombosed isolated femoral artery aneurysm: a rare entity. *Int Surg J* 2020;7:1652-4.