

Case Report

Spontaneous rupture of neurogenic bladder

Vinodh Duraismy, Mishall Prasannan*, Maniselvi Swamidurai, Kannan Ross

Institute of General Surgery, Madras Medical College, Chennai, Tamil Nadu, India

Received: 12 January 2020

Revised: 27 January 2020

Accepted: 28 January 2020

***Correspondence:**

Dr. Mishall Prasannan,

E-mail: mishall.93@gmail.com

Copyright: © the author(s), publisher and licensee Medip Academy. This is an open-access article distributed under the terms of the Creative Commons Attribution Non-Commercial License, which permits unrestricted non-commercial use, distribution, and reproduction in any medium, provided the original work is properly cited.

ABSTRACT

Pneumoperitoneum is abnormal presence of air or any other gas in the peritoneal cavity. This finding can be both benign or a sign of a grave underlying pathology and a wide spectrum of clinical conditions can attribute to the finding. Prompt clinical examination of a case of abdominal pain can identify findings of peritonitis. We are reporting an interesting case report about a patient of acute abdomen with pneumoperitoneum and peritonitis which was caused by spontaneous rupture of urinary bladder. A 36-year-old male, came with complaints of abdominal pain for one day, two episodes of non-bilious vomiting. He was a known case of neurogenic bladder on continuous bladder drainage. Systemic examination of the abdomen showed warmth, diffuse tenderness, guarding and absent bowel sounds. Bladder catheterisation showed clear urine. On investigation, He had pneumoperitoneum in chest X-ray and free fluid in ultrasonography. A clinical diagnosis of hollow viscus perforation was made and emergency laparotomy was done in view of signs of peritonitis. There was rupture of the dome of urinary bladder with necrosis of the bladder wall and extravasation of urine into the peritoneal cavity. This rare presentation should remind us to keep all the differential diagnoses in mind while opening a case of perforation peritonitis as timely intervention can well and truly be the difference between life and death.

Keywords: Spontaneous urinary bladder rupture, Pneumoperitoneum, Neurogenic bladder

INTRODUCTION

Pneumoperitoneum is abnormal presence of air or any other gas in the peritoneal cavity. The most common cause is a perforation of the abdominal viscus, most commonly a perforated ulcer, although a pneumoperitoneum may occur as a result of perforation of any part of the bowel. This finding can be both benign or a sign of a grave underlying pathology and a wide spectrum of clinical conditions can attribute to the finding.¹ Prompt clinical examination of a case of abdominal pain can identify findings of peritonitis.² Among the investigations, radiological images showing air within the peritoneal cavity is one of the earliest and most accurate findings of a hollow viscus perforation.³ Spontaneous urinary bladder rupture is a very rare finding. It is usually caused by malignancies, post

radiotherapy, during strenuous vaginal delivery, and very rarely in cases of hemophilia and indwelling foleys catheter. We report a rare case of neurogenic bladder presenting with abdominal pain, who had pneumoperitoneum and features of peritonitis, and showed spontaneous rupture of the urinary bladder into the peritoneal cavity.

CASE REPORT

A 36-year-old male, came with complaints of abdominal pain for one day, two episodes of non-bilious vomiting. He was a known case of neurogenic bladder on continuous bladder drainage. He had no history of any previous surgeries. On examination, he had tachycardia. Systemic examination of the abdomen showed warmth, diffuse tenderness, guarding and absent bowel sounds.

Bladder catheterisation showed clear urine. On investigation, He had pneumoperitoneum in chest X-ray and free fluid in ultrasonography.

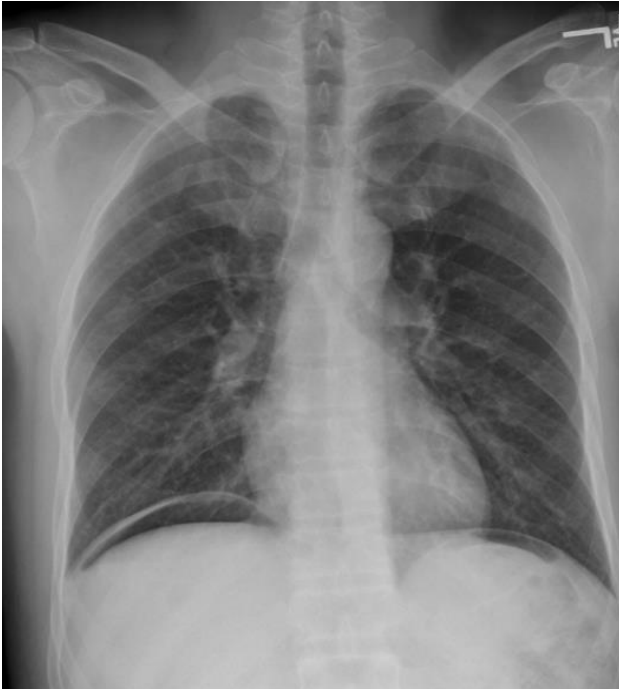


Figure 1: Chest X-ray showing air under the right hemidiaphragm.

A clinical diagnosis of hollow viscus perforation was made and emergency laparotomy was done in view of signs of peritonitis. There was rupture of the dome of urinary bladder with necrosis of the bladder wall and extravasation of urine into the peritoneal cavity.

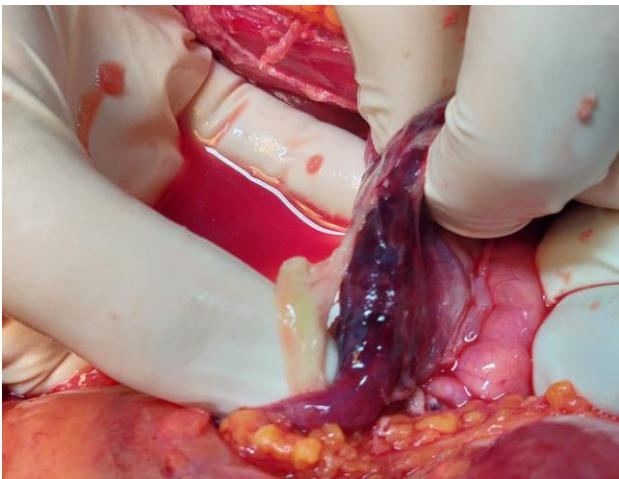


Figure 2: Necrosed dome of urinary bladder.

Rest of the abdominal viscera was normal. Debridement of unhealthy tissue of the urinary bladder was done till fresh bleed was visualised. Primary repair of the bladder dome was done in two layers using continuous absorbable sutures. A suprapubic cystostomy was done

and continuous bladder drainage was established. Routine urethral catheterisation was also done. The patient had an uneventful post-operative period and was discharged after a week.

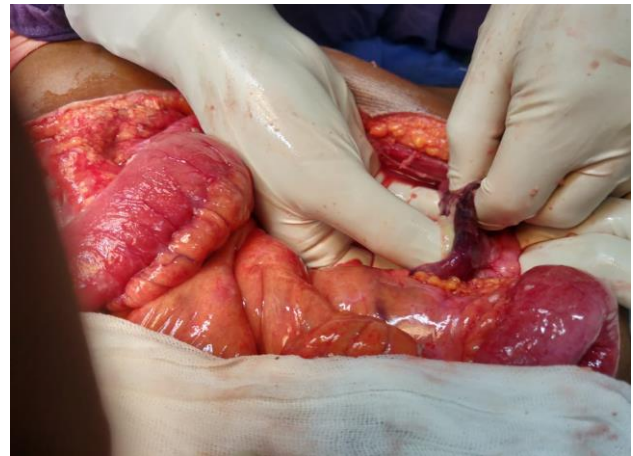


Figure 3: Surgeon's hand passing through the urinary bladder perforation.

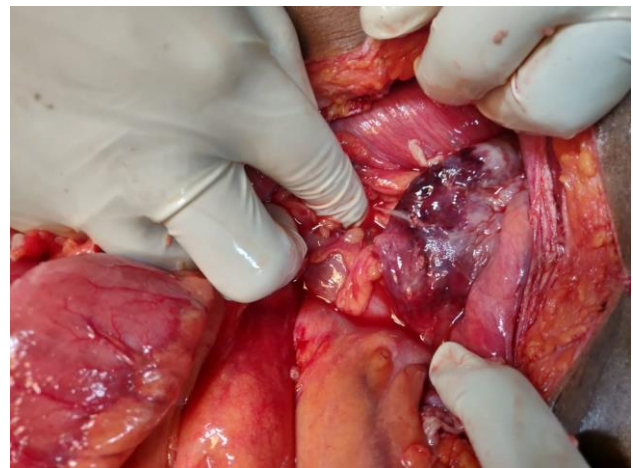


Figure 4: Bladder wall showing patchy necrosis.

DISCUSSION

Neurogenic bladder has caused filling up of bladder to such an extent that it caused pressure necrosis to the dome of the bladder, which is the part most prone for perforation. This in turn, has led to urinary contamination of the peritoneum and presenting to us with features of peritonism. The pneumoperitoneum which occurred happened to be a benign finding, which lead us to go for an exploratory laparotomy. There has only been a single case report in the *Journal of Emergency Medicine - American Academy of Emergency Medicine* which showed an indwelling urinary catheter for prolonged duration to be a causative factor of perforation of urinary bladder.⁴ This rare presentation should remind us to keep all the differential diagnoses in mind while opening a case of perforation peritonitis as timely intervention can well and truly be the difference between life and death.⁵

CONCLUSION

Peritonitis caused by hollow viscus perforation is usually a very hazardous course of disease where the delay in presentation and delay in diagnosis from our part plays a crucial role in determining the survival of the patient. In such a scenario, we should also be prepared to tackle rare causes of pneumoperitoneum such as our case scenario. Bladder rupture, being easy to diagnose and repair intraoperatively, lead to a relatively stable post-operative course for this patient's recovery.

Funding: No funding sources

Conflict of interest: None declared

Ethical approval: Not required

REFERENCES

1. D'Agostino S, Fabbro MA, Musi L, Bozzola L. Pneumatosis cystoides intestinalis – A rare cause of

- pneumoperitoneum in an infant. J Pediatr Surg. 2000;35(7):1106-8.
2. Omori H, Asahi H, Inoue Y, Irinoda T, Saito K. Pneumoperitoneum without perforation of the GI tract. Dig Surg. 2003;20(4):334-8.
3. Mularski RA, Ciccolo ML, Rappaport WD. Nonsurgical causes of pneumoperitoneum. West J Med. 1999;170(1):41-6.
4. Zang C, et al. JEM. 2017;50(12):410-1.
5. Salky BA, Kaynon A, Bauer JJ, Gelernt IM, Kreel I. Ruptured hepatic abscess: a rare cause of spontaneous pneumoperitoneum. Am J Gastroenterol. 1982;77(11):880-1.

Cite this article as: Duraisamy V, Prasannan M, Swamidurai M, Ross K. Spontaneous rupture of neurogenic bladder. Int Surg J 2020;7:908-10.