

## Original Research Article

# Combined liver-visceral resection for neoplastic lesions correlates with increased postoperative complications

Ashraf Mohammad El-Badry, Mohamed Mahmoud Ali\*

Department of Surgery, Sohag University Hospital, Faculty of Medicine, Sohag University, Sohag, Egypt

**Received:** 14 January 2020

**Accepted:** 04 March 2020

### \*Correspondence:

Dr. Mohamed Mahmoud Ali,

E-mail: [drmohamedmahmoud1969@gmail.com](mailto:drmohamedmahmoud1969@gmail.com)

**Copyright:** © the author(s), publisher and licensee Medip Academy. This is an open-access article distributed under the terms of the Creative Commons Attribution Non-Commercial License, which permits unrestricted non-commercial use, distribution, and reproduction in any medium, provided the original work is properly cited.

## ABSTRACT

**Background:** Combined liver-visceral resections (CLVRs) may impose increased risk of postoperative complications. The clinical outcome of CLVRs versus sole liver resection (SLR) has not been adequately reported from upper Egypt cancer surgery programs.

**Methods:** Medical records of adult non-cirrhotic patients who electively underwent liver resection from February 2015 to April 2018 at Sohag University Hospital, Egypt, were retrospectively reviewed. Indications for liver resection comprised definitively malignant tumors and those with equivocal radiologic features. The severity of surgical complications, including mortality, was compared among patients who underwent CLVRs versus SLR control group with matching age, gender, number of resected liver segments, method of hepatic inflow occlusion and parenchyma transection techniques.

**Results:** Twenty-six patients were enrolled, including 13 with CLVRs group and their 13 SLR control group. Histopathologic examination of resected specimens confirmed malignancy in 17 patients (10 in CLVR group and 7 in SLR group). Major liver resection ( $\geq 3$  segments) was carried out in 14 (54%) patients, 7 per each group. The complication score was significantly higher in CLVRs ( $p < 0.05$ ). Similarly, the length of hospital and intensive care unit stays was significantly prolonged in CLVRs group ( $p < 0.05$ ). Overall, 2 patients died (8%), exclusively in the CLVRs. Elderly patients ( $> 65$  years) who underwent CLVRs exhibited increased complications compared with their matching controls.

**Conclusions:** CLVR predisposes to increased morbidity rates and mortality. It should be carried out in carefully selected patients to avoid worse clinical outcome.

**Keywords:** Colorectal liver metastasis, Liver resection, CLVRs

## INTRODUCTION

The recent decades have witnessed remarkable advances in oncologic surgery of the liver which represents the most common site of metastasis particularly from colorectal origin.<sup>1</sup> About 20% of colorectal cancer patients present with synchronous liver metastases.<sup>2</sup> Among those patients, 80% have initially unresectable metastases.<sup>3</sup> Liver resection for metastasis from other organs may have less favorable outcome.<sup>4</sup> New surgical

strategies, chemotherapy regimens and interventional procedures are widely applied particularly for patients with extensive liver metastases to widen the opportunity of curative resection.<sup>5</sup> Parenchyma-augmenting procedures such as occlusion of the portal vein via embolization or surgical ligation, staged liver resections and associating liver partitioning and portal vein ligation for staged hepatectomy (ALPPS) have enabled major curative resection that were otherwise impossible. Among interventional approaches, tumor ablation using

radiofrequency, microwave and cryotherapy were frequently applied either alone or in conjunction with surgery.<sup>6</sup> Furthermore, preoperative chemotherapy alone or in combination with targeted treatments have remarkably contributed to downsizing of liver metastases and enhancing resectability.<sup>7</sup>

In the setting of colorectal cancer with synchronous liver metastasis, three different strategies are currently available, among which the classic and reverse strategies were described as staged resections. The classic strategy entails initial removal of the primary colon or rectal cancer and subsequent resection of liver metastases in a second stage. In the reverse “liver first” approach, liver metastasis is approached in the first stage followed by later resection of the primary cancer.<sup>8</sup> The third approach refers to simultaneous resection of the primary tumor and liver metastases combined in a single operation.<sup>9</sup>

Conflicting results on the clinical outcome were reported when combined resections were compared with sole liver resection. For instance, equal mortality rates were reported among patients who underwent combined resection of the liver and colorectal tumors and those who had liver only resection either during the classic or reverse approach.<sup>10,11</sup> However, another study showed that contrary to the classic approach, combined resections are associated with higher morbidity and mortality.<sup>6,12</sup> Moreover, contradictory results were shown with respect to the influence of combined liver-colorectal versus sole liver resection on major postoperative complications.<sup>6,9,10,13</sup>

The conflicting data extend also to the influence of the classic and reverse approach on postoperative complications and mortality. Among patients who underwent the classic versus reverse approach, no significant difference was found regarding postoperative liver insufficiency, bile leak, bleeding and infection. Ninety-day mortality following either approach was also not significantly different.<sup>14</sup> In contrast, another study reported that the reverse approach results in remarkably higher mortality rates at 90 and 180 days after surgery in comparison with the classic strategy.<sup>6</sup>

Since establishment of the oncologic liver surgery program at Sohag University Hospital, Egypt on 2012, the impact of CLVRs was not adequately addressed. Therefore, we carried out the current study to explore the clinical outcome, including postoperative morbidity and mortality, after CLVRs versus SLR.

## METHODS

Medical records of consecutive adult patients who underwent liver resection (February 2015 to April 2018) at Sohag University Hospital were retrospectively reviewed. Adult (>18-year-old) non-cirrhotic patients with American Society of Anesthesiologists (ASA) score of I, who underwent CLVRs electively and their controls

with age, gender, number of resected liver segments, method of liver inflow occlusion and parenchyma transection technique, who had sole liver resection a variety of hepatic masses were enrolled. All patients were managed by the same team of surgeons and anesthesiologists. Preoperatively, all patients were thoroughly evaluated in standardized manner including comprehensive analysis clinical data, relevant family history and routine clinical examination. Regular laboratory work-up comprised full blood count, plasma levels of bilirubin, albumin, liver enzymes, creatinine, glucose level and viral serology for hepatitis B and C. Coagulation profile was initially evaluated by determination of prothrombin time and concentration. A panel of tumor markers including carcinoembryonic antigen, carbohydrate antigen 19:9 and alfa fetoprotein was consistently ordered. Abdominal ultrasonography was performed primarily to identify the number and location of parenchymal and/or vascular lesions while triphasic computerized tomography (CT) scans were used for precise characterization and localization of the liver masses in relation to hepatic vasculature. Contrast enhanced CT of the chest was carried out in all patients with liver metastasis to detect any lung metastasis. Of note, preoperative biopsy was not carried out for patients with radiologically equivocal lesions for the fear of tumor spread or intra-abdominal bleeding.

During laparotomy, the abdominal viscera and peritoneal cavity were initially explored to confirm the absence of peritoneal deposits and/ or malignant ascites using self-retaining abdominal retractor. Liver transection was performed under inflow occlusion using a vessel loop applied around the free margin of the lesser omentum. Hepatic inflow occlusion (Pringle maneuver) was applied via continuous or intermittent clamping of the portal triad. Continuous Pringle maneuver was applied by clamping of the hepatoduodenal ligament during the whole duration of liver parenchyma transection. Intermittent occlusion comprised alternating 10 and 5 min cycles of liver ischemia and reperfusion, respectively. Postoperative complications and mortality were recorded in all patients. Postoperative complications entailed intra-abdominal hemorrhage, bile leak, ascites, intraperitoneal abscess, hepatic failure (manifested by bleeding tendency, jaundice and encephalopathy) and wound infection.

Surgery-related mortality was defined as death occurring after surgery within the same hospital admission or during the first postoperative 30 days. Postoperative complications were graded according to Clavien-Dindo classification. As previously described, an overall score of postoperative complications (ranging from one to seven) was calculated for each patient through allocation of one point to each of grades I, II, IIIa, IIIb, IVa, IVb and V in ascending order.<sup>15</sup> Statistical analysis was carried out by GraphPad Prism 6.0 software. For comparisons, p value <0.05 was considered statistically significant.

## RESULTS

### Preoperative data

Twenty-six patients were eligible for the study with median age of 52 (range: 22-76) years and predominance (69%) of male gender. A summary of relevant preoperative data is shown in Table 1.

**Table 1: Preoperative data.**

Parameter	N	%
Male gender	18	69
Smoking	10	38
Abdominal pain	16	62
Anorexia	14	54
Diabetes	6	23
Fatty liver (ultrasonography)	8	31

In the CLVRs group, the majority of patients were considered for surgery due to metastatic cancer to the liver from different organs. However, in one patient with malignant-featuring pancreatic head mass, liver resection was planned for concurrent liver mass due to its radiologic features which were consistent with hepatic hemangioma and a barely marginal increase in CA 19:9 levels preoperatively. In another patient with right adrenal tumor and a third one with jejunal mass, liver resection was decided in both patients due to the atypical features of preoperative imaging characteristics.

**Table 2: Clinical diagnoses, SLRs group.**

Clinical characteristic	No.
Metachronous liver metastases from colonic origin	3
Metachronous liver metastases from rectal origin	2
Liver metastasis from gall bladder carcinoma	1
Intrahepatic cholangiocarcinoma	1
Giant liver hemangioma	1
Liver mass with indefinite diagnosis	5

In the SLR group, 8 patients underwent liver resection on the basis of confident clinical diagnosis of metachronous liver metastasis from colorectal cancer (5), metastasis from gall bladder cancer (1), intrahepatic cholangiocarcinoma (1) and hemangioma (1). In the remaining 5 patients, liver resection was carried out due to the uncertain clinical diagnosis and equivocal imaging findings. Tables 2 and 3 showed the preoperative diagnoses based on clinical findings and imaging reports.

### Operative data

Operative time was significantly prolonged in the CLVRs group (range: 160 to 480, median: 255 minutes)

compared with SLR group (range 90 to 315, median: 180 minutes), ( $p < 0.05$ ).

Liver resection for malignant lesions was indicated in 17 (65%) patients, among them 16 cases of metastatic cancers and one primary cancer (intrahepatic cholangiocarcinoma). Among patients with liver metastases, 12 had CRLM with primary tumor originating from the colon in 8 and the rectum in 4 patients.

**Table 3: Organs resected simultaneously with the liver, CLVRS group.**

Organ	No.
Colon/rectum	5
Rectum	2
Pancreas	1
Small bowel (jejunum)	1
Ovary	1
Adrenal gland	1
Lung and diaphragm	1
Diaphragm and gall bladder mass	1

Liver metastasectomy for non-CRLM was undertaken due to local liver invasion in 4 patients, including 3 patients with synchronous metastases from lung, gall bladder and recurrent ovarian cancers and a fourth patient who had recurrent hepatic metastasis from gall bladder cancer.

Liver resection for benign lesion was undertaken in 9 (35%) patients with focal nodular hyperplasia (3), giant hemangioma (2), hemangioendothelioma (1), intrahepatic biliary adenoma (1), xanthogranulomatous cholecystitis (1) and inflammatory pseudotumor (1). Liver transection was performed using only the clamp crushing technique in 18 patients (69%, 9 per each group) or assisted by the dissecting sealer in 8 patients (31%, 4 per each group).

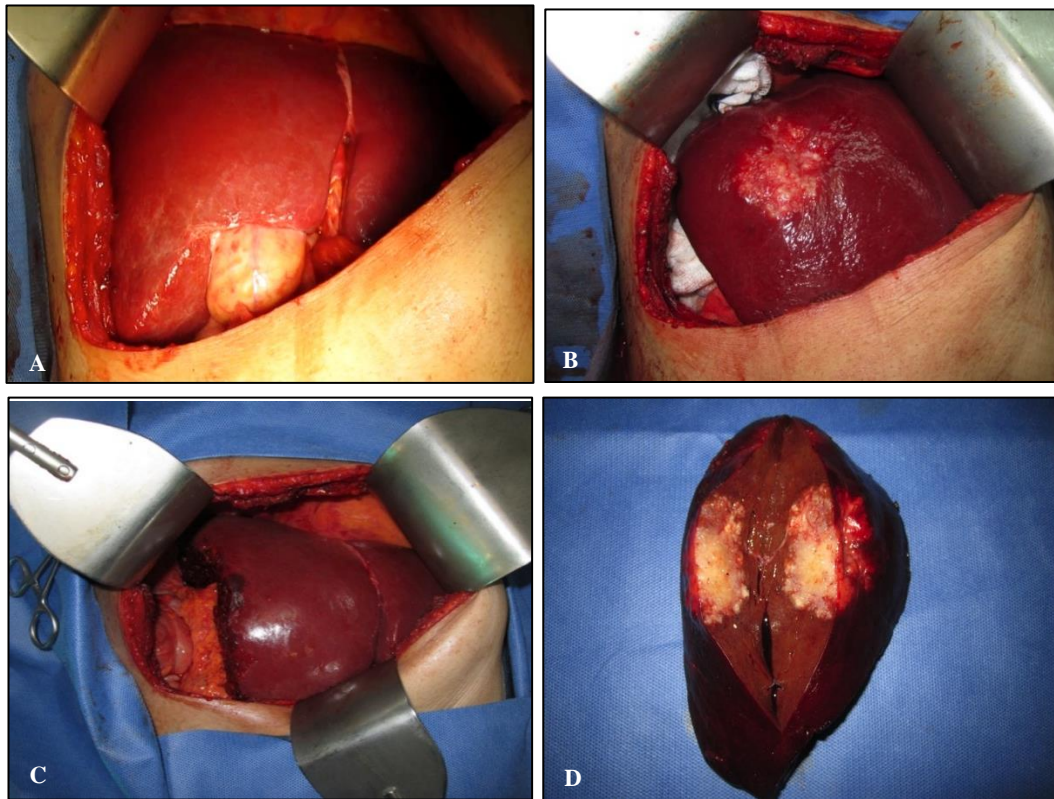
Major liver resection ( $\geq 3$  segments) was done in 14 (54%) patients. In the CLVRs group, 7 patients underwent major hepatectomy due to metastases from colorectal (5), gall bladder (1) and recurrent ovarian (1) cancer. In the SLR group, major liver resection was carried out for metastatic colorectal (4) and gall bladder (1) cancers, intrahepatic cholangiocarcinoma (1) and giant hemangioma (1).

Non-selective inflow occlusion was applied in 20 patients (77%) while selective inflow occlusion, involving of the right or left hemiliver was applied 6 patients (23%). Anatomic resection was carried out in 22 patients (85%) whereas non-anatomic resection was performed in 4 patients (15%).

The central venous pressure was kept at low level (0–5 mm H<sub>2</sub>O) with preservation of adequate urine output (at least 30 ml/hour) during parenchymal transection in all

patients. Nonetheless, blood loss was significantly higher in the CLVRs and ranged from 350-1300 (median: 750) ml versus 100-650 (median: 250) ml in the SLR group),  $p < 0.05$ . Likewise, patients in the CLVRs required

significantly increased number of transfusion units including red blood cells and plasma (range: 0-5, median 3) in comparison with SLR group (range: 0-2 median 1),  $p < 0.05$ .



**Figure 1: Liver metastasis (involving segments VI and VII) from rectal cancer, (A) initial exploration before right lobe mobilization, (B) initial exploration after complete mobilization of the right lobe, (C) right posterior sectionectomy completed, (D) resected specimen with grossly adequate margins.**

The type of liver ischemia (continuous versus intermittent) was not associated with the increased severity of postoperative complications. Figure 1 (A-D) shows right posterior sectionectomy specimen due to metastatic rectal adenocarcinoma involving liver segments VI and VII.

**Postoperative data**

In the SLR group, histopathologic examination showed that the resected liver masses were malignant in 7 patients and benign in the remaining 6. Table 4 summarizes the definitive histopathologic compared with the preoperative diagnoses.

In the CLVRs group, the resected liver lesions showed histopathologic evidence of malignant lesions in 10 patients while in only 3 cases the resected liver specimens contained histopathologically proven benign lesions, details are shown in Table 5.

The severity of postoperative complications was significantly higher among patients of CLVRs (median 4, range 1-7) compared with those in SLR (median 2, range

1-4) group,  $p < 0.05$ . Among patients of the CLVRs group, elderly (>65 years) patients exhibited significantly higher scores of postoperative complications compared with younger patients in the same group as well as their controls in the SLR group,  $p < 0.05$ .

**Table 4: Definitive histopathologic diagnoses of resected liver lesions: SLR group.\***

Definitive histopathologic diagnosis	No.
Metachronous liver metastases from colonic adenocarcinoma	3
Metachronous liver metastases from rectal adenocarcinoma	2
Liver metastasis from gall bladder carcinoma	1
Intrahepatic cholangiocarcinoma	1
Giant liver hemangioma	1
Inflammatory pseudotumor*	1
Focal nodular hyperplasia*	1
Xanthogranulomatous cholecystitis*	1
Intrahepatic bile duct adenoma*	1
Hemangioendothelioma*	1

\*The definitive histopathologic diagnosis in 5 cases with ambiguous radiologic features included 1 case for each of the

following: inflammatory pseudotumor, focal nodular hyperplasia, xanthogranulomatous cholecystitis, intrahepatic bile duct adenoma and hemangi endothelioma.

Among all patients enrolled in this study, mortality rate was 7.7% (two patients died) postoperatively. However, postoperative mortality was encountered exclusively in CLVRs group. The first patient who died from respiratory and multiorgan failure following combined liver, diaphragm and lung resections (right lower lobectomy) was elderly (73 years). The second patient had liver resection combined with extended right hemicolectomy, right nephrectomy and simple repair of the duodenum after resection of transverse colonic-duodenal fistula. This patient died on postoperative day 25 due to duodenal leak and sepsis.

**Table 5: Definitive histopathologic diagnoses of the resected liver and other organs' lesions: CLVRs group.**

Definitive histopathologic diagnosis	No.
Synchronous liver metastases from colonic adenocarcinoma	4
Synchronous liver metastases from rectal adenocarcinoma	2
Synchronous liver metastases from colonic neuroendocrine carcinoma	1
Liver metastases from recurrent ovarian cancer	1
Liver metastases from lung carcinoma invading the diaphragm	1
Liver metastases and diaphragmatic deposits from gall bladder adenocarcinoma	1
Focal nodular hyperplasia (liver) and pancreatic rest (jejunum)*	1
Focal nodular hyperplasia (liver) and adenoma (right adrenal gland)*	1
Hemangioma (liver) and adenocarcinoma (pancreas)*	1

\*Histopathologic examination confirmed the benign nature of the resected liver mass in 3 cases including focal nodular hyperplasia (2) and hemangioma (1).

## DISCUSSION

In this study we analyzed the influence of combined liver-visceral resections on the severity of postoperative complications. In comparison with patients who underwent SLR, simultaneous resection of the liver and other organ(s) was associated with higher complication rates and mortality, particularly in elderly patients and those who undergo multi-organ resection.

The study cohort comprised patients who underwent CLVRs in comparison with control group of matching SLR patients. Factors considered for matching involved age group (by decade), gender, number of resected liver segments, hepatic inflow occlusion and parenchyma transection techniques. Given the negative influence of

parenchymal liver disorders on the clinical outcome of liver resection, patients with cirrhosis, severe steatosis and cholestasis were excluded.<sup>16-22</sup>

As anticipated, the CLVRs required significantly longer operative time. This finding accords with previous report which showed that the operative time for simultaneous resection of the liver and other viscera as significantly prolonged.<sup>23</sup>

Moreover, the burden of combined liver-visceral resection entailed higher blood loss and increased need for transfusion. These data are in line with previous studies which demonstrated that combined simultaneous liver-visceral resection correlates with increased blood loss and intraoperative transfusions.<sup>23</sup>

With respect to parenchymal transection, we regularly use the crushing clamp technique. In a limited number of patients, the vessel-sealing device was used. The policy was based on previously published data that showed compelling evidence that parenchyma transection using modern devices, including the harmonic scalpel, water jet device and the dissecting sealer did not result in significant reduction of blood loss, complication rates and mortality compared with the crushing clamp technique.<sup>24</sup> Therefore, crushing clamp technique was our preferred method due to the limited financial resources in our center. Noteworthy, continuous ischemia did not result in significant rise in the postoperative transaminase levels or the complication score compared with intermittent inflow occlusion. This is likely related to application of continuous ischemia only in minor resections.

Different strategies were applied for management of colorectal cancer with synchronous liver metastases including the standard "primary first", combined and reverse "liver first" approaches. Upfront combined liver-colorectal resection, without neo-adjuvant chemotherapy, prevailed among our colorectal cancer patients who present with synchronous liver metastases due to the relatively small number ( $\leq 3$ ) of liver deposits. This strategy accords with the published guidelines which do not advocate neo-adjuvant chemotherapy with technically-easy metastasectomy limited number of the metastatic deposits' number.<sup>12</sup> The standard approach was carried out in one patient with liver metastases from left colon cancer due to symptomizing primary tumor and large number of liver secondaries. In this situation, postoperative chemotherapy was successful in downsizing the liver deposits and therefore secured enough liver volume during resection of the secondary tumors thereafter. The decision was based on previously published data which clearly demonstrated downsizing benefit of chemotherapy in this situation.<sup>25,26</sup> The reverse "liver first or Geneva" approach was applied in one patient with locally advanced rectal cancer to provide opportunity to control the fast-growing metastasis prior to neoadjuvant therapy for the primary tumor.<sup>27,12</sup> It was found that in contrast to patients who underwent liver resection alone, the postoperative course was

significantly more complicated following CLVRs. This observation agrees with a number of previous studies which demonstrated increased postoperative morbidity in the situation of combined versus sequential resection of CRLM.<sup>12,28,29</sup>

Liver resection for metastatic cancers of non-colorectal origin remains debatable.<sup>30</sup> In the current study, CLVRs for non-CRLM was done due to direct invasion by malignant tumors from neighboring organs in 3 patients with original tumors from the colon, ovary and the right lung. The enthusiasm to perform liver resection in a fourth patient with non-CRLM (recurrent liver metastases from previously removed gall bladder cancer) was related to the relatively long interval between resection of the primary tumor and the appearance to metastasis.<sup>31</sup>

Considering that there is almost no evidence on any beneficial effect of liver metastasectomy in cases of pancreatic cancer, we have no case of liver metastasectomy from pancreatic cancer.<sup>30</sup> The only indication of combined liver-pancreas resection in this study was one case of minor hepatectomy for coincidental liver hemangioma in combination with pancreaticoduodenectomy for pancreatic head cancer. In this case, liver resection was undertaken on the basis of confident benign radiologic features of the liver lesion during preoperative imaging.

However, CLVR procedures were performed for other benign lesions due to preoperative unspecified radiologic features and lack of frozen section biopsy intraoperatively. For instance, we reported one case of liver and small bowel mass that have been resected in the same operation. Interestingly, the liver mass was due to focal nodular hyperplasia while the jejunal mass was made by a pancreatic rest. In another patient, liver resection was done for a patient with focal lesions in the liver and right adrenal gland. Likewise, both masses were histopathologically proven to be benign including focal nodular hyperplasia and adrenal adenoma.

Of note, the current study is limited by a number of factors including the inherent defects of retrospective analysis and the relatively small number of patients. Inclusion of patients with benign lesions does not impair the quality of our results since the main focus of the study was a comparison between both groups in short term clinical outcome including morbidity and mortality. Survival was not investigated as it is definitely be influenced by the histopathologic type of the resected lesions.

## CONCLUSION

In conclusion, the results demonstrate that resectional liver surgery involving simultaneous resection of other organs carries increased risk of morbidity and mortality. However, it can be safely carried out in carefully selected patients.

*Funding: No funding sources*

*Conflict of interest: None declared*

*Ethical approval: The study was approved by the Institutional Ethics Committee*

## REFERENCES

1. Pretzsch E. Mechanisms of metastasis in colorectal cancer and metastatic organotropism: hematogenous versus peritoneal spread. *J Oncol.* 2019;74:7-19.
2. Cetin B, Bilgetekin I, Cengiz M, Ozet A. Managing synchronous liver metastases in colorectal cancer. *Indian J Surg Oncol.* 2018;9:461-71.
3. Adam R, Kitano Y. Multidisciplinary approach of liver metastases from colorectal cancer. *Ann Gastroenterol Surg.* 2019;3:50-6.
4. Wakabayashi T. Predictive model for survival after liver resection for noncolorectal liver metastases in the modern era: a Japanese multicenter analysis. *J Hepato Biliary Pancreat Sci.* 2019;26:441-8.
5. Hof J, Kok K, Sijmons RH, Jong KP. Systematic review of the prognostic role of the immune system after surgery of colorectal liver metastases. *Front Oncol.* 2019;9:148.
6. Reding D. Treatment strategies and outcome of surgery for synchronous colorectal liver metastases. *Swiss Med Wkly.* 2017;147:14-8.
7. Tsilimigras DI. Disappearing liver metastases: a systematic review of the current evidence. *Surg Oncol.* 2019;29:7-13.
8. Saad AM, Rahman AO. Initial systemic chemotherapeutic and targeted therapy strategies for the treatment of colorectal cancer patients with liver metastases. *Expert Opin Pharmacother.* 2019;20:1767-75.
9. Kye BH. Which strategy is better for resectable synchronous liver metastasis from colorectal cancer, simultaneous surgery, or staged surgery? Multicenter retrospective analysis. *Ann Surg Treat Res.* 2019;97:184-93.
10. Jones RP, Brudvik KW, Franklin JM, Poston GJ. Precision surgery for colorectal liver metastases: opportunities and challenges of omics-based decision making. *Eur J Surg Oncol.* 2017;43:875-83.
11. Gavriilidis P. Simultaneous versus delayed hepatectomy for synchronous colorectal liver metastases: a systematic review and meta-analysis. *J Hepat Bilia.* 2018;20:11-9.
12. Chow FCL, Chok KH. Colorectal liver metastases: an update on multidisciplinary approach. *World J Hepatol.* 2019;11:150-72.
13. Martin RCG, Augenstein V, Reuter NP, Scoggins CR, McMasters KM. Simultaneous versus staged resection for synchronous colorectal cancer liver metastases. *J Am Coll Surg.* 2009;208:842-50.
14. Esposito F. Primary tumor versus liver-first approach for synchronous colorectal liver metastases: an association française de chirurgie

- (afc) multicenter-based study with propensity score analysis. *World J Surg.* 2018;42:4046-53.
15. El-Badry AM, Abdelraheem O. Clinical outcome after liver resection for colorectal versus non-colorectal metastasis: a comparative study. *Int Surg J.* 2018;5:390-7.
  16. El-Badry AM, Ahmed AE. Evaluation of the “50-50 criteria” of post-hepatectomy liver failure as mortality predictor after resection of liver tumors. *Int Surg J.* 2019;6:648-52.
  17. Abdelhameed HF, El-Badry AM. Cirrhosis aggravates the ninety-day mortality after liver resection for hepatocellular carcinoma. *Int Surg J.* 2019;6:2869-75.
  18. El-Badry AM, Abusedera MA, Ali HM. Postoperative thrombocytopenia aggravates liver dysfunction after resection of hepatocellular carcinoma in the cirrhotic liver. *HPB.* 2019;21:982.
  19. El-Badry AM, Graf R, Clavien PA. Omega 3 - Omega 6: what is right for the liver? *J Hepatol.* 2007;7:718-25.
  20. Clavien PA. What is critical for liver surgery and partial liver transplantation: size or quality? *Hepatol Baltim Md.* 2010;52:715-29.
  21. El-Badry AM. Prevention of reperfusion injury and microcirculatory failure in macrosteatotic mouse liver by omega-3 fatty acids. *Hepatol Baltim Md.* 2007;45:855-63.
  22. El-Badry AM. Chemical composition of hepatic lipids mediates reperfusion injury of the macrosteatotic mouse liver through thromboxane. *J Hepatol.* 2011;55:1291-9.
  23. Nakajima K. Predictive factors for anastomotic leakage after simultaneous resection of synchronous colorectal liver metastasis. *J Gastrointest Surg.* 2012;16:821-7.
  24. Moggia E. Methods to decrease blood loss during liver resection: a network meta-analysis. *Cochrane Database Syst Rev.* 2016;10:CD010683.
  25. Mahfud M. Impact of preoperative bevacizumab on complications after resection of colorectal liver metastases: case-matched control study. *World J Surg.* 2010;34:92-100.
  26. Kawamura J. Clinical efficacy of liver resection after downsizing systemic chemotherapy for initially unresectable liver metastases. *World J Surg Oncol.* 2016;14:56.
  27. Mentha G. ‘Liver first’ approach in the treatment of colorectal cancer with synchronous liver metastases. *Dig Surg.* 2008;25:430-5.
  28. Passot G, Vauthey JN. In favor of two-stage hepatectomy (TSH). *Eur J Surg Oncol.* 2015;41:1566-7.
  29. Shubert CR. A NSQIP review of major morbidity and mortality of synchronous liver resection for colorectal metastasis stratified by extent of liver resection and type of colorectal resection. *J Gastrointest Surg Off.* 2015;19:1982-94.
  30. Clarke NAR, Kanhere HA, Trochsler MI, Maddern GJ. Liver resection for non-colorectal non-neuroendocrine metastases. *Anz J Surg.* 2016;5:137-140.
  31. Martel G. Liver resection for non-colorectal, non-carcinoid, non-sarcoma metastases: a multicenter study. *PloS One.* 2015;10:e0120569.

**Cite this article as:** El-Badry AM, Ali MM. Combined liver-visceral resection for neoplastic lesions correlates with increased postoperative complications. *Int Surg J* 2020;7:1335-41.