

## Case Report

# Hydatid cyst of broad ligament: a rare case report

Ajay Gujar<sup>1</sup>, Jayant Pednekar<sup>1</sup>, Nida Khan<sup>1\*</sup>, Anurag Tiwary<sup>1</sup>, Rohith Pillai<sup>1</sup>,  
Karna Chheda<sup>2</sup>, Pragati Singhal<sup>1</sup>

<sup>1</sup>Department of General Surgery, Dr. D. Y. Patil University, School of Medicine, Navi Mumbai, Maharashtra, India

<sup>2</sup>Department of General Surgery, BDMA Municipal Hospital, Kandivali, Mumbai, Maharashtra, India

**Received:** 31 January 2020

**Accepted:** 12 February 2020

**\*Correspondence:**

Dr. Nida Khan,

E-mail: khannida08@yahoo.com

**Copyright:** © the author(s), publisher and licensee Medip Academy. This is an open-access article distributed under the terms of the Creative Commons Attribution Non-Commercial License, which permits unrestricted non-commercial use, distribution, and reproduction in any medium, provided the original work is properly cited.

### ABSTRACT

Hydatid cyst is a parasitic disease caused by tapeworm *Echinococcus*. It affects the liver and lung most commonly, but may rarely affect fallopian tube, broad ligament and other structures. One such peculiar case is where a 17 years old female presented with a rapidly growing cystic mass in lower abdomen, clinically suspicious of ovarian mass or mesenteric cyst. Investigations failed to identify the nature. On laparotomy, excision of the mass was done. Surprisingly histopathological examination identified the lesion as hydatid cyst arising from the broad ligament. Patient responded well to surgical excision followed by albendazole administration. Female genital tract hydatidosis is a rare entity and in most cases the involvement is secondary. Primary hydatid disease of female genital tract is even very rarer and generates considerable diagnostic difficulty.

**Keywords:** Broad ligament hydatid cyst, Echinococcus, Hydatid cyst

### INTRODUCTION

Hydatid cystic disease is a parasitic disease caused by *Echinococcus granulosus*. The larvae of this parasite cause the disease, which is endemic in Mediterranean, Middle Eastern, and South American countries and in New Zealand and Turkey, where people are in close contact with sheep and dogs.<sup>1</sup>

The most common site of disease is in the liver (50% to 80%), followed by the lung (5% to 30%). The life cycle of *Echinococcus* requires a definitive host, which is often a dog, and an intermediate host, which is commonly sheep. Humans become accidental intermediate hosts when they become infected after ingesting ova passed in dog feces. Pelvic disease is rare, with a 20 year old study reporting an incidence of 0.37% occurring in broad ligament.<sup>2</sup>

The incidence of hydatid disease varies in different geographic areas, being endemic in central India, while

being very frequent in Australia, Central America and Eastern Europe.<sup>3</sup>

Surgery is the primary method of treatment; however, percutaneous approaches have been investigated in recent years.

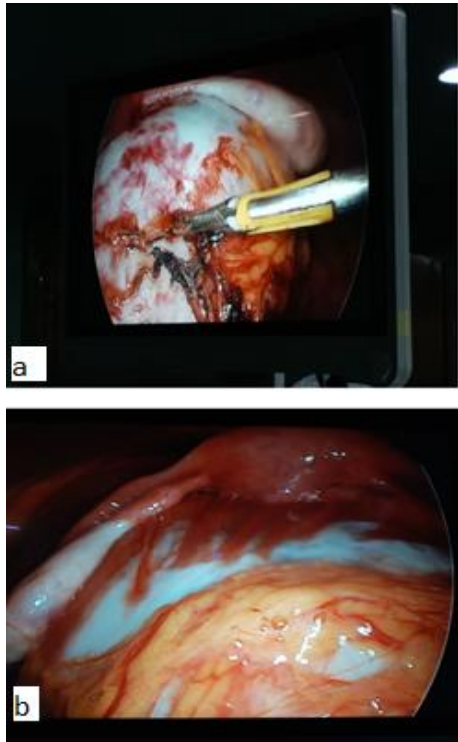
### CASE REPORT

A 17 year old female from north eastern India, presented with complaint of lump in abdomen since one year. The lump had progressively increased in size. Patient also had complaints of urinary hesitancy since 2 months. Patient went into urinary retention two days after admission and was catheterized. Patient also had history of contact with a pet dog in her childhood. Her menstrual cycle was regular.

On general examination, the lady was thin built, well-nourished, and not anemic. There was no lymphadenopathy. On systemic examination, respiratory, and cardiovascular systems were normal. On abdominal

examination, a cystic mass of 15×12 cm with smooth surface was palpable in the left lower abdomen with restricted mobility. The mass was non tender. There was no hepatosplenomegaly or ascitis.

Routine blood and urine examination, chest X-ray revealed no abnormality. Serum CA 125, alfa foeto protein (AFP), carcino embryonic antigen (CEA) was within the normal limits. Ultrasonography (USG) of whole abdomen, suggested.



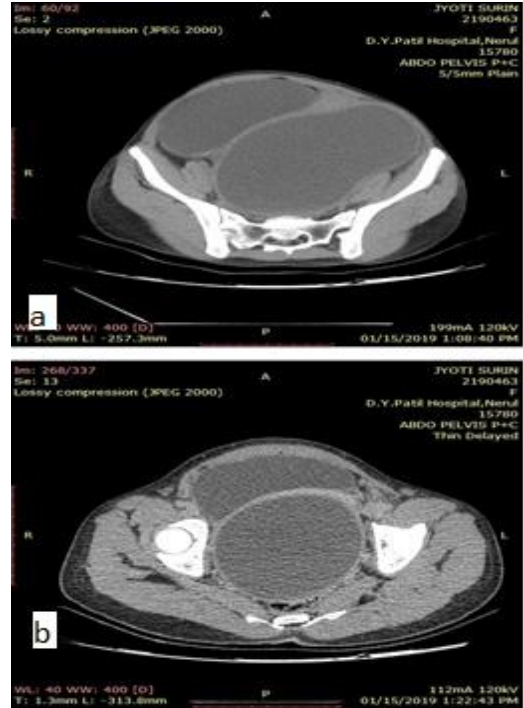
**Figures 1: a, b) Intraoperative pictures of hydatid cyst of broad ligament.**

CT scan abdomen revealed a large thick walled, peripherally enhancing lesion in pelvis seen separately from the uterus and right ovary and not seen separately from left ovary, measuring approx 15.7×9.3×19 cm. Superiorly it was reaching upto L3 vertebra. It was causing mass effect in the form of displacement of urinary bladder towards right anteriorly and displacement of uterus anteriorly. Inferiorly it was extending upto the level of pubic symphysis. It was also compressing bilateral distal ureters and causing mild to moderate hydronephrosis and hydroureter. Minimal endometrial collection/ thickening was noted.

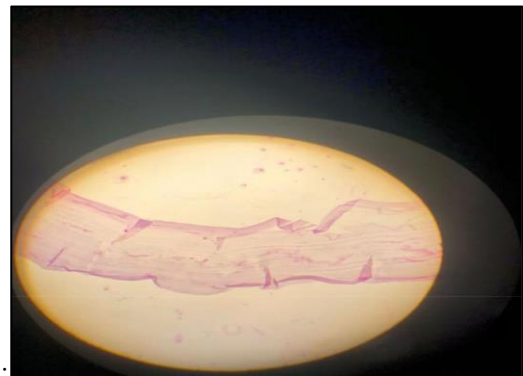
A 1.5 cm×1.4 cm hypodense non enhancing cystic lesion is noted in segment 6 of liver extending upto capsular surface of liver suggestive of simple cyst.

As no definite proof of origin and nature of the mass could be derived by clinical, radiological, and laboratory investigations, a diagnostic laparoscopy converted to open laprotomy was performed. Intra operatively, the cyst was

noted to be arising from the left broad ligament with no adhesions to ovaries, uterus, bowel, omentum or colon. Cyst was punctured, fluid aspirated to decrease its volume, then separated from broad ligament and peritoneal lavage was done. Whole resected specimen was sent for the histopathological examination.



**Figures 2: a, b) CT images of hydatid cyst.**



**Figure 3: Histopathology of hydatid cyst.**

On gross examination of specimen, a cyst measuring 12×8×5 cm, with an unremarkable external surface and internal surface had wall thickening at places and hemorrhagic areas microscopically, multiple sections studied showed cyst wall composed of hyalized pseudocapsule with attached fibrous tissue, smooth muscle and blood vessels. The separately lying inner part of cyst wall shows acellular lamellated membrane along with attached germinal layer. No protoscolices were seen. No evidence of atypia or malignancy. Post-

operative recovery was uneventful. Patient was started on albendazole for 6 weeks.

## DISCUSSION

Hydatid cyst primarily affects liver and lungs. Involvement of female genital tract is extremely rare, Ovaries are involved in such cases.<sup>4-6</sup> Disease is usually secondary to hydatidosis affecting abdominal organs, with the pelvis being affected due to spillage during primary surgery.<sup>7</sup>

One such exceptional case of primary broad ligament hydatid cyst is being described hereby as the condition is rare and clinically difficult to identify. The frequency of involvement of female genital organs in hydatid disease is very low, and its pathogenesis still remains obscure. The symptoms of the disease are not specific, they simulate those of ovarian cysts. Prior history and roentgenograms of calcified cysts contributed to the correct preoperative diagnosis. In a 18 year study done in endemic Tunisia, on 265 patients over 18 years, only one was found to have hydatid cyst of broad ligament.<sup>8</sup>

Hydatid cyst of female pelvis is a rare entity. It is usually diagnosed intraoperatively or post operatively.<sup>9</sup> The pre-operative diagnosis of hydatid disease may be possible by radiographs, ultrasonography, and CT scan in the women with high clinical suspicion of hydatid cyst. The plain radiograph may show calcification in the wall of the cyst. Ultrasonography and CT scan may demonstrate features like multilocular appearance, a fluid level from hydatid sand and ultrasonic 'water lily sign'. In this study case, ultrasonography and CT abdomen and pelvis revealed ovarian or mesenteric cyst. Casoni's test is only 63.8% sensitive and 47% specific to hydatid disease, and has been superseded by more sensitive, specific and safer serological tests.<sup>10</sup>

Fine needle aspiration cytology (FNAC) may help in establishing the diagnosis of unilocular cystic pelvic mass. In the past, FNAC of hydatid cyst was thought to cause severe anaphylactic reactions. But in the study of Von Sinner et al the incidence of anaphylactic reactions reported was very low. FNAC may show hooklets, scolices, and laminated cyst wall. FNAC was not done for our patient as differential diagnosis was ovarian or mesenteric cyst.<sup>11</sup> Casoni's intradermal test (CIT) and Indirect haemagglutination test (IHA) are positive in variable number of patient.

CT allows precise assessment of osseous lesions, whereas MR imaging is superior in demonstrating neural

involvement.<sup>11</sup> Treatment is excision of cyst followed by a long course of anti-helminthics.

## CONCLUSION

Hydatid disease of broad ligament is a rare presentation, with a reported incidence of less than one percent. Diagnosis is usually intra or postoperative. Treatment is excision of cyst and long course of albendazole.

*Funding: No funding sources*

*Conflict of interest: None declared*

*Ethical approval: Not required*

## REFERENCES

1. Jarnagin W. Blumgart's surgery of liver, biliary tract and pancreas, 6<sup>th</sup> edition. Elsevier; 2016:532
2. Bickers J, William M. Hydatid disease of the female pelvis. Am J Obst Gynecol. 1970;107:477-83.
3. Akther J, Khanam N, Rao S. Clinico epidemiological profile of hydatid diseases in central India, a retrospective and prospective study. Int J Biol Med Res. 2011;3:603-6.
4. Bhattacharya A, Saha R, Mitra S, Nayak P. Primary hydatid cyst of broad ligament. Trop Parasitol. 2013;3(2):155-7.
5. Georgakopoulos PA, Gogas CG, Sariyannis HG. Hydatid disease of the female genitalia. Obstet Gynecol. 1980;55:555-9.
6. Yuksel M, Demirpolat G, Sever A, Bakaris S, Bulbuloglu E, Elmas N. Hydatid disease involving some rare locations in the body: a pictorial essay. Korean J Radiol. 2007;8(6):531-40.
7. Bellil S, Limaïem F, Bellil K, Chelly I, Mekni A, Haouet S, et al. Descriptive epidemiology of extrapulmonary hydatid cysts: a report of 265 Tunisian cases. Tunis Med. 2009;87:123-6.
8. Arora M, Gupta CR, Jindal S, Kapoor N. An unusual case of hydatid cyst of broad ligament. JIACM. 2005;6:86-7.
9. Smith H, Sheikh AZ. Casoni Skin test, radiopedia. Available at Radiopedia.org. Accessed on 12 October 2019.
10. Sinner WN, Nyman R, Linjawi T, Ali AM. Fine needle aspiration biopsy of hydatid cysts. Acta Radiol. 1995;36:168-72.
11. Pedrosa I, Saíz A, Arrazola J, Ferreirós J, Pedrosa CS. Hydatid disease: Radiologic and pathologic features and complications. Radiographics. 2000;20:795-817.

**Cite this article as:** Gujar A, Pednekar J, Khan N, Tiwary A, Pillai R. Hydatid cyst of broad ligament: a rare case report. Int Surg J 2020;7:1298-300.