

Case Report

Retained iatrogenic foreign body causing persistent non-healing wound: a case report

Aisha Waquad, Hiren Patel, Mai Gandhi*, Guny Gabriel

Department of General Surgery, Kingsbrook Jewish Medical Center, Brooklyn, New York

Received: 02 January 2020

Accepted: 12 February 2020

***Correspondence:**

Dr. Mai Gandhi,

E-mail: mdang86@gmail.com

Copyright: © the author(s), publisher and licensee Medip Academy. This is an open-access article distributed under the terms of the Creative Commons Attribution Non-Commercial License, which permits unrestricted non-commercial use, distribution, and reproduction in any medium, provided the original work is properly cited.

ABSTRACT

An 88-year-old female presented with non-healing wound of left hip, found to have iatrogenic foreign body. The patient presented at the age of 88 with complaints of a persistent wound of left hip. She had a previous incision and drainage of an abscess on her left hip and subsequently received negative pressure therapy. She underwent a wound exploration and found to have multiple foreign bodies in the wound. While uncommon, iatrogenic foreign body should be considered as a possible differential diagnosis in patient with non-healing wounds. The literature on iatrogenic foreign body is reviewed. Iatrogenic foreign body is an uncommon pathology but should be included in the differential diagnosis in patients presenting with a non-healing wound.

Keywords: Foreign body, Iatrogenic foreign body, Non-healing wound

INTRODUCTION

Iatrogenic foreign body objects retained in the human body generally require medical attention. Their timely management is imperative to optimize the patient's quality of life. Foreign bodies can be found in any system, anywhere in the gastrointestinal tract to the soft tissues or solid organ.¹⁻⁴ Majority of patients with retained foreign bodies present within few days. However, other patients can live with chronic symptoms for months. In a study, it was reported that the surgical retained foreign body incidence occurs between 0.001%-0.01%.⁵ There is currently no literature review on retained foreign body as a complication of wound vacuum therapy. Here we discuss a foreign body (negative therapy dressing) discovered *in-situ* after months resulting in a non-healing hip ulcer, which required surgical intervention.

CASE REPORT

An 88-year-old female with a left hip wound and persistent serosanguinous drainage presented to our

hospital for surgical debridement. Patient has a known history of left hip abscess, which was incised and drained five months prior. She was subsequently placed on negative wound therapy for two months with the intention for faster closure of the wound. Wound vacuum therapy was discontinued and patient continued to experience sero-purulent discharge, erythema and tenderness of the wound. She denied any associated symptoms such as fevers/chills or changes in ambulating status.

Her past medical history is significant for dementia, type 2 diabetes mellitus, stage 4 chronic kidney disease, and ambulates with a walker. Past surgical history was significant for right hip replacement. Her home medication regimen includes carvedilol 25 mg twice daily, linagliptin 5 mg daily, simvastatin 20 mg daily, lurasidone 40 mg daily, ferrous sulfate 325 mg daily, bumetanide 1 mg daily, aspirin 81 mg daily, and vitamin C 500 mg daily. The patient was retired and denies any prior tobacco or alcohol use. It is noted that she is allergic to penicillin. Upon examination, her vital signs were 98.0°F, blood pressure of 105/64 mmHg, heart rate of 68

beats per minute, and a respiratory rate of 18 breaths per minute. Lung examination revealed vesicular breath sounds bilaterally. Cardiovascular exam revealed S1 and S2 with regular rate and rhythm without murmurs, rubs, or gallops. Abdominal exam revealed normal bowel sounds in all four quadrants without any gross distention or tenderness upon palpation. Laboratory results were within normal limits saved for mild anemia (hemoglobin 10.6). Electrocardiogram revealed a right bundle branch block which was deemed to not have perioperative or postoperative risk due to the patient undergoing non-cardiac surgery. The patient was maximized medically, found to be low risk, and was surgically cleared for the procedure.

Patient was taken to the operating room for wound exploration and debridement of left hip non-healing ulcer. Intraoperatively, multiple foreign bodies, appeared to be black foam dressing, were found within the hip wound. Wound was measured about 5 cm x 3 cm in diameter. All foreign bodies were removed and wound was explored thoroughly. Wound was then irrigated with copious amount of sterile saline and packed with iodoform packing material. Patient tolerated procedure well and has been healing since the surgery.

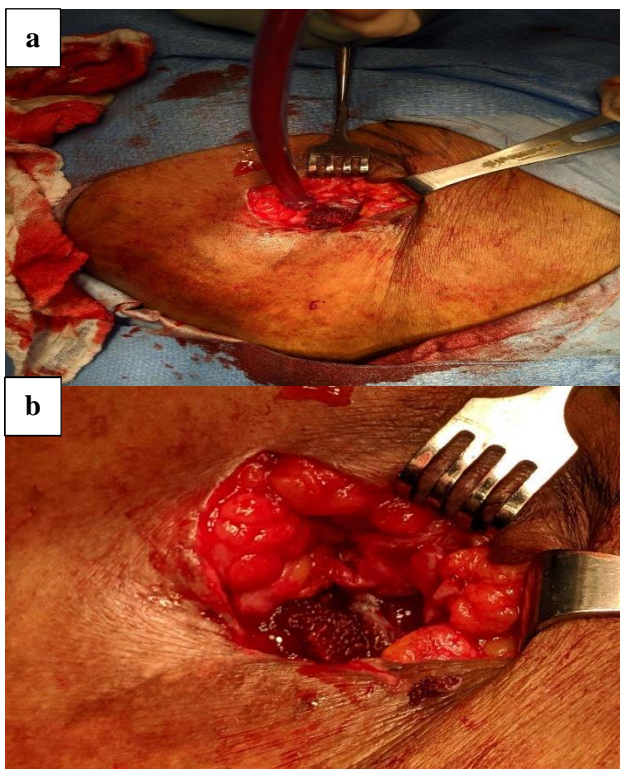


Figure 1 (a and b): Multiple foreign bodies consistent with black foam from negative pressure therapy kit.

DISCUSSION

Foreign body retention is suggested to have a direct relationship with the formation and progression of a chronic wound due to an inflammatory response. It is

reported that in one of three reports of foreign body retention has led to diffuse inflammation around the foreign body.⁶ Diffuse inflammation triggers a chronic inflammatory response and progresses into a state of a non-healing wound which may include chronic drainage, as seen in our case presented here. Current literature suggests that there is no significant association in the length of time of retention of the foreign body with initiation of fistula formation.⁷ However, long-term retained foreign bodies are known to place pressure on the walls of nearby organs which can lead to diffuse inflammation and large fistulas between organs. In these cases, surgical treatment of multiple organ involvement is the treatment of choice.⁸

Traditionally, the majority of wounds are treated with daily dressing. Selective wounds are treated with negative pressure therapy, as presented here by our patient.⁹ Negative pressure wound therapy, also referred to as vacuum-assisted wound closure, applies intermittent to continuous sub-atmospheric pressure to the surface area of the wound.¹⁰ Commercially available systems include an open-pore polyurethane ether foam sponge, an adhesive cover, fluid collection system, and a suction pump. Clinical evidence has shown that compared to conventional wound dressing techniques, negative pressure wound therapy can result in faster wound healing time and wound closure.¹¹ However, the sponge and associated wound mesh may become adherent to underlying granulation tissue which causes careful removal to become challenging. As seen in this patient, pieces of the sponge were left behind in the wound and cause continuous inflammation leading to further drainage and improper wound closure. This resulted in an infected wound although leukocyte counts remained low. This could have had led to severe consequences (such as sepsis and mortality) if not caught in time, especially in a diabetic patient

CONCLUSION

A non-healing wound requires further investigation. We present a case of iatrogenic foreign body found incidentally during workup for a ventral hernia. Iatrogenic foreign body, although uncommon, should be considered in the differential diagnosis for persistent wound.

ACKNOWLEDGEMENTS

Authors would like to thank Dr. Narendra Kumthekar, Chairman, Department of Surgery, Kingsbrook Jewish Medicine Center and Dr. Neil Mandava, Chairman, Department of Surgery, Flushing Hospital Medical Center.

Funding: No funding sources

Conflict of interest: None declared

Ethical approval: Not required

REFERENCES

1. Kurer MA, Davey C, Khan S, Chintapatla S. Colorectal foreign bodies: a systematic review. *Colorect Dis.* 2009;12(9):851-61.
2. Fung BM, Sweetser S, Song LM, Tabibian JH. Foreign object ingestion and esophageal food impaction: An update and review on endoscopic management. *World journal of gastrointestinal endoscopy.* 2019;11(3):174-92.
3. Agarwal A. Foreign body-related extremity trauma in children: a single-center experience. *Indian J Orthopaedics.* 2018;52(5):481-8.
4. Xu J, Wang H, Song ZW, Shen MD, Shi SH, Zhang W, et al. Foreign body retained in liver long after gauze packing. *World J Gastroenterol.* 2013;19(21):3364-8.
5. Gothwal M, Rodha M, Surekha B, Singh P, Yadav G, Sethi P. Gossypiboma- a nightmare for surgeon: a rare case with review of literature. *J Mid-life Health.* 2019;10(3):160-2.
6. Margolis D. Epidemiology of wounds. In: Mani R, Romanelli M, Shukla V, eds. *Measurements in wound healing.* 1st ed. London, Springer; 2013: 145-153.
7. Gottrup F. A specialized wound-healing center concept: importance of a multidisciplinary department structure and surgical treatment facilities in the treatment of chronic wounds. *Am J Surg.* 2004;187(5):38-43.
8. Cawich SO, Thomas DA, Mohammed F, Bobb NJ, Williams D, Naraynsingh V. A management algorithm for retained rectal foreign bodies. *Am J Men Health.* 2017;11(3):684-92.
9. MacDonald J. Global initiative for wound and lymphoedema care. *J Lymphoedema.* 2009;4(2):92-5.
10. Ubbink DT, Westerbos SJ, Nelson EA, Vermeulen H. A systematic review of topical negative pressure therapy for acute and chronic wounds. *Br J Surg.* 2008;95(6):685-92.
11. Gestring M, Sanfey H. *Negative pressure wound therapy.* UpToDate, edited by Collins KA and Sanfey H. Philadelphia, PA: Wolters Kluwer Health. 2014.

Cite this article as: Waquad A, Patel H, Gandhi M, Gabriel G. Retained iatrogenic foreign body causing persistent non-healing wound: a case report. *Int Surg J* 2020;7:883-5.