

Case Report

Gallbladder volvulus: a rare cause of acute abdomen

Raphael Shamavonian*, Jade F. Enoch, Nagy Andrawis

Department of General Surgery, Shoalhaven District Memorial Hospital, Nowra, New South Wales, Australia

Received: 15 December 2019

Revised: 08 February 2020

Accepted: 12 February 2020

*Correspondence:

Dr. Raphael Shamavonian,

E-mail: drraphaelshamavonian@gmail.com

Copyright: © the author(s), publisher and licensee Medip Academy. This is an open-access article distributed under the terms of the Creative Commons Attribution Non-Commercial License, which permits unrestricted non-commercial use, distribution, and reproduction in any medium, provided the original work is properly cited.

ABSTRACT

Gallbladder volvulus is an extremely rare cause of abdominal pain. It requires high clinical suspicion to diagnose and prompt surgical management. The main risk factors for this condition are age (over 60 years old) and being female. Presentation can often mimic acute cholecystitis or biliary colic as patients with a volvulus will present with right upper quadrant pain, nausea, vomiting with or without fevers and raised inflammatory markers. Imaging can help aid diagnosis with computed tomography of the abdomen or ultrasound often being the most available and time efficient modality. Delay in diagnosis and surgery can lead to significant patient morbidity. We report a case of gallbladder volvulus in a 78-year-old female that was managed successfully with laparoscopic cholecystectomy.

Keywords: Gallbladder, Cholecystectomy, Laparoscopy, Volvulus

INTRODUCTION

Gallbladder volvulus is an incredibly rare cause of the acute abdomen, accounting for less than 1 in 365,000 hospital admissions.¹ Due to the nature of its presentation and rarity, it can be an elusive diagnosis for physicians to make. It has been reported that only 9.8% of patients are diagnosed with gallbladder volvulus pre-operatively.² Prompt surgical management is necessary and can reduce mortality to less than 5%.¹

CASE REPORT

A 78-year-old female was transferred from a peripheral hospital with 24 hours of progressive abdominal pain, nausea and vomiting. Pain had commenced in the lower abdomen and progressively worsened, being maximal in the right abdomen. On arrival to the emergency department she was tachycardic, hypertensive with a distended abdomen and generalised peritonitis. Tenderness was maximal in the right lower quadrant. Venous blood gas was within normal limits with pH 7.39, BE- 2.2, lactate 1.4 mmol/l. White cell count was

$23.88 \times 10^9/l$, neutrophils $20.63 \times 10^9/l$ and C-reactive protein 58 mg/l. A contrast enhanced computed tomography (CT) scan of the abdomen was performed which demonstrated a distended gallbladder with stranding within the mesentery, shown in Figure 1.

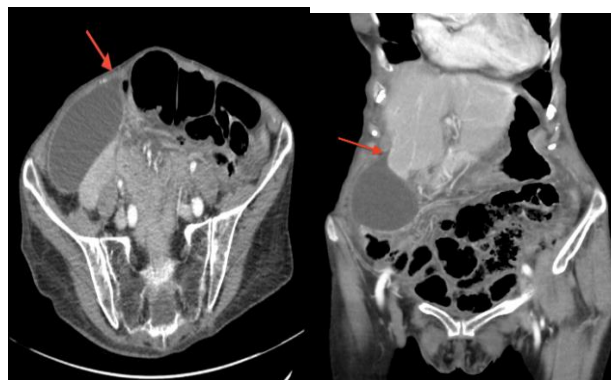

Figure 1: Coronal and sagittal CT slices demonstrating “beak sign” (red arrow) with distended gallbladder.

She was booked for diagnostic laparoscopy and proceed to laparotomy.

Diagnostic laparoscopy revealed a frankly necrotic gallbladder with a small amount of serous free fluid in the pelvis. Figure 2 showed that the gallbladder had twisted upon its mesentery. Anatomically, the presence of a prominent right hepatic artery running in close proximity to Calot's triangle was the only noted variant. Intra-operative cholangiogram performed demonstrated trifurcating right hepatic, right posterior sectoral and left hepatic ducts; but was otherwise normal with no filling defects.

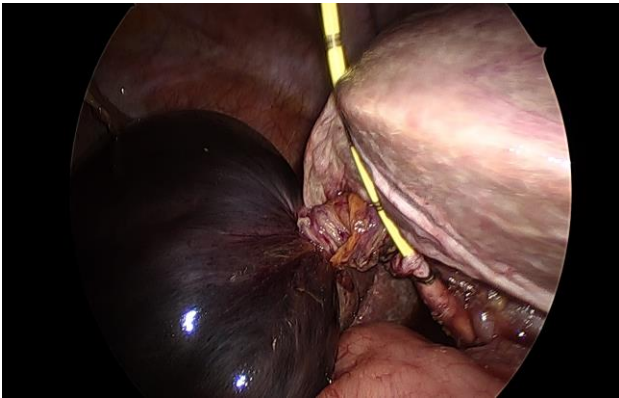


Figure 2: Necrotic gallbladder with volvulus of mesentery and cholangiogram catheter placed in cystic duct.

The operative approach was to maintain the volvulus so as not to release ischaemic metabolites into the circulation, and isolate the cystic duct and artery thus obtaining the critical view shown in Figure 3. The gallbladder was removed successfully after decompression via an Endo-catch bag. A 10 Fr Vari-vac abdominal drain was left *in situ*. The patient made an uncomplicated recovery after a short stay in high dependency unit for monitoring, and was discharged on postoperative day 5.

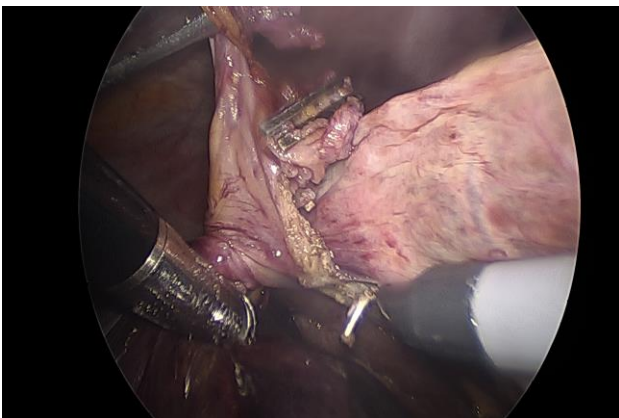


Figure 3: Cholecystectomy being performed with dissection of the abnormal gallbladder mesentery, clips placed on the cystic duct (center).

DISCUSSION

Gallbladder volvulus (GV) was first described by Wendel in 1898 as a "floating gallbladder."³ It is extremely rare with an incidence of 1 in 365,000 hospital admissions and accounts for less than 0.1% of cholecystectomy cases.¹ There have been between 300-500 cases of GV reported in the literature.¹ Incidence increases with age, commonly affecting those in their seventh or eighth decade of life, with a female to male ratio of 3:1.⁴ Prompt recognition and surgical management is required in order to avoid necrosis, gangrene and ultimately perforation of the gallbladder. To date, only a few of the reported cases have successfully managed GV laparoscopically, since Nguyen et al in 1995.⁵

There are two main types of GV: type A whereby the gallbladder and cystic duct or artery are supported on a mesentery, or type B whereby the cystic duct or artery alone is supported on a mesentery. The aetiology of GV is poorly understood, however, it has been suggested to be multifactorial. Essentially, GV is due to the presence of a mesentery on which the gallbladder is able to twist upon its axis, compromising both its blood supply and biliary drainage. A long or widened mesentery, as well as abnormal fixation of the gallbladder to the liver, will predispose a patient to this phenomenon. Furthermore, loss of visceral fat, atrophy of the liver and increased elasticity, which all become more apparent with increasing age, make the gallbladder more susceptible to twisting on itself.⁶ This may explain why the condition is more prevalent in the elderly. Significant peristaltic movement of the stomach, duodenum and nearby colon have also been attributed as potential causes of GV. It is interesting to note that cholelithiasis is neither a prerequisite or casual factor for torsion of the gallbladder. It is often an incidental finding; with up to 24% incidence which was not evident in our case.¹

Presentation of GV is predominantly characterized by right upper quadrant pain with associated nausea and vomiting. It will often mimic biliary colic or cholecystitis depending on the degree of torsion. With partial torsion (less than 180 degrees), symptoms are usually similar to biliary colic as detorsion will often occur resulting in symptom resolution. However, with complete torsion (more than 180 degrees), symptoms will often persist and be more in keeping with acute cholecystitis.⁷ Other case reports on gallbladder volvulus report similar presentations with right upper quadrant pain, nausea and emesis being the predominant symptoms.^{1,3-5,7} However, there is inconsistency in the rise of serological markers, in particular the WCC and CRP, which could be due to the timing of presentation or intermittent detorsion of the gallbladder. Clinicians should also be aware that GV may also present with right lower quadrant pain, similar to acute appendicitis, due to distension and migration of the gallbladder after undergoing torsion as evident in a case report by Vedanayagam et al.⁸ Nevertheless, the most common thing noted in all case reports of GV is that even

if the diagnosis is not made initially, it is the continued RUQ pain and ongoing clinical deterioration despite antibiotics and adequate resuscitation that will lead to operative intervention and discovery of GV. In an attempt to help with diagnosis of GV, Lau developed what has become known as the “Triad of Triads” in 1982, presented in Table 1.⁹

Table 1: “Triad of Triads” used to help recognize gallbladder volvulus.¹²

Appearance	Symptoms	Physical examination
Elderly (usually female)	Sudden onset	Nontoxic presentation
Thin habitus	Right upper quadrant pain	Palpable right upper quadrant mass
Spinal deformities	Early emesis	Pulse-temperature discrepancy

GV is notoriously difficult to diagnose pre-operatively, as investigations are often non-specific, as demonstrated in this case report. Wu et al estimated that only 9.8% of patients with GV are diagnosed pre-operatively using all available diagnostic modalities.² Serological markers are often equivocal and will generally represent an inflammatory process.¹⁰ Advancements in imaging has helped clinicians diagnose GV with ultrasound and CT being the modalities of choice. Ultrasound often reveals findings consistent with acute cholecystitis including gallbladder wall thickening and pericholecystic fluid.¹¹ CT findings that may suggest GV include fluid between the gallbladder and its fossa, horizontal rather than vertical axis orientation, cystic duct on the right of the gallbladder, and the ‘whirl sign’ resulting from a twisted cystic artery.¹² HIDA scanning and MRI can also be used to diagnose GV, however in the acute setting, these are impractical investigations.

Prompt cholecystectomy is the gold standard of managing GV. Multiple cases have been managed laparoscopically since first being performed by Nguyen et al in 1995.⁵ Surgeons should be mindful when performing this procedure that the common bile duct may be at the anterior margin of the liver due to the rotation of the mesentery and therefore more susceptible to iatrogenic injury.¹³ Decompression of the gallbladder will often have to be conducted prior to cholecystectomy due to significant distension and an inability to adequately grasp the gallbladder. Although detorsion prior to cholecystectomy was not done in present case in order to avoid release of toxic metabolites, if done, it may help reduce the chance of bile duct injury as this structure will more likely return to a more appropriate anatomical position.¹⁴ If laparoscopy cannot be conducted safely, an open approach is also considered acceptable management of GV. With timely surgical intervention, patients will have a good prognosis following the procedure.

CONCLUSION

Although a rare occurrence, clinicians should consider GV as a potential cause of acute abdominal pain. A high index of clinical suspicion is required to make the diagnosis pre-operatively due to the non-specific investigative findings that accompany this pathology. Suspicion for GV should be heightened when patients show no improvement clinically or serologically following adequate resuscitation and appropriate antibiotic therapy. Prompt cholecystectomy should be conducted in all patients with suspected GV as significant delays carry increased patient morbidity and mortality.

Funding: No funding sources

Conflict of interest: None declared

Ethical approval: Not required

REFERENCES

1. Nakao A, Matsuda T, Funabiki S, Mori T, Koguchi K, Iwado T, et al. Gallbladder torsion: case report and review of 245 cases reported in the Japanese literature. *J Hepatobiliary Pancreat Surg.* 1999;6(4):418-21.
2. Pu TW, Fu CY, Lu HE, Cheng WT. Complete body-neck torsion of the gallbladder: a case report. *World J Gastroenterol.* 2014;20(38):14068-72.
3. Wendel A. A case of floating gallbladder and kidney complicated by cholelithiasis, with perforation of the gallbladder. *Ann Surg.* 1898;27(2):199-202.
4. Reilly DJ, Kalogeropoulos G, Thiruchelvam D. Torsion of the gallbladder: a systematic review. *HPB.* 2012;14(10):669-72.
5. Nguyen T, Geraci A, Bauer JJ. Volvulus of the gallbladder. *Surg. Endosc.* 1999;9:519-21.
6. Stieber AC, Bauer JJ. Volvulus of the gallbladder. *Am J Gastroenterol.* 1983;78(2):96-8.
7. Shaikh AA, Charles A, Domingo S, Schaub G. Gallbladder volvulus: a report of two original cases and review of the literature. *Am Surg.* 2005;71(1):87-9.
8. Vedanayagam MS, Nikolopoulos I, Janakan G, El-Gaddal A. Gallbladder volvulus: a case of mimicry. *BMJ Case Rep.* 2013; bcr2012007857.
9. Lau WY, Fan ST, Wong SH. Acute torsion of the gallbladder in the aged: a re-emphasis on clinical diagnosis. *ANZ J Surg.* 1982;52(5):492-4.
10. Gupta V, Singh V, Sewkani A, Purohit D, Varshney R, Varshney S. Torsion of gall bladder, a rare entity: a case report and review article. *Cases J.* 2009;2(1):193.
11. Bahar MM, Motie MR, Amouzeshi A. Gallbladder volvulus: review of the literature and report of three cases. *J Trauma.* 2013;1(1):34-8.
12. Tajima Y, Tsuneoka N, Kuroki T, Kanematsu T. Gallbladder torsion showing a ‘whirl sign’ on a multi detector computed tomography scan. *Am J Surg.* 2009;197(1):9-10.

13. Christoudias GC. Gallbladder volvulus with gangrene. Case report and review of the literature. *J Soc Laproend.* 1997;1(2):167-70.
14. Frahat W, Mabrouk MB, Ammar H, Said MA, Lagha S, Gupta R, et al. Gallbladder volvulus: A case report and review of the literature. *Int J Surg Case Rep.* 2019;60:75-8.

Cite this article as: Shamavonian R, Enoch JF, Andrawis N. Gallbladder volvulus: a rare cause of acute abdomen. *Int Surg J* 2020;7:876-9.