

Original Research Article

Post burn neck contracture: an algorithm for choosing the ideal surgical method of management

Medhat S. Hassan*

Department of Plastic, Reconstructive and Burn Surgery, Faculty of Medicine, Menoufia University, Egypt

Received: 08 December 2019

Revised: 21 December 2019

Accepted: 25 December 2019

***Correspondence:**

Dr. Medhat S. Hassan,

E-mail: medhatsamyaly08@yahoo.com

Copyright: © the author(s), publisher and licensee Medip Academy. This is an open-access article distributed under the terms of the Creative Commons Attribution Non-Commercial License, which permits unrestricted non-commercial use, distribution, and reproduction in any medium, provided the original work is properly cited.

ABSTRACT

Background: The aim of the study is to facilitate choosing the surgical technique that will be suitable for improving both function and aesthetics of each patient through this suggested algorithm system. Any post burn neck contracture usually causes severe impairment of function and aesthetics, which causes serious psychological and social problems. That's why it is very important to sub-categorize this type of deformity by anatomical location and cause of burn to allow choosing the ideal method of surgical management.

Methods: This is a prospective study which was performed in Plastic Surgery Department, Menoufia University Hospitals over the period from March 2017 to March 2019. The study included 30 patients suffering post burn neck contracture deformities.

Results: Patients were carefully examined, and the post burn neck deformities were analyzed according to age, condition of skin at the contracture site, the range of sternomastoid muscles movement at both sides of the neck and patient's general condition. Patients were given scores and categorized into 4 grades. And according to each patient's grade, the suitable surgical technique was chosen and fulfilled. 25 patients showed great satisfaction to their post operative's outcomes and the rest were poorly satisfied.

Conclusions: Application of patients with post burn neck contractures to this algorithm system will make it easy to choose the ideal method of management and gain the best surgical results possible when performing surgical correction.

Keywords: Burn, Contractures, Neck

INTRODUCTION

Post burn neck contracture consequences are considered of the greatest challenges in reconstructive surgery. This is because the deformities resulting from burn insult affect the neck region altering the normal position of the head during flexion, extension or lateral rotation position. In addition to the arousal of abnormal skin portions and hypertrophic scars in the head and neck areas either in the static or dynamic status of the head.¹

As the neck region is easily exposed to various injuries such as scald, electric flashes, oil splashes, it is expected to see mentosternal or even cervicothoracic contractures after these injuries. The deeper the burn, the worse the contracture. Also, the more areas involved, the worse the contracture.²

Some other factors were found to have an obvious effect on the development of these deformities. For example, Patient with positive family history of keloids and hypertrophic scars would develop post burn contracture much easier than others, suggesting genetic factors to

have a role in the pathway of contracture development. Also, it has been noticed that deformities development is expected more between Africans and Caucasians than between Asians and Europeans, suggesting the difference of race to also have a role in contracture development pathway. At last, socioeconomic aspects have an important effect because lack of awareness towards dealing with burns and improper burn treatment would give catastrophic results.³

Diagnosing post burn neck contracture is not difficult, it could be only the appearance of abnormal skin appendages either in resting or motion position. Or there could also inability to maintain full flexion, extension or lateral rotation of the head for a long time without exhaustion as well. And finally, there could be inability to maintain the head in the neutral position while sitting erect. Other associated problems would be incomplete oral occlusion with mouth commissures affection, cicatricial ectropion of the lower eyelid, and alteration of trachea position resulting in difficult intubation, even that some patients would need surgical release before intubation.⁴

Older classifications for post burn contractures have been issued, such as Spina classification (1958) reported by Kirschbaum which classified neck contractures into central, lateral or complete.⁵ Achaur (1991) also classified anterior neck contractures into mild, moderate, extensive or sever Onah (2005) classified neck contractures into 4 categories and subdivided each category into a, b and c sub-categories.⁶ He took the normal position of the neck in erect position, the traction on surrounding normal skin appearing during extension and the width of the contracture band as the main milestones for his classification and Makboul (2013) who gave a simpler classification mixing between the main grades of Achaur (1991) and the subcategories of Onah (2005).^{7,8}

The main problem in these classifications was that they did not focus on evaluating the suitability of surgical procedures needed for solving the problem of each post burn contracture patient, this was the main reason for developing this algorithm system to help in choosing the suitable method of surgical reconstruction for each patient when applied.

METHODS

This prospective study was performed at department of plastic, reconstruction and burn surgery, Menoufia faculty of medicine, Egypt in the period between March 2017 to March 2019. It included 30 patients complaining of post burn neck contracture.

Inclusion criteria

Patients between the ages of 10 to 60 years old complaining of different degrees of post burn neck contracture was included in this study.

Exclusion criteria

Patients with ages below 10 years and above 60 years; patients with cervical spine spondylitis; patients with tracheal alteration interfering with general anesthesia; patients with cardiac, liver and kidney diseases; patients with uncontrolled diabetes mellitus; patients taking anti convulsing drugs; patients with high body mass index were excluded.

Each of these patients was accurately evaluated taking full history to detect the presence of any chronic diseases as diabetes mellitus, hypertension or any neurological disorders requiring frequent treatment, vital signs assessment and full laboratory investigations to complete blood count, random blood sugar, kidney and liver enzymes and coagulation profile, inspection of the quality of the skin at the neck region and the surrounding areas (back, shoulders and the supraclavicular areas) and inspection of the range of motion to extension, lateral rotation of both sides and flexion; in order to evaluate the degree of sternomastoid muscles affection on each side of the neck.

All relevant ethical aspects were considered in conducting the research. The participants were assured that their participation in the study is voluntary and that they can withdraw at any time; confidentiality and privacy of the participants were respected. Also, informed consents were taken from the patients declaring their will to participate in the study. For patients under the age of 18, informed consent was taken from their parents, but the data of the questionnaire was collected from the patient.

Algorithm system

After evaluating the patients accurately by performing the steps mentioned previously, I was able to make an algorithm system helping in choosing the suitable surgical solution for each patient based on four aspects (age of the patient, quality of the skin of the neck and areas surrounding the lesion, degree of affection of both sternomastoid muscles, and general condition of the patient)

Age of the patient was patients below 40 years (score 2) and patients above 40 years (score 1).

Lesion condition and quality of skin surrounding linear narrow lesion (less than one finger width) with normal surrounding skin in the neck (score 4); broad lesion (more than one finger width) with normal surrounding skin in the neck (score 3); big lesion affecting the neck region but skin of surrounding areas normal (score 2); big lesion affecting the neck and surrounding lesions (score 1).

Degree of affection of sternomastoid function on both sides were mild affection of extension only (score 4);

moderate affection of extension with mild affection of lateral rotation on one or both sides (score 3); moderate affection of extension and lateral rotation at one side (score 2); severe affection of extension, lateral rotation and flexion (score 1).

General condition of the patient were without associated chronic diseases (score 2) and with associated controlled chronic diseases (score 1).

Statistical analysis

Chi-square and fisher exact test were used for comparison of qualitative variables. One-way ANOVA test was used to compare between means of categorical and numerical data. Significance level (p-value) was adopted, i.e. $p < 0.05$ for interpretation of results of tests of significance.

RESULTS

This study was performed at department of plastic, reconstruction and burn surgery, Menoufia faculty of medicine, Egypt in the period between March 2017 to March 2019.

Table 1: Age and genders of the participating patients.

Age (in years)->	5-20	21-40	41-55	Total
Females	6	7	6	19
Males	4	5	2	11
Total	10	12	8	30

It included 30 patients complaining of post burn neck contracture. 19 patients (63.33%) were females and 11 patients (36.67%) were males. The ages varied from 5 years to 56 years (mean age 29.7 years): 10 patients (33.33%) were below age of 20 years, 12 patients (40%) were in the ages between 20 and 40 years, and 8 patients (26.67%) were above the ages of 40 years (Table 1).

Each patient was submitted to the suggested algorithm system (with a total score of 12 points) and given a score. And accordingly, was categorized into one of the following four grades:

Grade 1 (12, 11, 10 score points) patients of multiple Z plasty would be suitable for them (Figure 1) and this grade included 8 patients.

Grade 2 (9 and 8 score points) patients of local flaps (e.g. cervical flap) and proximal axial flaps (e.g. supraclavicular flap, trapezius flap) would be suitable for them. But if a large area affected, it could be associated with grafting (Figure 2-4) this grade included 12 patients.

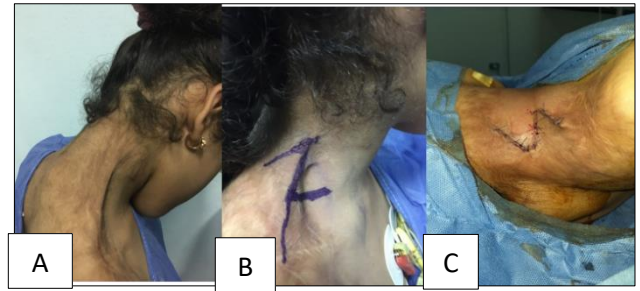


Figure 1: Female patient 9 years old with post burn neck contracture (grade I), (A) preoperative, (B) planning of the Z plasty operation and (C) postoperative after Z plasty.

Grade 3 (7 and 6 score points) patients of distal axial flaps (e.g. latissimus dorsi flap) would be suitable for them. About if a large area affected, it could be associated with grafting (Figure 5), this grade included 6 patients.

Grade 4 (less than 6 score points) patients of split thickness grafting would be suitable for them (Figure 6) and this grade included 4 patients.

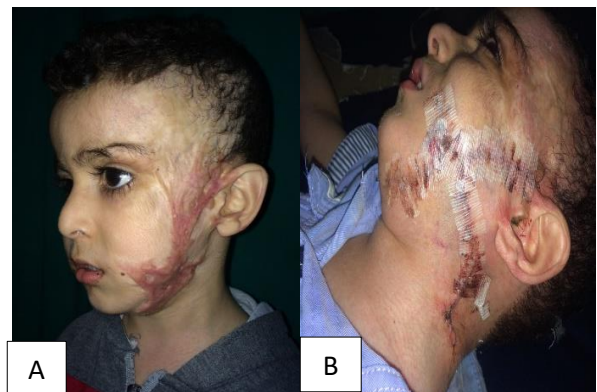

Figure 2: Male patient 6 years old with post burn neck contracture (grade I), (A) preoperative, and (B) postoperative after local skin flaps.

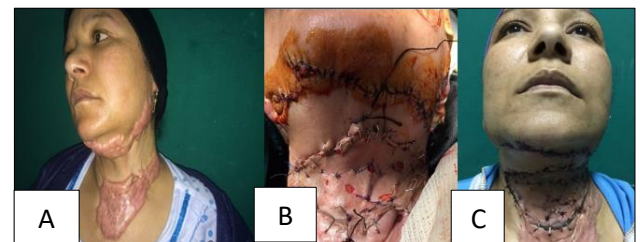


Figure 3: Female patient 46 years old with post burn neck contracture (grade II extensive), (A) preoperative, (B) intraoperative repair by raising a bipedicle skin flap associated with partial thickness skin grafting and (C) postoperative.

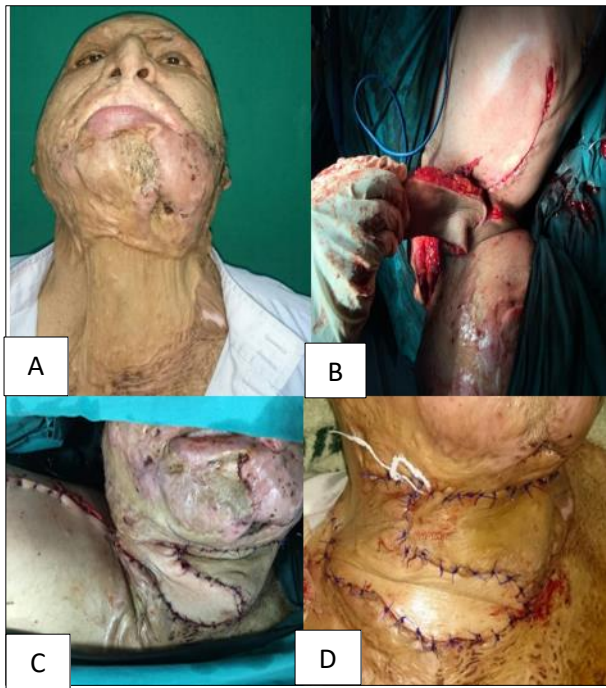

Figure 4: Male patient 47 years old with post burn neck contracture (grade II extensive), (A) preoperative, (B) intraoperative repair by raising a supraclavicular skin flap, (C) immediate postoperative and (D) postoperative after 1 week.

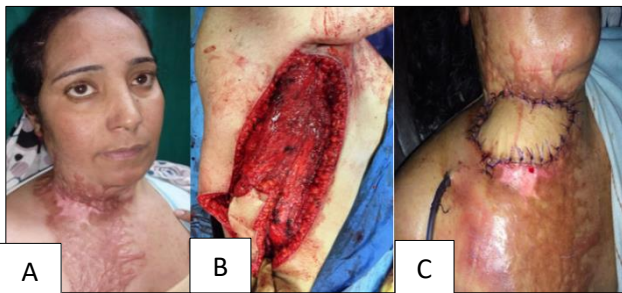


Figure 5: Female patient 43 years old with post burn neck contracture (grade III), (A) preoperative, (B) Intraoperative repair by raising a Lasissimus dorsi flap and (C) postoperative.

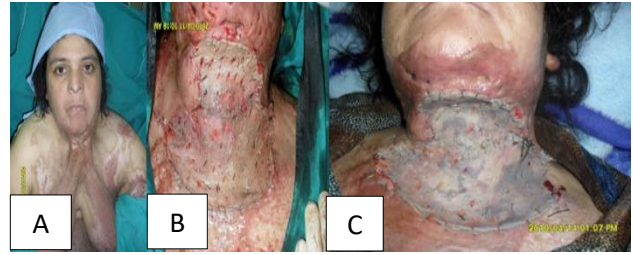


Figure 6: Female patient 50 years old with post burn neck contracture (grade IV): (A) preoperative, (B) intraoperative repair by partial thickness skin grafting and (C) postoperative.

The aim of these grades was to choose the ideal method of management and gain the best surgical results possible when performing surgical correction according to the previous scoring system. So, after applying the surgical solutions suggested by the algorithm system, 25 patients showed great satisfaction to their post operative's outcomes with significant ($p < 0.05$) and 5 patients were poorly satisfied (Table 2) as 7 patients (87.5%) categorized grade 1 were satisfied and 1 patient (12.5%) was unsatisfied, 11 patients (91.67%) categorized grade 2 were satisfied and 1 patient (8.33%) was unsatisfied, 5 patients (83.33%) categorized grade 3 were satisfied and 1 patient (16.67%) was unsatisfied and 2 patients (50%) categorized grade 4 were satisfied and 2 patients (50%) were unsatisfied.

Complications that happened to some of the patients were partial flap dehiscence and necrosis which happened to three patients, they needed debridement and secondary sutures which were enough, partial skin graft loss which happened to three patients also, two healed with continuous dressing and one needed secondary skin grafting.

Recurrence with long term follow up, recurrence was noticed in about six patients, but to a milder degree than the previous condition. Small local flaps or grafting was enough for solving this problem.

Table 2: Relation between the grades of the suggested algorithm and patient's satisfaction.

Patient satisfaction	Grade 1	Grade 2	Grade 3	Grade 4	Total
Satisfied	7	11	5	2	25
Unsatisfied	1	1	1	2	5
Total	8	12	6	4	30

DISCUSSION

The head and neck areas are the most important aesthetic and functional regions in the burnt patients. Unlike most joints which are in maximal flexion (e.g. ankle) or extension (e.g. knee) position, the head is usually in a

neutral position between flexion and extension in the erect position due to maintained static tone of sternomastoid muscles on both sides of the neck. But in case of patients with deep extensive burn injury to the neck region, the patient usually maintains the flexion position to decrease pain sensation; resulting in chronic flexion contracture while healing.⁸

Applying flaps for post burn neck contracture is superior than grafting the total released area, as we introduce normal textured elastic skin to the released area which will increase range of motion of the head and neck and decrease possibility of recurrence of contracture. Still, we would still need grafting if large areas are affected as flaps might not be enough the total released area.³

There were several classifications as we mentioned before based on the position of the lesion, position of the head and the ability to extend the head. Onah introduced a classification including categories of 1-4, based on the existing position, severity and problems. Subgroups within each category expressed the width of the contracture.⁷ Tsai et al, classification depended on the zones of anterior cervical scar contractures in burn patients. This classification was guided only toward microsurgical interference and did not deal with the scar shape or width.⁹ Makboul et al, classification was simpler than Onah classification, but still only depending on the site and width of the scar.⁸

In addition to the differences between them and our algorithm system, they were still helpful in simplifying the status of post burn contracture categorization with no obvious special purpose for applying them, unlike this algorithm system which is directed towards choosing the suitable method of surgical reconstruction.⁵⁻⁸

This algorithm system also covered analyzing the full range of motion of head and neck, focused on the extent of burn injury to the neck and surrounding areas as a main aspect of categorization, which was not considered in the previously mentioned classifications.⁵⁻⁸

In addition ,this algorithm system introduced a variety of surgical solutions that were not suggested in Onah and Makboul et al. classifications such as axial flaps from surrounding healthy areas (eg. Supraclavicular flaps) or from distant areas (eg. Latissimus dorsi flaps) in addition to multiple z and local flaps.^{7,8} This would surely help in choosing more appropriate methods with better aesthetic and functional outcomes.

CONCLUSION

This post burn contracture algorithm system is simple, effective and could be used by young surgeons to help them make surgical plans for post burn neck contracture, even if they lack experience towards these patients.

Funding: No funding sources

Conflict of interest: None declared

Ethical approval: The study was approved by Menoufia University-Faculty of Medicine`s the Institutional Ethics Committee

REFERENCES

1. Edlich RF, Nichter LS, Morgan RF, Persing JA, Van Meter CH Jr, Kenney JG. Burns of the head and neck. *Otolaryngol Clin North Am.* 1984;17:361-88.
2. Pallua N, Künsebeck HW, Noah EM. Psychosocial adjustments 5 years after burn injury. *Burns.* 2003;29:143-52.
3. Kobus K, Stepniewsky J. Surgery of post-burn neck contractures. *Eur J Plast Surg.* 1988;11:126-8.
4. Voinchet V, Bardot J, Echinard C, Aubert JP, Magalon G. Advantages of early burn excision and grafting in the treatment of burn injuries of the anterior cervical region. *Burns.* 1995;21:143-6.
5. Kirschbaum S. Mentosternal contracture: preferred treatment by acromial flap. *Plast Reconstr Surg.* 1958;21:131-8.
6. Achauer BM. Neck reconstruction. In: Achauer BM, ed. *Burn Reconstruction.* New York, NY: Thieme Medical Publishers; 1991: 79-86.
7. Onah II. A Classification System for Postburn Mentosternal Contractures. *Arch Surg.* 2005;140:671-5.
8. Makboul M, El-Oteify M. Classification of post-burn contracture neck. *Ind J Burns.* 2013;21:50-4.
9. Tsai FC, Mardini S, Chen DJ, Yang JY, Hsieh MS. The classification and treatment algorithm for post-burn cervical contractures reconstructed with free flaps. *Burns.* 2006;32:626-33.

Cite this article as: Hassan MS. Post burn neck contracture: an algorithm for choosing the ideal surgical method of management. *Int Surg J* 2020;7:547-51.