

## Original Research Article

# The role of thoracodorsal artery perforator flap after breast conserving surgery

Fatemah El-Gapaty<sup>1\*</sup>, Shawky Skaker<sup>2</sup>, Ahmed Sabry<sup>2</sup>, Ahmed Taalab<sup>3</sup>

<sup>1</sup>Department of Surgery, Faculty of Medicine, Tanta University, Egypt

<sup>2</sup>Department of Surgery, <sup>3</sup>Department of Plastic Surgery, Faculty of Medicine, Menoufia University, Egypt

**Received:** 09 December 2020

**Revised:** 27 March 2021

**Accepted:** 01 April 2021

**\*Correspondence:**

Dr. Fatemah El Gapaty,

E-mail: Karimshady90@hotmail.com

**Copyright:** © the author(s), publisher and licensee Medip Academy. This is an open-access article distributed under the terms of the Creative Commons Attribution Non-Commercial License, which permits unrestricted non-commercial use, distribution, and reproduction in any medium, provided the original work is properly cited.

### ABSTRACT

**Background:** The emergence of thoracodorsal artery perforator flap combined with radiotherapy as new techniques in breast reconstruction has resulted in greater focus on oncoplastic breast surgery. In this study, we studied the role of thoracodorsal artery perforator flap after breast conserving surgery.

**Methods:** This study included 40 patients of stage I and II breast cancer at Menoufia University hospital from July 2018 to February 2019. Every patient accepted to be enrolled in this study with curative intent by having breast conservative surgery and immediate reconstruction by TDAP flap.

**Results:** The mean operative time was 145 min. Seroma is the commonest complication following TDAP flap reconstruction and occurred in four cases (20%) and was treated by repeated aspiration. The cosmetic outcome was acceptable with 90% of patients rating their outcome as either pleased or satisfied. The subjectively assessed functional outcome showed a mean time of 10 days postoperative for patients to regain their full range of shoulder movements.

**Conclusions:** Thoracodorsal artery perforator flap can play a significant role in oncoplastic surgery and breast reconstruction with acceptable cosmetic and functional outcome.

**Keywords:** Thoracodorsal Artery, Breast cancer, Reconstruction, Flap

### INTRODUCTION

Breast cancer is the most commonly occurring cancer in women and the second most common cancer overall. There were over nearly 2 million new cases diagnosed in 2018, representing about 25 per cent of all cancers in women. Incidence rates vary widely across the world, from 27 per 100,000 in Middle Africa and Eastern Asia to 92 per 100,000 in Northern America. It is the fifth most common cause of death from cancer in women, with an estimated 522,000 deaths (6.4% of the total). It is also the most frequent cause of cancer death in women from regions characterised by lower indices of development and/or income (14.3% of deaths), and the second most frequent from regions characterised by higher indices of

development and/or income (15.4% of deaths), after lung cancer.<sup>1</sup>

Early diagnosis can partially be achieved through rapid access referral, accurate triple assessment and multidisciplinary management of potential breast cancer patients. All patients presenting with breast symptoms should undergo triple assessment, this involves history taking and examination, followed by breast imaging and pathological assessment.<sup>2</sup>

The surgical management of breast cancer has witnessed a considerable evolution in the past few decades. Breast conserving therapy is the mainstay treatment for early-stage breast cancer.<sup>3</sup> The advent of oncoplastic surgery

has brought new dimensions to breast conserving surgery and included the aesthetic principles of breast surgery to cancer management.<sup>4</sup>

Breast-conserving surgery combined with radiation is now well established as the preferred local-regional treatment for a majority of patients with early stage breast cancers. There are no statistically significant differences in the survival rate or in the incidence of the development of new cancers between women treated with mastectomy and those treated with breast conservation therapy.<sup>4</sup> Breast conserving surgery appears to offer advantages over mastectomy with regard to quality of life and aesthetic outcomes.<sup>5</sup>

The harvest of these flaps often left significant morbidities such as the abdominal wall weakness and the seroma in the back. Nowadays the breast surgeon is more than often faced with smaller defects for which such bulky flaps offer a surplus of tissue with unacceptable morbidities compared to the smaller defects these flaps have to reconstruct. Improvements in our knowledge of the vascular anatomy have enabled the design of a new type of fasciocutaneous flaps, which are based on perforating vessels only.<sup>6</sup> Thus, donor site morbidity is markedly reduced.

Surgeons have attempted to develop various partial breast reconstruction techniques to improve the breast asymmetry (or overall body image) resulting from BCS, as measures to improve patients' QOL. However, there is no consensus as to the best oncoplastic breast surgical technique for any given situation. Hence, surgeons make the decisions on reconstruction techniques based on breast size and the defect-to-breast-volume ratio following tumor excision.<sup>7</sup>

Koshima and Soeda introduced the concept of "perforator flaps" in 1989, when they reported the use of a flap consisting of paraumbilical skin and fat based on a muscular perforator to reconstruct defects in the groin and the tongue.<sup>8</sup> In 1995, Angrigiani et al described the thoracodorsal artery perforator flap (TDAP) for the first time.<sup>9</sup> However, Hamdi et al were the first to describe the use of TDAP in breast reconstruction in 2004.<sup>10</sup>

## METHODS

During the period from July 2018 to February 2019, this prospective randomized controlled study was conducted on 40 patients suffering from early breast cancer (stage I and II) at Menoufia university hospital. Every patient accepted to enroll in current study with curative intent by having breast conservative surgery and immediate reconstruction by TDAP flap.

### Inclusion criteria

Inclusion criteria for current study were; patients with early stage breast cancer at upper outer quadrant who

were willing for conservative breast surgery and immediate reconstruction and patient with T1 or T2 lesions.

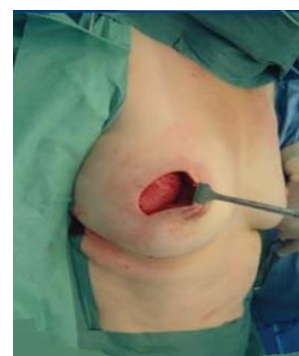### Exclusion criteria

Exclusion criteria for current study were; locally advanced breast cancer (T3, T4) lesions, metastatic disease, inflammatory breast cancer, absolute contraindication to conservative breast surgery with skin systemic (scleroderma-tielangectazia) and central tumor, patient with medical disease contraindicating for general anesthesia, and patients who don't prefer breast reconstruction.

### Preoperative assessment

History and physical examination, routine labs, metastatic work up, preoperative counselling session by the operating surgeon were done to explain the operative procedure and expected complications, patients underwent a handheld Doppler mapping and marking of the thoracodorsal artery perforators on the night before surgery by the operating surgeon. Preoperative marking of the area was done to be resected and the area of flap harvest with dimensions being recorded. The surgery was done under general anesthesia on supine position then lumpectomy followed by frozen section and homeostasis.

After resection of the mass with safety margin 2 cm all around the mass through obtuse incision in the upper outer quadrant was done and the anterior (upper) aspect of the artery was anastomosed with a 6.0 polypropylene (Figure 1). The tumor margin invasion was evaluated at the resection margin using the frozen section in the operating room.

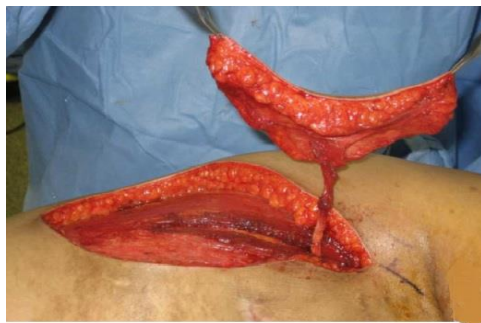


**Figure 1: Setting the flap into the post-lumpectomy defect.**

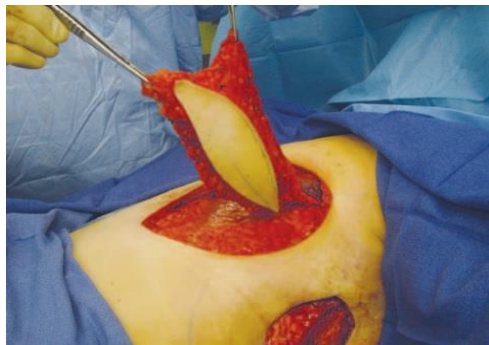
Perfect homeostasis was ensured then axillary dissection was done in all cases with special attention to presume. Once dissection of the vessels was complete, the skin paddle was carefully passed through the split LD muscle, then subcutaneously through the auxiliary region into the breast defect. The donor site was closed primarily. Operative time was recorded, and postoperatively during

hospital stay flaps were followed up for colour, temperature and capillary circulation and drains for colour and amount of output and early complications were recorded. Patients were reviewed by operating surgeon one week then two weeks postoperatively and postoperative photographs were taken in three views and all complications that have developed were recorded and dealt with.

Drains were removed when their output was equal to or less than 50 cc. Patients were then referred to receive their adjuvant treatment according to their final pathology report. After finishing their adjuvant treatment patients were invited again to be reviewed by the operating surgeon where they were photographed in three views.



**Figure 2: Thoracodorsal vessels dissected until enough length is achieved to allow inseting of the flap with no tension.**



**Figure 3: The flap was completely de-epithelialized.**

**Statistical analysis**

The collected data were organized, tabulated and statistically analyzed using SPSS software (statistical package for the social sciences, version 21, SPSS Inc. USA). Data were described using mean and standard deviation (SD) and frequencies according to the type of the data (quantitative or categorical respectively). Chi-square and fisher exact test were used for comparison of qualitative variables. We used one way ANOVA test to compare between means of categorical and numerical data. Significance level was adopted at  $p < 0.05$  for interpretation of results for tests of significance.

**RESULTS**

Patients in the study were studied regarding age, marital status, parity and lactation. Ages of patients in this study ranged from 24 to 56 years old with mean 42.35 years. Thirty patients (75%) were married, 8 patients (20%) were single and two patients (5%) was divorced. 28 patients (70%) were multipara and 12 patients (30%) were nullipara. 28 patients (70%) were lactating and 12 patients (30%) were non-lactating.

**Table 1: Socio-demographic characteristics of the studied patients.**

Variables (n=20)		N	%
<b>Age (years)</b>	Mean±SD	42.35±9.25	
	(range)	(24-56)	
<b>Marital status</b>	Married	30	75
	Divorced	2	5
	Single	8	20
<b>Parity</b>	Multipara	28	70
	Nulliparous	12	30
<b>Lactation</b>	Positive	28	70
	Negative	12	30

Patients in the study were selected to have early stage breast cancer (stage I and II). TDAP was done for all patients (40 cases), 16 patients (40%) had underwent TDAP for T1 tumors and 24 patients (60%) for T2 tumors. All patients were scheduled for complete axillary dissection including all axillary levels (I, II and III). Flaps were successfully transferred with an average operative time of 145 minutes (range 120-180 minutes) (Table 2). The largest dimensions of TD AP flap used were 20x8 cm (range of 12-20 cm long and 5-10 cm wide). All the flaps were based on a single perforator artery (17 cases, 85%), except in 3 cases (15%) in which 2 perforators from the same vertical branch of the thoracodorsal artery were isolated and used there was no any case had received blood transfusion.

**Table 2: Operative data of the studied patients.**

Variables (n=20)		N	%
<b>Operative time (minutes)</b>	Mean±SD;	145±19.87;	(120-180)
	(range)		
<b>Harvested flaps measurements (mm)</b>	Mean±SD;	125.5±38.89;	(65-200)
	(range)		
<b>Number of perforators</b>	1	17	85.0
	2	3	15.0
<b>Bl. transfusion</b>	Positive	0	0.0
	Negative	20	100.0

Hospital stay was calculated from the day of the operation to the day of discharge (Table 3). The mean duration of hospital stay was 7.85 days with a range of 6-12 days. The complications were related to both the flap

and the donor site (Table 3). There were two cases (5%) of partial flap necrosis. Hematoma under the flap was observed in 4 cases (10%) and was evacuated. Seroma the commonest complication following TDAP flap reconstruction and occurred in eight cases (20%) and was treated by repeated aspiration. Excellent results were observed in 20 cases (50%) (Table 4). Good results were observed in 16 cases (40%). Fair results were observed in 4 cases (10%). No poor result was reported after reconstruction.

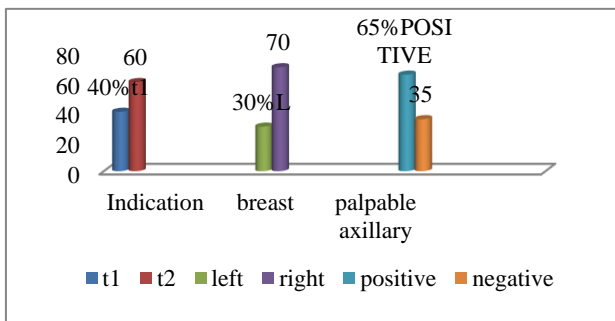


Figure 4: Clinical data of the studied patients.

Table 3: Post-operative follow up and complications.

Variables (n=20)	N	%
<b>Hospital stay</b>	Mean±SD; (range)	3.85±1.46; (2-4)
<b>Flap necrosis</b>	No	38 95.0
	Partial	2 5.0
<b>Hematoma</b>	Positive	4 10.0
	Negative	36 90.0
<b>Seroma</b>	Positive	8 20.0
	Negative	32 80.0
<b>Infection</b>	Positive	4 10.0
	Negative	36 90.0
<b>Hypertrophic scar</b>	Positive	4 10.0
	Negative	36 90.0

Table 4: Aesthetic grades of reconstructed breasts.

Aesthetic grade (n=20)	N	%
<b>Grade I (poor)</b>	0	0.0
<b>Grade II (fair)</b>	4	10.0
<b>Grade III (good)</b>	16	40.0
<b>Grade IV (excellent)</b>	20	50.0

## DISCUSSION

Immediate breast reconstruction has become in many medical centers the standard of care for women who need or desire surgical restoration of a breast mound after surgical excision of breast cancer. The shift from delayed to immediate reconstruction has occurred for many reasons including patient preference, lower cost, improved patient convenience, reduced anesthetic risk, and the less end emotional trauma associated with immediate reconstruction (provided that not affecting

adjuvant therapy, so not affecting survival or increasing incidence of local recurrence).<sup>11</sup>

Reconstruction with autogenous tissue avoids all of the potential complications of implants in terms of infection, dehiscence, exposure, distortion, deflation and contracture. The reconstructed breast mimics the normal breast far better than any prosthesis. While initially more complex and expensive, autogenous breast reconstructions are the most accepted and durable breast reconstruction that generally hold up well for the patient's life. Because of this freedom from late problems, autogenous reconstructions have been found to be less cost than implant based reconstructions.<sup>12</sup>

Immediate breast reconstruction does not interfere with the resumption of chemotherapy or the ability to detect loco regional recurrence, the cosmetic result was dependent on the initial outcome of the reconstruction. If fat necrosis was present however, irradiation tended to accentuate fibrosis and volume loss.<sup>13</sup>

Autologous tissue breast reconstruction is considered a reliable surgical technique. The LD-MC flap has been the "workhorse" for treating difficult or complicated cases as well as for primary reconstruction lip transference to the conventional LD-MC flap has been reported to increase its initial volume and improve autologous breast reconstruction. Morbidity of the donor area might be considered a disadvantage, albeit to a minimal extent, for this procedure. Muscle harvesting remains controversial, with conflicting favorable and negative report on the technique.<sup>14</sup>

The incorporation of the TDAP flap, a derivation of the perforator flap era and which was initially described as "the LD-MC flap without muscle", permits harvesting, of the same skin and subcutaneous tissue area normally obtained with the conventional LD-MC flap without the muscle, thereby avoiding the possible morbidities of this procedure. The presence of the muscle might be considered important considering the necessity of volume for the reconstruction. However, voluminous part of the muscle remains under the axilla after transferring the flap to the anterior area. The muscle transferred to the breast mound is quite thin, with minimal volume contribution.<sup>15</sup>

The thoracodorsal artery perforator flap (TDAP) was first described by Angrigiani-1995, and perforator landmarks were established by him.<sup>16</sup>

Current study was conducted on 40 patients with early breast cancer, in whom conservative breast surgery was indicated during the period from (July 2018 to January 2020.) Findings of current study revealed that twenty patients with potentially curable breast cancer who are good candidates for TDAP were selected.

In a study done by Koutz et al they have focused on factors that influence the decision to have breast

reconstruction. Patients decided IBR to be able to wear free clothing styles in 83%, to eliminate external prosthesis in 90%, to feel more balanced in 72%, to feel more feminine in 69%, and to be morally satisfied in 95%. They stated that breast reconstruction has been shown to lesser psychological disturbances and the number of women who have undergone reconstruction has increased dramatically.<sup>17</sup> In current study, patient motivation for breast reconstruction were studied. 10% of patients preferred reconstruction to be satisfied morally and to avoid external prosthesis. Aesthetic purposes was the issue of concern in 40% of patient, however, none of patient had tendency for wearing free clothing styles.

The pedicle TDAP flap can be used for partial breast reconstruction after lumpectomy or as additional bulk for previously reconstructed breast or for complete breast reconstruction with expander or implant. However, the indication to choose the TDAP flap over the classical LD flap remain unclear, since the harvesting of the TDAP flap is more technically demanding and there are no studies that compare donor site morbidity between these flap.<sup>17</sup> In current study, all patients were scheduled for conservative breast surgery, where the breast mass was excised with safety margin and axillary dissection was undertaken for three levels. In 12 patients (30%), mass was located in left breast, while in 28 patients (70%), the right breast was the side affected by the tumor. Regarding the nodal status, all patients were scheduled for complete axillary dissection including all axillary levels (I, II and III), seven patients (35%) had negative axillary nodes and thirteen patient (65%) had positive nodes.

Oncology safety of conservative breast surgery and reconstruction with TDAP has not yet been fully demonstrated. Best available evidence suggests that patients should be selected based on study of breast duct anatomy by breast magnetic resonance imaging, mammographic distance between tumor and nipple and obligatory intra-operative frozen section from retro-areolar tissue. Additional factors such as tumor size, axillary lymph node status, lymphovascular invasion and degree of intraductal component are also being used.<sup>18</sup> Hamdi et al reported in their study the harvested flaps measured 23x8.8 cm (range of 20-30 long and 8-10 cm wide). The flaps were successfully transferred with an average operative time of 190 minutes (range 135-260 minutes). The flaps were harvested based on the perforator in all 4 patients. Jain et al reported in their study the maximum length of flap that can be taken based on a single perforator needs to be assessed.

Hospital stay was calculated from the day of the operation to the day of discharge. The mean duration of hospital stay was 7.85 days with a range of 6-12 days. Judkins et al studied the advantages, disadvantages and results that can be expected after immediate breast reconstruction utilizing TDAP flap in 100 patients with an average length of follow up was 20 months (range 8 to 44 months). The major complications were rare (1%

partial necrosis and 1% total necrosis). The minor complications were represented mainly with dorsal seroma and were the main drawback of the technique and occurred in 79% especially in obese patients. Donor site morbidity in terms of wound infection and scarring was relatively low and occurred in 4% of cases. They reported that the level of patient satisfaction was high 87% of the patients were deeply satisfied, 10% were satisfied and only 3% were poorly satisfied. The aesthetic results have been judged excellent by surgeons in 85%, good in 12% and poor in 3% and no results judged bad. They concluded that breast reconstruction after SSM by LD flap with implant was encouraging and brings a major advance in breast reconstruction.<sup>18-20</sup> Hamdi et al reported in their study the postoperative period was uneventful. Wound healing was achieved. A seroma formation did not occur in any case. None of the patients had any subjective functional impairment within an average follow-up of 12 months.

When using TDAP flaps, the donor site shows similar complications to those which appear when using latissimus dorsi muscle flaps. It is recommended not to take more than an 8 cm width for the flap. The sparing of the muscle may add more tension when primary closing is intended. Excellent results were observed in ten cases (50%). Good results were observed in eight cases (40%). Fair results were observed in two cases (10%). No poor result was reported after reconstruction.

The role of TDAP flap in breast reconstruction still needs to be established. Its potential advantages or disadvantages, when compared with latissimus dorsi flap reconstruction are yet in question. Still, it is believed there are important advantages to this flap. First, several studies showed that after transfer of the LD muscle, shoulder strength and/or the range of motion deteriorate. In addition, preserving the LD muscle is probably less painful postoperatively. Second, harvesting of the LD muscle results in high seroma rate of the donor site. Third, the aesthetic result might be somewhat superior with the TDAP flap because of preservation of the posterior axillary fold.<sup>19</sup>

The versatility of TDAP has several advantages that itaworkhorse flap for most reconstructions requiring soft tissue cover. Further, the ease of harvest makes it a good perforator flap for beginners. Its use in chimerism with the underlying latissimus dorsi muscle provides reconstruction for coverage and volume replacement.<sup>20</sup>

## CONCLUSION

Thoracodorsal artery perforator flap represents a valid and safe option, which adds to the reconstructive arsenal of oncoplastic surgeons. This technique combines the advantages of perforator flaps in reducing donor site morbidities to an absolute minimum, and the advantages of pedicled flaps, which do not require sophisticated microvascular anastomoses. Thus, it can achieve an

acceptable cosmetic outcome with minimal donor site morbidity. Finally, proper case selection and preoperative Doppler mapping are recommended to ensure good results.

*Funding: No funding sources*

*Conflict of interest: None declared*

*Ethical approval: The study was approved by the Institutional Ethics Committee*

## REFERENCES

1. Fisher B, Land S, Mamounas E, Dignam J, Fisher ER, Wolmark N. Prevention of invasive breast cancer in women with ductal carcinoma in situ: an update of the National surgical adjuvant breast and bowel project experience. *Semin Oncol.* 2001;28(4): 400-18.
2. Shokuhi S, Parker SJ. Management of breast cancer: basic principles. *Surg.* 2007;25(6):261-3.
3. Sakorafas GH. Breast cancer surgery--historical evolution, current status and future perspectives. *Acta Oncol.* 2001;40(1):5-18.
4. Noguchi M, Yokoi-Noguchi M, Ohno Y, Morioka E, Nakano Y, Kosaka T, et al. Oncoplastic breast conserving surgery: Volume replacement vs. volume displacement. *Eur J Surg Oncol.* 2016;42(7):926-34.
5. Curran D, van Dongen JP, Aaronson NK, Kiebert G, Fentiman IS, Mignolet F, Bartelink H. Quality of life of early-stage breast cancer patients treated with radical mastectomy or breast-conserving procedures: results of EORTC Trial 10801. *Eur J Cancer.* 1998; 34(3):307-14.
6. Johnstone MS. Vertical rectus abdominis myocutaneous versus alternative flaps for perineal repair after abdominoperineal excision of the rectum in the era of laparoscopic surgery. *Ann Plast Surg.* 2017;79(1):101-6.
7. Kim JB, Kim DK, Lee JW, Choi KY, Chung HY, Cho BC, et al. The usefulness of pedicled perforator flap in partial breast reconstruction after breast conserving surgery in Korean women. *Arch Plast Surg.* 2018;45(1):29-36.
8. Blondeel PN. The gent consensus on perforator flap terminology: preliminary definitions. *Plastic Reconstruct Surg.* 2003;112(5): 1378-83.
9. Angrigiani C, Rancati A, Escudero E, Artero G, Gercovich G, Deza EG. Propeller thoracodorsal artery perforator flap for breast reconstruction. *Gland Surg.* 2014;3(3):174-80.
10. Hamdi M, Khuthaila DK, Van Landuyt K, Roche N, Monstrey S. Double-pedicle abdominal perforator free flaps for unilateral breast reconstruction: new horizons in microsurgical tissue transfer to the breast. *J Plast Reconstr Aesthet Surg.* 2007;60(8):904-12.
11. Parker PA, Youssef A, Walker S, Basen-Engquist K, Cohen L, Gritz ER, Wei QX, Robb GL. Short-term and long-term psychosocial adjustment and quality of life in women undergoing different surgical procedures for breast cancer. *Ann Surg Oncol.* 2007; 14(11):3078-89.
12. Beahm EK, Walton RL. Revision in autologous breast reconstruction: principles and approach. *Clin Plast Surg.* 2007;34(1):139-62.
13. Ahmed FK, Mohammed HM, Mahmoud AA. Skin-sparing mastectomy with immediate latissimus dorsi flap reconstruction versus delayed reconstruction after modified radical mastectomy. *Int Surg J.* 2019; 6(10):3543-7.
14. Khajuria A, Mosahebi A. Outcome reporting in breast reconstruction. *J Plast Reconstr Aesthet Surg.* 2019;72(10):1700-38.
15. Roy MK, Shrotia S, Holcombe C, Webster DJ, Hughes LE, Mansel RE. Complications of latissimus dorsi myocutaneous flap breast reconstruction. *Eur J Surg Oncol.* 1998;24(3):162-5.
16. Angrigiani C, Rancati A, Escudero E, Artero G. Extended thoracodorsal artery perforator flap for breast reconstruction. *Gland Surg.* 2015;4(6):519-27.
17. Hamdi M, Van Landuyt K, Monstrey S, Blondeel P. Pedicled perforator flaps in breast reconstruction: a new concept. *Br J Plast Surg.* 2004;57(6):531-9.
18. Mariotti C, Raffaelli E. The surgical treatment of DCIS: from local excision to conservative breast surgery and conservative mastectomies. *Ductal Carcinoma in Situ of the Breast.* Germany: Springer; 2018:107-42.
19. Adler N, Seitz IA, Song DH. Pedicled thoracodorsal artery perforator flap in breast reconstruction: clinical experience. *Eplasty.* 2009;9:e24.
20. Ortiz CL, Mendoza MM, Sempere LN, Sanz JS, Torres AN, Barraquer EL. Versatility of the pedicled thoracodorsal artery perforator (TDAP) flap in soft tissue reconstruction. *Ann Plast Surg.* 2007;58(3): 315-20.

**Cite this article as:** EL-Gapaty F, Skaker S, Sabry A, Taalab A. The role of thoracodorsal artery perforator flap after breast conserving surgery. *Int Surg J* 2021;8:1407-12.