

## Case Report

# Very rare giant adrenal myelolipoma: a tumor mimic

Aditya Prasad Padhy\*, Abinash Kanungo, Deepak Kumar Das, Sunny

Department of General Surgery, Kalinga Institute of Medical Sciences, Bhubaneswar, Odisha, India

**Received:** 10 December 2019

**Accepted:** 09 January 2020

**\*Correspondence:**

Dr. Aditya Prasad Padhy,

E-mail: [docadityapadhy@gmail.com](mailto:docadityapadhy@gmail.com)

**Copyright:** © the author(s), publisher and licensee Medip Academy. This is an open-access article distributed under the terms of the Creative Commons Attribution Non-Commercial License, which permits unrestricted non-commercial use, distribution, and reproduction in any medium, provided the original work is properly cited.

### ABSTRACT

Adrenal myelolipoma is a very rare benign neoplasm usually unilateral, and nonsecreting, occurring in the adrenal gland which consist of fatty tissues and hematopoietic elements. Some cases of this type may cause symptoms like chronic abdominal pain however usually these tumors are small and asymptomatic. Surgery is the modality of treatment where there are severe symptoms with life threatening progression with size of tumor reaching more than 6 cm. Here we report an unusual case of a 59-year-old male with history of chronic abdominal pain from a growing right-sided large adrenal mass. With all possible hematological, histo-pathological as well as imaging investigations warranted a high suspicion for tumor mass, hence decided for surgically excision, which was both diagnostic as well as curative. The histopathological study of the excised mass confirmed the initial diagnosis of adrenal myelolipoma. Surgery is the diagnostic and curative modality of treatment for adrenal myelolipoma after all possible investigations to reach for a clinical diagnosis as well for proper planning for surgery. By this we can prevent complications like spontaneous rupture and hemorrhage of the mass, and subsequent cardiovascular shock. Management varies from individual to individual. Open radical adrenalectomy is the standard treatment for giant myelolipomas (size >10 cm), while the minimally invasive approach has been used in only few cases of small sized tumors. Although it is a benign tumor, surgery plays main role for symptomatic cases and high suspicion of malignancy.

**Keywords:** Adrenal myelolipoma, Adrenal gland, Benign condition, Surgical excision

### INTRODUCTION

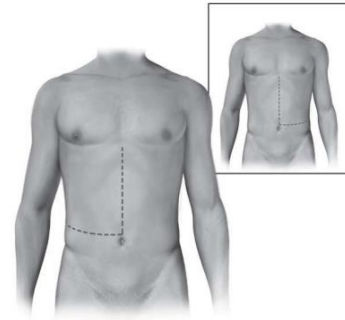
Adrenal myelolipoma is very rare and non-functional, benign tumor, predominantly occurs in the adrenal gland. and composed of varying amounts of macroscopic adipose tissues and mature hematopoietic elements, resembling bone marrow.<sup>1</sup> It effects men and female equally mostly during 5<sup>th</sup> to 7<sup>th</sup> decade of life. Incidental detection is most common.<sup>2,3</sup> Exact incidence of these tumors not known where as some studies have found out the incidence to be 0.008-0.4%.<sup>3</sup> It has been seen the size of these tumors can vary from as small as 4 cm to as large as 31 cm till date.<sup>7</sup> The small size (usually <4 cm) are asymptomatic hence treated conservatively. Surgical management is recommended when becomes symptomatic, or grows quickly or to attain a size of

>6 cm.<sup>4</sup> In case of malignant or potentially malignant tumors, adrenalectomy must be performed.<sup>5</sup> Giant myelolipoma is when its greatest diameter attains >10 cm.<sup>6</sup> Most often the right adrenal gland is the origin, but other sites, such as the presacral area, spleen, stomach, lung, liver, retroperitoneum and testis, are also reported.<sup>8,9</sup> Here we discuss about a case of incidental diagnosis of adrenal myelolipoma in a 59 year old male who presented with pain abdominal pain diagnosis, review the literature and management.

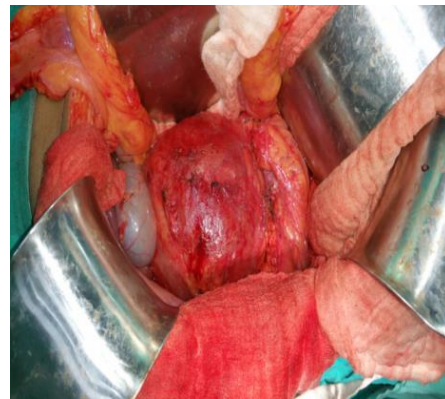
### CASE REPORT

A 59-year male, with complaining of pain abdomen for 6 months, no history of nausea/vomiting/fever. Normal bowel bladder habit. A known case of hypertension

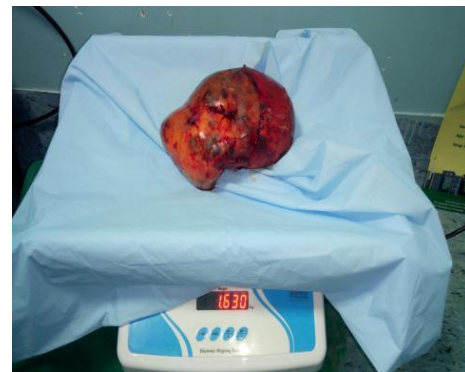
(HTN), sickle cell and  $\beta$ -thalasemia trait. On examination vitals stable, abdomen soft, distended, large mass palpable in right lumbar region, occupying towards umbilical region also, of size approximately 15 cm  $\times$  10 cm, firm, restricted mobility, not moving with respiration, margins are not well defined. Ultrasonography (USG) whole abdomen and pelvis. Large right sub hepatic and supra renal mass likely adrenal mass, cholelithiasis, prostomegaly with significant post-void residual urine (PVRU) were noticed. Blood investigations was with in normal limit except liver function tests (LFTs) in which total bilirubin was 4.46 mg/dl, direct bilirubin was 1.71 mg/dl, hemoglobin (Hb) electrophoresis showed heterozygous sickle and  $\beta$ -thalasemia. Plasma adrenocorticotropic hormone (ACTH), serum cortisol, dexamethasone supression test, urinary metanephine and Nor-metanephine, serum lactate dehydrogenase (LDH), beta-human chorionic gonadotropin (hCG), alpha-fetoprotein (AFP), dehydroepiandrosterone sulfate (DHEAS), estradiol, testosterone were within normal limit. Magnetic resonance imaging (MRI) and contrast-enhanced computed tomography (CECT) abdomen were large heterogeneous mass of size 22 x 16.5 x 13.5 cm in right suprarenal region. Displacing right kidney, liver, duodenum and pancreas. Small calcification foci with thickening of peri and paranephric fat. Splenomegaly with multiple calcification. 7 x 7 cm fat density lesion in left adrenal. Cholelithiasis (3.6 mm calculus) (Figure 1). USG guided biopsy-fibrocollagen and fibroadipose tissue. Operative Finding was proceeded with modified Makuchi incision, 24 x 18 cm, 1.6 kg mass in right suprarenal / retroperitoneal space (Figure 2). Pushing kidney anteriorly and downward. Right renal vein stretched out. IVC compressed. Grossly adherent to under surface of liver, retroperitonium, upper anterior surface of right kidney. Renal hilum not visualized (Figure 3 and 4). Mass removed in toto (Figure 5). Post-operative period was uneventful and followed up for 1 year without any features of tumor recurrence either clinically or on imaging. Bipsy came out to be adrenal myelolipoma.



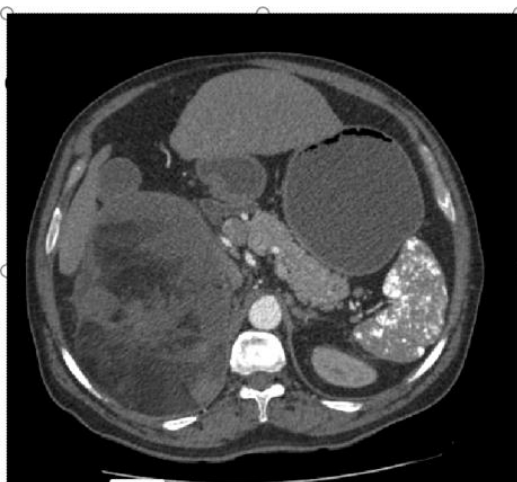**Figure 2: Showing modified Makuchi incision.**



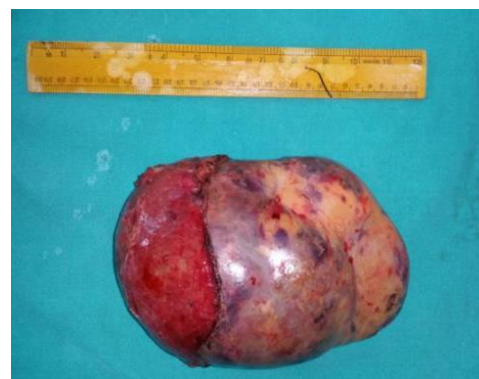**Figure 3: Intra-operative picture of the tumor.**



**Figure 4: Weight of the tumor.**



**Figure 1: CECT abdomen.**



**Figure 5: Tumor after excision in toto.**

## DISCUSSION

Adrenal myelolipoma is a rare benign tumor, containing adipose and hematopoietic tissues. Often confused with its malignant counterpart. Asymptomatic, unilateral right-sided, incidentally detected size often <4 cm giant extremely rare, 10% of reported case.<sup>10</sup> Diagnosis often done based on autopsy or imaging findings for reasons unrelated to adrenal gland diseases hence called as “Incidentalomas”. Most widely accepted theory for development of adrenal myelolipoma adrenocortical cell metaplasia in response to stimuli like infection, inflammation, stress, and necrosis.<sup>11</sup> For diagnosis CECT is more sensitive than MRI or USG.<sup>12</sup> The differential diagnosis should fat-containing retroperitoneal mass including retroperitoneal lipoma, liposarcoma and renal angiomyolipoma.<sup>13</sup> Modified Makuchi incision should be given when the size is more than 10 cm and suspecting severe adhesions to surrounding.<sup>14</sup>

## CONCLUSION

Adrenal myelolipomas clinically silent very rare benign tumor, mostly detected incidentally. A systematic approach with clinical suspicion as per clues from history, presentation and supported by appropriate radiological and biochemical findings can help to reach a pre-operative diagnosis which agrees with post-operative histopathology along with precise surgery.

*Funding: No funding sources*

*Conflict of interest: None declared*

*Ethical approval: Not required*

## REFERENCES

1. Ersoy E, Ozdoğan M, Demirağ A, Aktimur R, Kulaçoğlu H, Kulaçoğlu S, et al. Giant adrenal myelolipoma associated with small bowel leiomyosarcoma: a case report. Turk J Gastroenterol. 2006;17(2):126-9.
2. Daneshmand S, Quek ML. Adrenal myelolipoma: diagnosis and management. J Urology. 2006;1(3):71-4.
3. Al Bahri S, Tariq A, Lowentritt B, Nasrallah DV. Hindawi Publishing Corporation: Giant bilateral adrenal myelolipoma with congenital adrenal hyperplasia. Case Rep Surg. 2014;728198:2014.
4. Ramirez M, Misra S. Adrenal myelolipoma: To operate or not? A case report and review of the literature. Int J Surg Case Rep. 2014;5:494-6.
5. Lam AK. Update on adrenal tumours in 2017 World Health Organization (WHO) of endocrine tumours. Endocr Pathol. 2017;28:213-27.
6. Bokhari MR, Bhimji S. Adrenal, myelolipoma. Stat Pearls. NCBI Bookshelf; 2017.
7. Brogna A, Scalisi G, Ferrara R, Bucceri AM. Giant secreting adrenal myelolipoma in a man: a case report. J Med Case Reports. 2011;5:298.
8. Zhao J, Sun F, Jing X, Zhou W, Huang X, Wang H, et al. The diagnosis and treatment of primary adrenal lipomatous tumours in Chinese patients: A 31-year follow-up study. Can Urol Assoc J. 2014;8:E132-6.
9. Molnar C, Lata L, Pisica R, Russu C, Gherghinescu M, Molnar C, et al. Anterior transabdominal laparoscopic adrenalectomy, without ligatures, for a symptomatic right adrenal myelolipoma with intratumorally haemorrhage. Chirurgia (Bucur). 2017;112:58-62.
10. Porcaro AB, Novella G, Ficarra V, Cavalleri S, Antonioli SZ, Curti P. Incidentally discovered adrenal myelolipoma. Report on 3 operated patients and update of the literature. Archivio Italiano di Urologia, Andrologia. 2002;74(3):146-51.
11. Tyritzis SI, Adamakis I, Migdalis V, Vlachodimitropoulos D, Constantinides CA. Giant adrenal myelolipoma, a rare urological issue with increasing incidence: a case report.” Cases J. 2009;2(9):8863.
12. Kenney PJ, Wagner BJ, Rao P, Heffess CS. Myelolipoma: CT and pathologic features. Radiology. 1998;208(1):87-95.
13. Repassy DL, Csata S, Sterlik G, Iványi A. Giant adrenal myelolipoma. Pathol Oncol Res. 2001;7:72-3.
14. Tsuru K, Ushiyama ST, Ozono S. Laparoscopic adrenalectomy for large adrenal tumors. J Endourol. 2005;19(5):537-40.

**Cite this article as:** Padhy AP, Kanungo A, Das DK, Sunny. Very rare giant adrenal myelolipoma: a tumor mimic. Int Surg J 2020;7:586-8.