

Case Report

Perforated duodenal ulcer after gastric bypass: a challenging diagnosis

Maria J. Amaral^{1,2*}, Marco Serôdio^{1,2}, Emília C. Fraga¹, Cristina P. Camacho^{1,2},
Ana C. Almeida^{1,2}, António Manso^{1,2}, José G. Tralhão^{1,2,3}

¹Department of General Surgery, Centro Hospitalar e Universitário de Coimbra, Coimbra, Portugal

²University of Coimbra, Coimbra, Portugal

³Coimbra Institute for Clinical and Biomedical Research (iCBR) area of Environment Genetics and Oncobiology (CIMAGO), University of Coimbra, Coimbra, Portugal

Received: 07 December 2019

Accepted: 09 January 2020

*Correspondence:

Dr. Maria João Amaral,

E-mail: mariajoaoamaral@hotmail.com

Copyright: © the author(s), publisher and licensee Medip Academy. This is an open-access article distributed under the terms of the Creative Commons Attribution Non-Commercial License, which permits unrestricted non-commercial use, distribution, and reproduction in any medium, provided the original work is properly cited.

ABSTRACT

Roux-en-Y gastric bypass (RYGB) is one of the most commonly performed surgeries for morbid obesity. Perforated duodenal ulcers are very rare in these patients (with a 0.25% incidence reported) and the diagnosis can be challenging. We report a case of a 43-year-old woman who presented with severe acute abdominal pain to the emergency department. She had undergone a laparoscopic RYGB 5 years previously. Exploratory laparoscopy revealed a duodenal perforation, which was repaired by primary closure. As *Helicobacter pylori* has been implicated in the formation of ulcers in this population, eradication therapy should be started.

Keywords: Gastric bypass, Duodenal ulcer, Perforation, Remnant stomach, Laparoscopy

INTRODUCTION

Roux-en-Y gastric bypass (RYGB) is one of the most commonly performed surgical procedures to treat morbid obesity, resulting in the exclusion of a remnant of the stomach, the duodenum and the proximal jejunum.¹ A perforated duodenal ulcer in the excluded duodenum is a very rare occurrence in patients who have undergone RYGB (with a nearly 0.25% incidence reported).² The diagnosis can be challenging as pneumoperitoneum is frequently absent on radiographs because ingested air would preferentially flow through the gastrojejunostomy rather than retrograde into the biliopancreatic limb.³ Furthermore, most of the reported cases correspond to the early days of gastric bypass when proton pump inhibitors (PPI) were not as liberally used.³

We report a case of a patient with a perforated duodenal ulcer who, 5 years previously, had undergone laparoscopic gastric bypass surgery for morbid obesity.

CASE REPORT

A 43-year-old woman presented with severe acute abdominal pain to the emergency department (ED). She denied fever, any other gastrointestinal symptoms and denied taking any nonsteroidal anti-inflammatory agents. Had a past medical history of laparoscopic gastric bypass 5 years previously without any complications, total thyroidectomy and laparoscopic cholecystectomy for cholelithiasis 3 years before. Abdominal examination revealed rebound tenderness and guarding. Chest and abdominal radiographs did not demonstrate free air (Figure 1). An urgent abdominal computed tomography (CT) showed a pneumoperitoneum without revealing its origin. Also, there was a small volume of peritoneal effusion in the pelvic cavity and inter-loops. There were signs of previous surgery (RYGB) with anastomotic permeability, and no gastric dilatation was observed (Figure 2). The laboratory tests were without abnormalities.

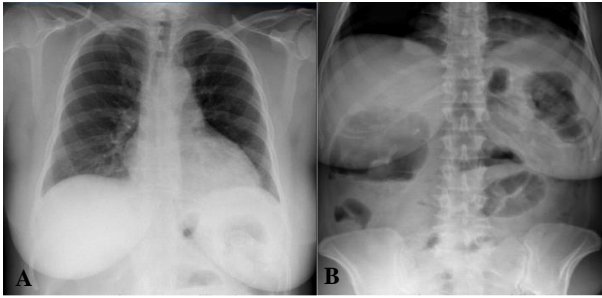


Figure 1: (A) Chest and (B) abdominal radiographs.

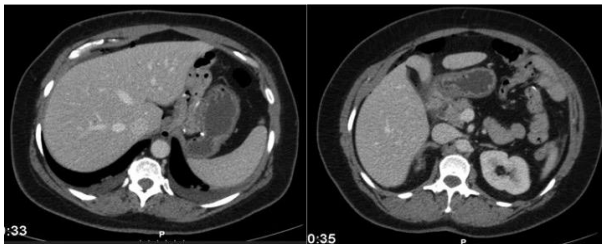


Figure 2: CT images of the patient showed anastomotic permeability without gastric dilatation and a small pneumoperitoneum.

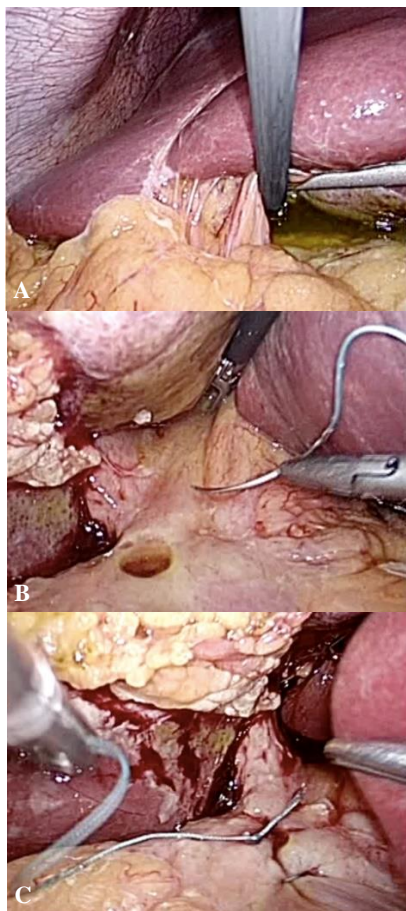


Figure 3: Laparoscopy (A) biliary fluid that helped detect the duodenal perforation, (B) duodenal perforation and (C) suture of the ulcer - two single stitches.

The patient underwent exploratory laparoscopy; biliary effusion was observed and inspection of the duodenum revealed a peptic ulcer perforation. The defect was repaired with nonabsorbable sutures, followed by an omentoplasty and a peritoneal lavage; a closed suction drain was left next to the duodenum (Figure 3).

After surgery, a standardized analgesic regimen was administered for pain relief, PPI were initiated and intravenous piperacillin-tazobactam was administered for 5 days. Feeding was resumed on the first postoperative day and, by the fourth postoperative day, the patient had almost completely recovered and the drain was removed. She was discharged on day 5 without any complications, medicated with long term PPI therapy.

DISCUSSION

As explained before, after a RYGB, a remnant of the stomach is left in situ and this blind-ended gastric remnant may cause complications and surgical emergencies. However, routine removal of the gastric remnant would expose the patients to greater surgical trauma, a prolonged surgical time and, probably, an increased risk for surgical complications and metabolic consequences, such as vitamin B12 deficiency.^{5,6}

In one series, gastroduodenal perforations presented 20 days to 12 years after the gastric bypass² and free air under the diaphragm, the classic radiologic sign of perforation, was not reported in any patients. Most cases were handled by primary closure of the perforation with following definite ulcer therapy in the form of pharmacologic treatment or surgery.⁶ The decision to proceed with a definitive surgical treatment should be based on the particular risks and benefits for each patient.³

Helicobacter pylori has been implicated in the formation of ulcers in this population by weakening the mucosal protective barriers, together with the ingestion of nonsteroidal anti-inflammatory drugs or alcohol consumption.^{3,4} Also, it was suggested that because the distal pouch is deprived of the buffering effect of the ingested food, the acid in the distal stomach and duodenum may not be neutralized, which may be accentuated by a delay in pancreatic secretion of bicarbonate and bile reflux.^{3,4}

As the excluded stomach is challenging to reach, eradication of *H. pylori* is usually addressed prior to RYGB but, in case it is detected after, in the presence of duodenal ulcers, eradication therapy should be started.¹ Stool antigen detection is probably the best noninvasive diagnostic tool, with reasonable high sensitivity and specificity, although histological diagnosis remains the gold standard.⁵ Therefore, biopsies could be done during surgery for perforated ulcers.

In this case, our patient denied doing a digestive endoscopy and *H. pylori* eradication prior to RYGB and she started eradication therapy after the complication.

CONCLUSION

Perforated ulcers in excluded segments after RYGB are very rare and can be hard to diagnose. Even so, this diagnosis must be kept in mind in these patients who have acute abdominal pain and immediate exploratory laparoscopy should be performed despite negative diagnostic procedures. *H. pylori* eradication therapy should be done and resection of the bypassed stomach can be indicated as a definitive treatment for complicated ulcers.

Funding: No funding sources

Conflict of interest: None declared

Ethical approval: Not required

REFERENCES

1. Pohl D, Schmutz G, Plitzko G, Kröll D, Nett P, Borbély Y. Perforated duodenal ulcers after Roux-Y Gastric Bypass. Am J Emerg Med. 2018;36(8):1525.e1-3.
2. MacGregor AMC, Pickens NE, Thoburn EK. Perforated peptic ulcer following gastric bypass for obesity. Am Surg. 1999;65:222-5.
3. Iskandar ME, Chory FM, Goodman ER, Surick BG. Diagnosis and Management of Perforated Duodenal Ulcers following Roux-En-Y Gastric Bypass: A Report of Two Cases and a Review of the Literature. Case Rep Surg. 2015;2015.
4. Mittermair R, Renz O. An Unusual Complication of Gastric Bypass: Perforated Duodenal Ulcer. Obes Surg. 2007;17(5):701-3.
5. Gypen BJ, Hubens GJA, Hartman V, Balliu L, Chapelle TCG, Vaneerdeweg W. Perforated Duodenal Ulcer after Laparoscopic Gastric Bypass. Obes Surg. 2008;18(12):1644-6.
6. Tom M. The Gastric Remnant in Roux-en-Y Gastric Bypass: Challenges and Possibilities. J Clin Gastroenterol. 2016;50(7):527-31.

Cite this article as: Amaral MJ, Serôdio M, Fraga E, Camacho C, Almeida AC, Manso A, et al. Perforated duodenal ulcer after gastric bypass: a challenging diagnosis. Int Surg J 2020;7:573-5.