

Case Report

Hypertrophied reverse palmaris longus muscle: a rare cause of carpal tunnel syndrome

Narayanamurthy Sundaramurthy, Surya Rao Rao Venkata Mahipathy*,
Alagar Raja Durairaj

Department of Plastic and Reconstructive Surgery, Saveetha Medical College and Hospital, Thandalam, Kanchipuram, Tamil Nadu, India

Received: 04 December 2019

Accepted: 08 January 2020

*Correspondence:

Dr. Surya Rao Rao Venkata Mahipathy,

E-mail: surya_3@hotmail.com

Copyright: © the author(s), publisher and licensee Medip Academy. This is an open-access article distributed under the terms of the Creative Commons Attribution Non-Commercial License, which permits unrestricted non-commercial use, distribution, and reproduction in any medium, provided the original work is properly cited.

ABSTRACT

Carpal tunnel syndrome (CTS) is usually secondary to compression or irritation of the median nerve in the fibro-osseous canal formed by the flexor retinaculum (transverse carpal ligament) and the carpal bones. The prevalence of CTS in the general population is about 7 to 19%. Several causes both local and systemic have been described, but CTS due to aberrant musculature are rare. Here we report a case of a middle-aged female with paresthesia of the hand and a positive Phalen's test with nerve conduction study of the median nerve showing sensorimotor neuropathy. The patient underwent surgery for open CTS release where we found a hypertrophied reverse palmaris longus muscle attached to the palmar aponeurosis which was excised along with its proximal tendon. On post-operative follow up all the symptoms of CTS were completely resolved. Muscle abnormalities concern three muscles: the palmaris longus, the flexor digitorum superficialis of index, and the lumbricals. These muscles can be hypertrophied, bifid, duplicated, digastric, inverted or have an abnormal insertion, thus creating a mechanical restriction of the carpal tunnel. Surgical resection of abnormal muscle provides excellent functional recovery.

Keywords: Carpal tunnel syndrome, Rare, Reverse palmaris longus

INTRODUCTION

Carpal tunnel syndrome (CTS) is secondary to compression or irritation of the median nerve in the osteofibrous canal, which is formed by the flexor retinaculum (transverse carpal ligament) and the carpal bones. The median nerve is the most common peripheral nerve entrapment syndrome globally, with an incidence of 99 per 100 000 annually.¹⁻³ The prevalence rate in the general population is between 7 and 19%.⁴ The pathogenesis of CTS is idiopathic in most cases.⁵ Several local and systemic causes have been described, but muscle aberrations have rarely been reported.^{6,7}

CASE REPORT

A 32-year-old female presented to us with pain, tingling, numbness and difficulty in moving the left hand and wrist for about 3 years duration. These symptoms aggravated at night and while doing activities like washing clothes and cooking. There was no history of trauma or surgery done for the left upper limb in the past. There were no similar complaints on the right side. There was no history of recent pregnancy, thyroid disease, diabetes mellitus or rheumatoid arthritis. On examination, the left upper limb appeared normal but she had paresthesia in the median nerve distribution area with a positive Phalen's and reverse Phalen's test. A clinical diagnosis of carpal tunnel

syndrome was made. We planned for an open carpal tunnel release. Under supraclavicular block and tourniquet control, parts were painted and draped. A lazy S shaped incision was made parallel and ulnar to the thenar crease distally to the volar wrist crease proximally (Figure 1).

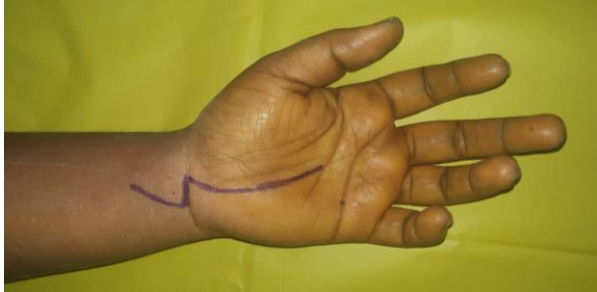

Figure 1: Marking of incision for open carpal tunnel release.

Incision was deepened in layers incising the palmar aponeurosis to expose the transverse carpal ligament which was divided. At this point, we noticed an abnormal muscle which was inserted into the palmar aponeurosis (Figure 2).

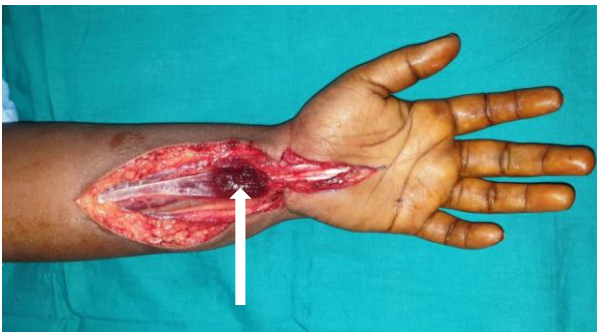


Figure 2: Intra-operative picture of hypertrophied reverse palmaris longus muscle (white arrow).

On proximal extension of the incision, the hypertrophied muscle became tendinous, and hence a diagnosis of reverse palmaris longus was made (Figure 3).

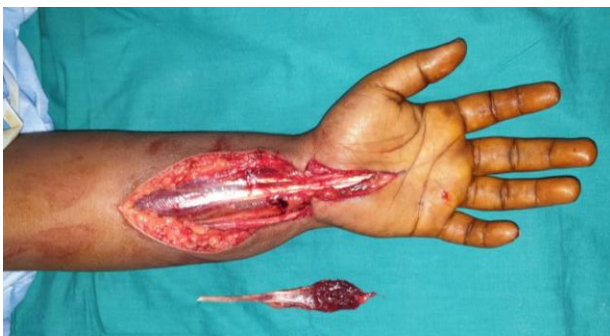

Figure 3: Intra-operative photograph after excising the hypertrophied reverse palmaris longus muscle with its proximal tendon.

On reviewing the literature, a rare cause of carpal tunnel syndrome was reverse palmaris longus. The muscle with its tendon was excised and haemostasis was secured. The incision was closed in layers with 3-0 polyglactin and 3-0 nylon sutures and compression dressing were applied (Figure 4).

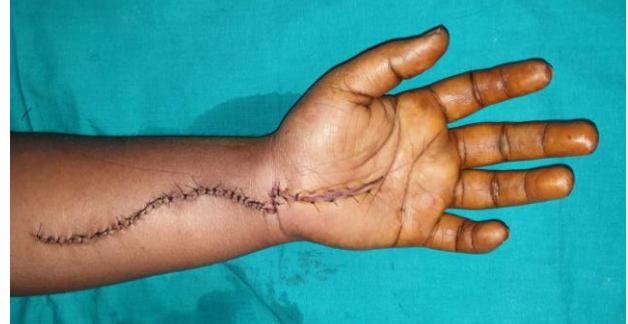

Figure 4: Immediate post-operative photograph.

It was changed to a loose dressing the next day with a splint. The paresthesia improved tremendously in the immediate post-operative period. Sutures were removed on the 10th post-operative day and started on physiotherapy.

DISCUSSION

In most cases of CTS, no cause is identified. In some cases, local or systemic issues as diabetes, hypothyroidism, alcohol consumption, and pregnancy have been reported as etiologies of CTS.^{2,3,8,9} Local causes like wrist fractures or soft tissue tumors have also been reported.^{10,11} Muscular abnormalities are found mainly in manual workers. Those abnormalities concern three muscles: the palmaris longus, the flexor digitorum superficialis of index, and the lumbricals.¹²⁻¹⁵ These muscles can be hypertrophied, bifid, duplicated, digastric, inverted or have an abnormal insertion, thus creating a mechanical restriction of the carpal tunnel. The literature reports only isolated cases of such abnormalities. In a study by Weissenborn et al, muscle abnormalities accounted for 0.8% of a total of 856 CTS patients in their study.¹⁶ Imaging modalities like ultrasonography, or magnetic resonance imaging, may reveal the diagnosis, but most of the time, it is an intra operative finding that is discovered in most patients, as also in our patient.^{17,18}

The palmaris longus (PL) is a fusiform muscle of the superficial flexor compartment of the forearm. It originates together with other superficial forearm flexors from the medial epicondyle and is covered by the anterobrachial fascia.¹⁹⁻²² The short belly transforms into a long, thin tendon which lies medial to the flexor carpi radialis. It passes above the flexor retinaculum and continues with the palmar aponeurosis. The PL is characterized by high-morphological variability including presence of an accessory muscle belly, occurrence of the reversed muscle, fusion with other muscles, the presence

of an atypical tendon course, and inserts or bifurcated/multiple tendinous insertions.^{19,24-30}

Variations in morphology of palmaris longus

The PL was present in 100 of 160 upper limbs (62.5%). The study recognized nine types of the PL muscle, based on variations in its form and insertion (Types I–IX). All types originated on the medial epicondyle of the humerus. Type I originated as a muscle belly on the medial humeral epicondyle. The muscular part turned into the tendon and inserted into the palmar aponeurosis. This type was found in 52 upper limbs (52%) (Figure 5a). Type II differed from Type I by the bifurcation of the distal tendon. Two components differed in size so that the ‘palmar division’ always predominated and inserted into

the palmar aponeurosis while the ‘second division’ was auxiliary and inserted into the flexor retinaculum of the wrist. This type was observed in 22 limbs (22%) (Figure 5b). Type III demonstrated a proximal attachment with the same morphology as Type I and II. The tendon was bifurcated; the ‘palmar division’ of the tendon always predominated and inserted into the palmar aponeurosis, while the ‘second division’ fused with the abductor pollicis brevis. This type was found in 10 cases (10%) (Figure 5c). Type IV originated with a long, thin tendon from the medial epicondyle of the humerus, then the tendon gradually extended into an elongated muscle belly; slightly above the level of the interstyloid line, the muscle belly became a tendon once again, inserting into the palmar aponeurosis. This type was observed in six limbs (6%) (Figure 5d).

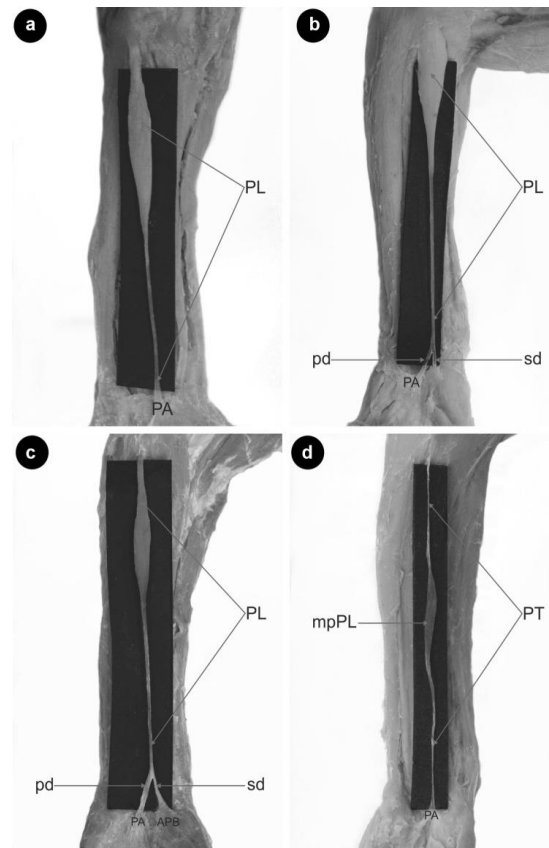


Figure 5: Type of palmaris longus muscle (a) type I palmaris longus muscle, PL palmaris longus muscle, PA palmar aponeurosis, (b) type II palmaris longus muscle PL palmaris longus muscle, PA palmar aponeurosis, PD palmar division, SD second division, (c) type III palmaris longus muscle, PL palmaris longus muscle, PA palmar division, APB abductor pollicis brevis, PD palmar division, SD second division, (d) type IV palmaris longus muscle, PT palmaris tendon, mpPL muscular part palmaris longus muscle, PA palmar aponeurosis.

Type V demonstrated the same morphology as type IV; however, the distal tendon was bifurcated: the ‘palmar division’ predominated and inserted into the palmar aponeurosis, while the ‘second division’ was auxiliary and inserted into the flexor retinaculum of the wrist. This type occurred in three limbs (3%) (Figure 6a). Type VI—this type was reversed—with the proximal portion being tendinous and distal portion being muscular. It was found in two limbs (2%) (Figure 6b). Type VII—characterized

by a partial doubling of the muscle belly, which then turned into two separate tendons (ulnar and radial). The two tendons connect and inserted together into the palmar aponeurosis. This type was observed in one limb (1%) (Figure 6c). Type VIII—demonstrated a proximal attachment with the same morphology as Type I, II and III. The tendon was divided into three parts: the ‘palmar division’ of the tendon inserted into the palmar aponeurosis, the ‘second division’ inserted into the

abductor pollicis brevis, and the ‘third division’ was auxiliary and inserted into the opponens pollicis muscle. This type was found in three limbs (3%) (Figure 6d). Type IX—the palmaris longus in the distal part passed above the palmar aponeurosis was connected as a

‘communication tendon and fused with the flexor carpi ulnaris muscle. This type was observed in one limb (1%) (Figure 6e). Our patient had a type VI morphology of palmaris longus.

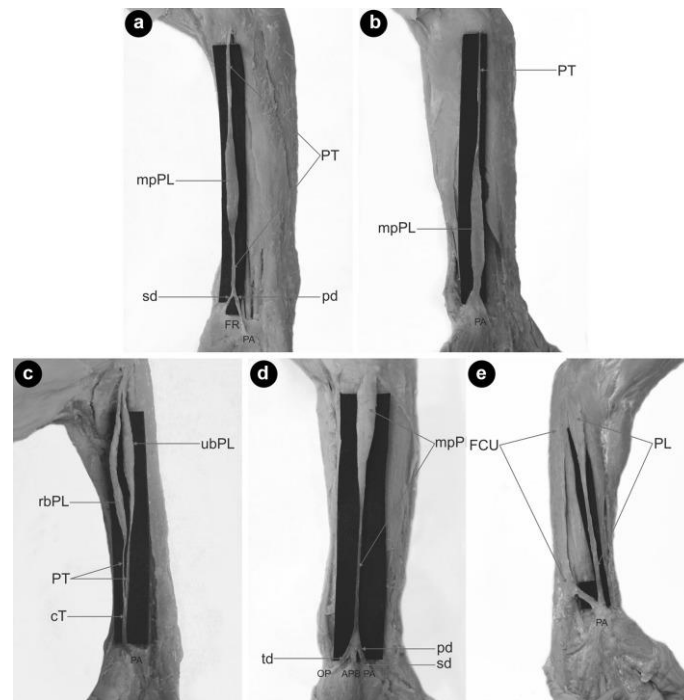


Figure 6: Type of palmaris longus muscle, (a) type V palmaris longus muscle, PT palmaris tendon, mpPL muscular part palmaris longus muscle, PA palmar aponeurosis, FR flexor retinaculum, PD palmar division, SD second division, (b) type VI (reversed) palmaris longus muscle. PT palmaris tendon, mpPL muscular part palmaris tendon, PA palmar aponeurosis, (c) type VII palmaris longus muscle, PT palmaris tendon, mpPL muscular part palmaris longus muscle, CT communication tendon, PA palmar aponeurosis, (d) type VIII palmaris longus muscle, mpPL muscular part palmaris longus muscle, PA palmar aponeurosis, ABP abductor pollicis brevis, OP opponens pollicis muscle, pd palmar division, SD second division, td third division. (e) type IX palmaris longus muscle, PL palmaris longus muscle, FCU flexor carpi ulnaris, PA palmar aponeurosis × communication tendon between the palmaris tendon and flexor carpi ulnaris.

CONCLUSION

It is imperative that all suspected cases of CTS should undergo a thorough clinical examination aided by nerve conduction study and supplemented by appropriate imaging particularly an MRI. Complete surgical resection of abnormal muscle provides excellent functional recovery in all patients.

Funding: No funding sources

Conflict of interest: None declared

Ethical approval: Not required

REFERENCES

1. Padua L, Coraci D, Erra C, Pazzaglia C, Paolasso I, Loreti C, et al. Carpal tunnel syndrome: clinical features, diagnosis, and management. *Lancet Neurol.* 2016;15(12):1273-84.
2. von Schroeder HP, Botte MJ. Carpal tunnel syndrome. *Hand Clin.* 1996;12(4):643-55.
3. Newington L, Ferry S, Pritchard T, Keenan J, Croft P, Silman AJ. Estimating the prevalence of delayed median nerve conduction in the general population. *Br J Rheumatol.* 1998;37(6):630-5.
4. Michelsen H, Posner MA. Medical history of carpal tunnel syndrome. *Hand Clin.* 2002;18(2):257-68.
5. Palmer KT. Carpal tunnel syndrome: the role of occupational factors. *Best Pract Res Clin Rheumatol.* 2011 ;25(1):15-29.
6. Samson P. Le syndrome du canal carpien. *Chir Main.* déc 2004;23(Suppl 1):S165- 77.
7. Lozano-Calderón S, Anthony S, Ring D. The quality and strength of evidence for etiology: example of carpal tunnel syndrome. *J Hand Surg.* 2008;33(4):525-38.
8. Giersiepen K, Spallek M. Carpal tunnel syndrome as an occupational disease. *Dtsch Arzteblatt Int.* 2011;108(14):238-42.
9. Niver GE, Ilyas AM. Carpal tunnel syndrome after distal radius fracture. *Orthop Clin North Am.* 2012;43(4):521-7.

10. Suginaka H, Hara A, Kudo T. An unusual case of common digital nerve compression caused by a lipoma arising from the flexor tenosynovium. *Hand Surg.* 2013;18(03):435-7.
11. Saraf SK, Tuli SM. Anomalous m. palmaris longus producing carpal tunnel-like syndrome. *Arch Orthop Trauma Surg.* 1991;110(3):173-4.
12. Depuydt KH, Schuurman AH, Kon M. Reversed palmaris longus muscle causing effort-related median nerve compression. *J Hand Surg Edinb Scotl.* 1998;23(1):117-9.
13. Smith RJ. Anomalous muscle belly of the flexor digitorum superficialis causing carpal-tunnel syndrome. Report of a case. *J Bone Joint Surg Am.* 1971;53(6):1215-6.
14. Eriksen J. A case of carpal tunnel syndrome on the basis of an abnormally long lumbrical muscle. *Acta Orthop Scand.* 1973;44(3):275-7.
15. Weissenborn W, Sabri W. Muscle anomalies as a cause of carpal tunnel syndrome. *Handchir Mikrochir Plast Chir.* 1987;19(3):153-5.
16. Pardal-Fernandez JM. Carpal tunnel syndrome. The contribution of ultrasonography. *Rev Neurol.* 2014;59(10):459-69.
17. Zeiss J, Jakab E. MR demonstration of an anomalous muscle in a patient with coexistent carpal and ulnar tunnel syndrome. Case report and literature summary. *Clin Imaging.* 1995;19(2):102-5.
18. Barkáts N. Hypertrophy of palmaris longus muscle, a rare anatomic aberration. *Folia Morphol.* 2015;74:262-4.
19. Ioannis D, Anastasios K, Konstantinos N, Lazaros K, Georgios N. Palmaris longus muscle's prevalence in different nations and interesting anatomical variations: review of the literature. *J Clin Med Res.* 2015;7:825-30.
20. Mathew AJ, Sukumaran TT, Joseph S. Versatile but temperamental: a morphological study of palmaris longus in the cadaver. *J Clin Diagn Res JCDR.* 2015;9:AC01-A3.
21. Olewnik Ł, Wysiadecki G, Polguj M, Podgórski M, Jezierski H, Topol M. Anatomical variations of the palmaris longus muscle including its relation to the median nerve—a proposal for a new classification. *BMC Musculoskelet Disord.* 2017;18:539.
22. Bergman RA, Afifi AK, Miyauchi R. *Illustrated Encyclopedia of Human Anatomic Variation: Opus I: Muscular System: Alphabetical Listing of Muscles;* 2015.
23. Albay SA, Astamoni YAK, Akalli BÜŞRAS, Unali ST. Anatomy and variations of palmaris longus in fetuses. *Rom J Morphol Embryol.* 2013;54:85-9.
24. Bernardes A, Melo C, Pinheiro S. A combined variation of Palmaris longus and Flexor digitorum superficialis: case report and review of literature. *Morphologie.* 2016;100:245-9.
25. Iqbal S, Iqbal R, Iqbal F. A bitendinous palmaris longus: aberrant insertions and its clinical impact—a case report. *J Clin Diagn Res.* 2015;9:AD03-A5.
26. Kumar N, Patil J, Swamy RS, Shetty SD, Abhinitha P, Rao MK, et al. Presence of multiple tendinous insertions of palmaris longus: a unique variation of a retrogressive muscle. *Ethiop J Health Sci.* 2014;24:175-8.
27. Marpalli S, Bhat ALS, Gadahad MRK. A case of reverse palmaris longus muscle—an additional muscle in the anterior compartment of the forearm. *J Clin Diagn Res.* 2016;10:AD03-A4.
28. Murabit A, Gnarra M, Mohamed A. Reversed palmaris longus muscle: anatomical variant—case report and literature review. *Can J Plast Surg.* 2013;21:55-6.
29. Sarkar M, Mukherjee P, Roy H, Sengupta SK, Sarkar AN. An unusual branch of celiac trunk feeding suprarenal gland—a case report. *J Clin Diagn Res.* 2014;8:AD03-4.

Cite this article as: Sundaramurthy N, Surya Rao, RVK, Durairaj AR. Hypertrophied reverse palmaris longus muscle: a rare cause of carpal tunnel syndrome *Int Surg J* 2020;7:576-80