

## Case Report

# Primary retroperitoneum mucinous cystadenoma

P. K. Bhatia, Kirti Savyasacchi Goyal\*, Himanshu Tanwar, Parkash Biswas

Department of General Surgery, M. M. I. M. S. R., Mullana, Ambala, Haryana, India

**Received:** 01 December 2019

**Revised:** 06 January 2020

**Accepted:** 07 January 2020

**\*Correspondence:**

Dr. Kirti Savyasacchi Goyal,

E-mail: [kirtisgoyal@gmail.com](mailto:kirtisgoyal@gmail.com)

**Copyright:** © the author(s), publisher and licensee Medip Academy. This is an open-access article distributed under the terms of the Creative Commons Attribution Non-Commercial License, which permits unrestricted non-commercial use, distribution, and reproduction in any medium, provided the original work is properly cited.

### ABSTRACT

Primary retroperitoneal mucinous cystadenomas are observed more frequently in women with no specific symptoms. A 35 Years old female patient presented with Intermittent abdominal pain in her left flank associated with fullness in abdomen. CECT confirmed a well-defined smoothly marginated homogenous non-enhancing unilocular cystic lesion in retroperitoneum in left lumbar region, separated from the pancreas, left kidney and ovary. On Laprotomy, the retroperitoneal tumor was completely removed, without spillage of its contents.

**Keywords:** Neoplasm, Primary cystadenomas, Retroperitoneum

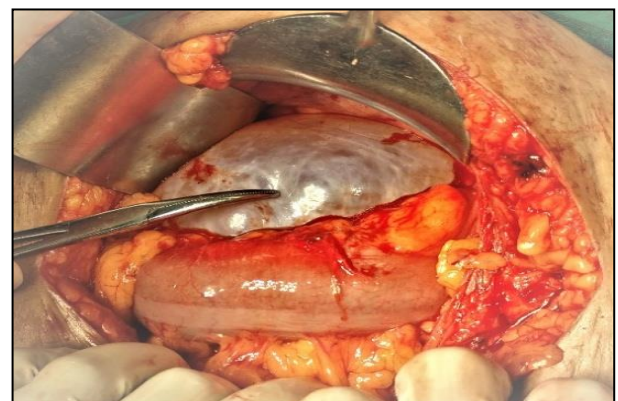### INTRODUCTION

Primary retroperitoneal mucinous cystadenomas (PRMCs) are observed more frequently in women with no specific symptoms unless they are large enough to create pressure to have an obstructive effect on adjacent organ. An accurate preoperative diagnosis in these cases is difficult because no effective methods have been established. Once diagnosed, complete excision is recommended because of the risk of infection or malignant degeneration, even though it behaves in a benign fashion with no recurrences in most of the cases.<sup>1</sup> The present report is of one case of a primary benign retroperitoneal mucinous cystadenoma.

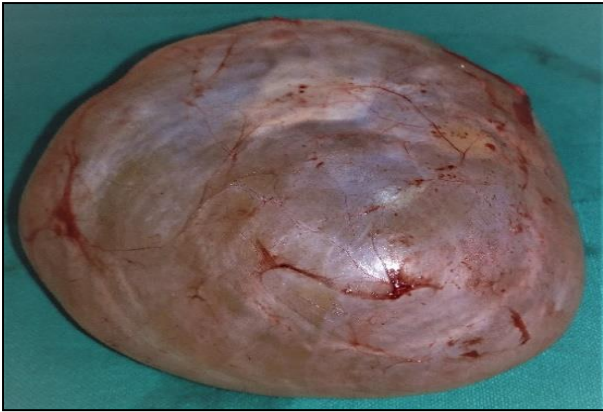### CASE REPORT

Among 35 years old female patient presented with Intermittent abdominal pain in her left flank associated with fullness in abdomen. Examination revealed a painless, palpable mass in the left lower quadrant of the abdomen. Patients general condition was fair and vitals. The laboratory data were within reference ranges and tumor markers including CA 19-9, CA 125 and CEA were normal. CT abdomen confirmed a well-defined

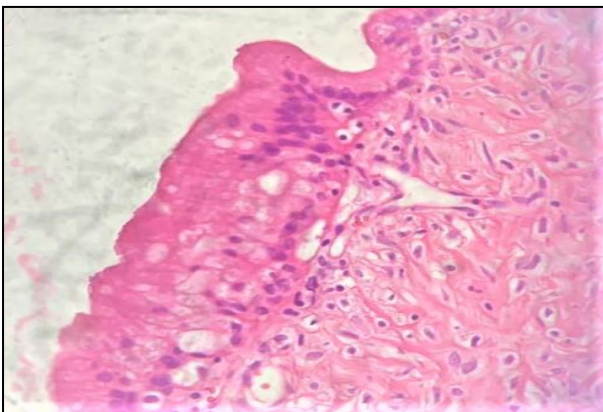
smoothly marginated homogenous non-enhancing unilocular cystic lesion with attenuation of 4-5 HU in retroperitoneum in left lumbar region displacing the descending colon anteriorly, measuring approximately 7.8×6.7×12.6 cm with attenuation of 20-25 HU (Figure 4). No septations seen within. No solid component seen. No mural nodularity is seen. It is separated from the pancreas, left kidney and ovary.



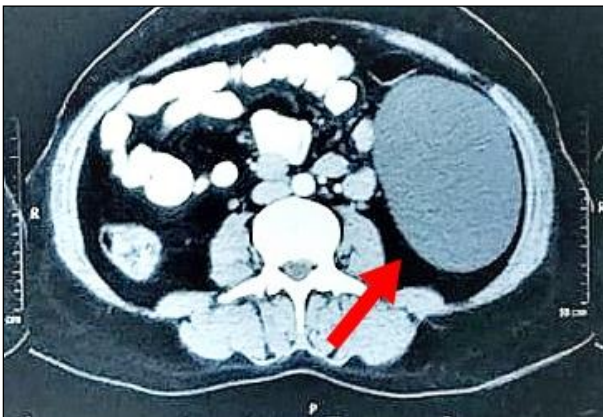**Figure 1: Retroperitoneal cyst displacing descending colon anteriorly.**



**Figure 2: Resected specimen.**



**Figure 3: Mucinous cystadenoma on H&E stain.**



**Figure 4: CECT abdomen (transverse section) showing non enhancing unilocular cystic lesion.**

On laprotomy, the cyst was found to be located behind the posterior peritoneum of the descending colon. The white line of Toldt was divided to expose the cystic mass (Figure 1). It had not invaded any adjacent organs. The retroperitoneal tumor was completely removed, without spillage of its contents. A huge retroperitoneal cyst measuring 9×8×8 cm grey-white in color having vascularised walls and containing clear mucinous fluid was excised (Figure 2). Histopathological assessment

revealed a unilocular cyst lined by tall columnar lining epithelium with mucinous differentiation and fibro-collagenous wall with sprinkling of lymphocytes, no features of malignancy reported (Figure 3). The postoperative course was uneventful, and the patient was discharged 5 days after surgery without any complications.

## DISCUSSION

Retroperitoneal tumors account for less than 0.2% of all neoplasms.

Although they share a histological similarity to ovarian mucinous cystadenomas, they can arise at any location in the retroperitoneum without ovarian attachment.<sup>2</sup> It is important to remember that cystic fluid spillage has to be prevented due to the uncertain pathology of the tumor in most of the cases.

The first description of a PRMC was undertaken by Handfield-Jones in 1924 in his study on retroperitoneal cysts.<sup>3</sup> As there are no epithelial cells in the retroperitoneum, the occurrence of this tumor type is extremely rare. To the best of our knowledge, this is the 42nd report of a PRMC in the literature worldwide.<sup>5</sup> Two theories have been proposed to explain the histogenesis. The first theory is that they are thought to arise from heterotopic ovarian tissue due to its resemblance to ovarian mucinous cystadenomas and second theory is that these tumors arise from an invagination of multipotential mesothelium with subsequent mucinous metaplasia of the cells, giving rise to a mucinous tumor that enlarges to form a cyst.<sup>2,4</sup> Based on a review of the cases reported in the literature, these tumors can be classified in three types. The most common type is the retroperitoneal mucinous cystadenoma. A large, unilocular or multilocular benign cystic tumor not associated with recurrence after resection. This was the type that our patient presented. Second type resembles the ovarian mucinous cystadenomas of low malignant potential third type is the mucinous cystadenocarcinoma.

## CONCLUSION

The complete surgical excision of the PRMCs is always recommended to eliminate the risk of infection, recurrence and malignant degeneration. An exploratory laparotomy with complete enucleation is the traditional treatment, although the laparoscopic excision has been reported.

*Funding: No funding sources*

*Conflict of interest: None declared*

*Ethical approval: Not required*

## REFERENCES

1. Agha RA, Fowler AJ, Saetta A, Barai I, Rajmohan S, Orgill DP. The SCARE Group the SCARE

- statement: consensus-based surgical case report guidelines. *Int J Surg.* 2016;34:180-6.
2. Subramony C, Habibpour S, Hashimoto LA. Retroperitoneal mucinous cystadenoma. *Arch. Pathol Lab Med.* 2001;125(5):691-4.
  3. Handfield-Jones RM. Retroperitoneal cysts: their pathology, diagnosis, and treatment. *Br J Surg.* 1924;12:119-34.
  4. Lee SY, Han WC. Primary retroperitoneal mucinous cystadenoma. *Ann Coloproctol.* 2016;32(1):33-7.
  5. Pesapane F, Van Renterghem S, Patella F, De Visschere P. A case report and a literature review of primary retroperitoneal mucinous cystadenoma: the importance of imaging in diagnosis and management: case report. *Future Oncol.* 2018;14(28):2923-31.

**Cite this article as:** Bhatia PK, Goyal KS, Tanwar H, Biswas P. Primary retroperitoneum mucinous cystadenoma. *Int Surg J* 2020;7:554-6.