

## Original Research Article

# Evaluation the role of laparoscopic management of complicated appendicitis

Samir H. Mahmoud\*, Mahmoud T. Ayoub, Mohamed B. Kotb, Mostafa Abdelghafor

Department of General Surgery, Assuit University Hospital, Assuit, Egypt

**Received:** 22 November 2019

**Revised:** 10 January 2020

**Accepted:** 30 January 2020

### \*Correspondence:

Dr. Samir H. Mahmoud,

E-mail: semochelsea20@yahoo.com

**Copyright:** © the author(s), publisher and licensee Medip Academy. This is an open-access article distributed under the terms of the Creative Commons Attribution Non-Commercial License, which permits unrestricted non-commercial use, distribution, and reproduction in any medium, provided the original work is properly cited.

### ABSTRACT

**Background:** A laparoscopic appendectomy (LA) was performed mostly on uncomplicated appendicitis due to opinions about its safety when it was first introduced. Nevertheless, there are still concerns about surgical difficulties in managing complicated appendicitis with laparoscopy, possible post-op complications and conversion to an open appendectomy (OA) during the surgery.

**Methods:** The study consists of 30 patients who underwent laparoscopic appendectomy in department of General Surgery at Assiut University hospitals. The study population was enrolled after fulfilling the selection criteria from department of General Surgery. Informed consent was taken from all the patients who are involved in this study. Patients diagnosis was based on clinical findings, complete blood counts, and abdominal sonography.

**Results:** Thirty patients underwent laparoscopic appendectomy for complicated appendicitis. Of the 30 patients, perforated appendix cases are 27, gangrenous appendix are 1, appendicular abscess only one case. Post operation wound infection, conversion rate and hospital stay rate very less.

**Conclusions:** The present study proved that laparoscopic appendectomy is the best approach in complicated appendicitis.

**Keywords:** Appendicitis, Complicated appendicitis, Laparoscopic appendectomy, Open appendectomy

### INTRODUCTION

Appendicitis is the commonest abdominal surgical emergency in the world which may lead to complications like appendicular abscess or mass, gangrene, perforation and peritonitis.<sup>1</sup> approximately 7% of the population developed appendicitis in their life time, with peak incidence between the ages of 10 and 30 years, thus making appendectomy the most frequently performed abdominal operation. Open appendectomy has been a safe and effective operation for acute appendicitis for more than a century. In 1981, Semm, a German gynecologist performed the first laparoscopic appendectomy.<sup>2</sup> Despite its use even before laparoscopic cholecystectomy, LA has not yet emerged as gold

standard appendectomy. LA has potential advantages of shorter hospital stay, early mobilization, early return of bowel function, acceptable complication rate along with the recent enthusiasm of minimally invasive surgery. Perforated appendicitis occurs in 20% to 30% of acute appendicitis patients and is associated with much higher risks of postoperative infectious complications such as wound infection and intra-abdominal abscess.<sup>3,4</sup> This study aimed to evaluate the safety and the efficacy of laparoscopy for managing complicated appendicitis.

### METHODS

Study design was prospective descriptive trial. Study place was Assuit University Hospital.

Period of study was since September 2017 to September 2019.

This prospective study is including patients of complicated appendicitis undergoing laparoscopic management. Investigations will be done for all the patients and they include CBC, prothrombin time and concentration and renal functions tests and abdominal ultrasonography (Abd U/S).

**Inclusion criteria**

Male or female patients with acute perforated appendicitis, patients who are fit for laparoscopy and general anesthesia, patients who provide a written informed consent and patient who agree to provide short term outcome data and agree to provide contact information were included.

**Exclusion criteria**

Patients with severe comorbid conditions with high risk for general anaesthesia, appendicular mass, patients suffering from an ongoing infection including chest infections and children and pregnant females were excluded.

**Surgical technique**

Camera was introduced through the 12 mm periumbilical port. This port was placed using a Hassan technique or direct cut down method. A diagnostic laparoscopy was performed. A 5 mm port is introduced in the right lower quadrant under vision.<sup>5</sup> A non-traumatic grasper was introduced through this port to identify the appendix. At this point the small intestine is lifted out of the pelvis exposing the inflamed appendix. Careful manipulation was essential without directly grasping it to avoid bowel injury.<sup>6,7</sup> A 10 mm port was introduced in a suprapubic site. Peritoneal toilet and aspiration of pus after abdominal exposure. A Maryland grasper was introduced, and a window is created in the mesentery to isolate the appendicular artery. Three clips are applied to the isolated vessel. The vessel was divided between clips leaving two clips on the patient side. Authors then use diathermy to divide the rest of the mesentery. The appendix was then ligated and divided at its base with End loops or transected by stapler. At this point authors assess the appendix stump and divided vessel to ensure hemostasis. Retrieval of the appendix in an Endobag.<sup>8,9</sup>

**Ethical approval**

This study was ethically approved by medical ethics committee, faculty of medicine, Assuit University (IRB no: 17100304).

**Statistical analysis**

Data analyzed included descriptive statistics, frequencies, percentages, the mean and standard deviation using SPSS.

**RESULTS**

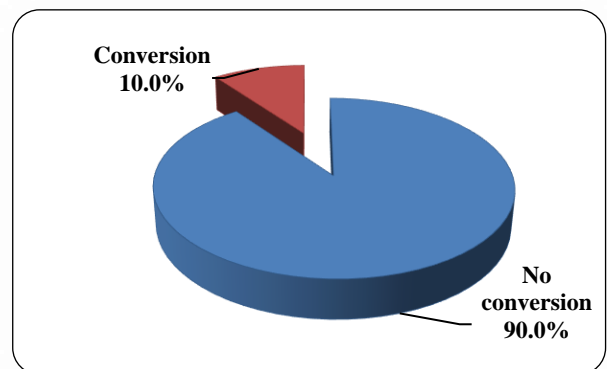
The study included 30 patients of adult male and female. Mean age of the studied patients was 31.77±13.07 years with range between 18 and 65 years. Out of 30 patients, 24 (80%) patients were females and 6 (20%) patients were males. It was noticed that there was increase of total leucocytic count (leukocytosis) in most of the patient, it was found that the mean WBCs was 12.99±4.26 with range between 6-21.9 (Table 1).

**Table 1: Operative results according to the procedure performed.**

Parameter	Result
Age (years)	31.77±13.07
Male/female	20%/80%
WBC	12.99±4.26
Conversion rate	10%
Hospital stay	2.00±0.59
Wound infection	3.3%

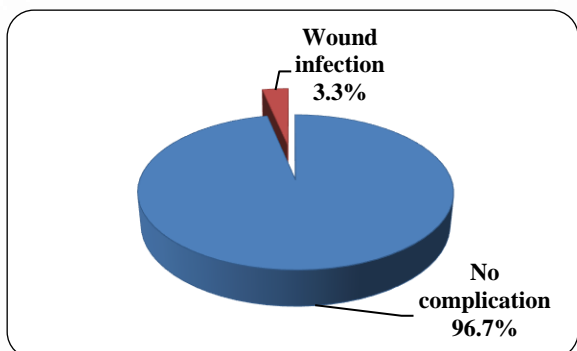
All 30 patients underwent diagnostic laparoscopy at first and intraoperative finding were as following. 20 patients (66.7%) had pus free IPF collection and perforated appendicitis (PA), 7 patients (23.3%) had turbid free IPF collection with AA (highly inflamed appendix), one case was mucocele of the appendix (3.3%), one case of appendicular abscess (3.3%) one case of gangrenous appendix (3.3%).

According to conversion to open surgery only three cases (10%) were converted to open surgery these cases were appendicular abscess, gangrenous appendix and mucocele of the appendix. 27 cases (90%) were successfully preceded to laparoscopic appendectomy.



**Figure 1: Conversion to open surgery.**

Post-operative follow up of 30 patients revealed only one case (3.3%) of postoperative complication in form of wound infection (which was the case of appendicular abscess) while the other 29 case (96.7%) hadn't any post-operative complication.



**Figure 2: Post-operative complication.**

Post-operative hospital stay of all patients were measured and revealed that 4 cases about 13.3% of the cases were stayed one day at the hospital while 23 case about 76.7% of the cases were discharged within two days from the admission and 3 cases about 10 % of the cases were stared three to four days at the hospital these cases which had prolonged hospital stay were the cases which converted to open surgery (appendicular abscess, gangrenous appendix and mucocele of the appendix). Mean±SD (range) of post-operative hospital stay was 2.00±0.59 (1.0-4.0) days (Table 2).

**Table 2: Duration of hospital stay (n=30).**

Hospital stay (days)	No.	%
1	4	13.3
2	23	76.7
3-4	3	10.0
Mean±SD (range)	2.00±0.59 (1.0-4.0)	

**DISCUSSION**

Thirty patients underwent laparoscopic appendectomy for complicated appendicitis. Out of 30 cases 27 patients were presented with perforated appendix (90%), one case was mucocele of the appendix (3.3%), one case of appendicular abscess (3.3%) and one case of gangrenous appendix (3.3%). there was only one case (3.3%) of postoperative complication in form of wound infection (Figure 1).

Only three cases (10%) were converted to open surgery these cases were appendicular abscess, gangrenous appendix and mucocele of the appendix Figure 2. Piskun et al, data on 52 patients with perforated appendicitis 10 (19%) had converted appendectomies.<sup>10</sup> According to So et al, there were 85 patients diagnosed with perforated appendicitis in this study underwent laparoscopy 40

patients (47%) underwent conversion to the open procedure after laparoscopy.<sup>11</sup>

These results for laparoscopic appendectomy confirm the significantly lower rate of wound healing complications only one case (3.3%). According to Lin et al, patients (15.2%) developed wound infections, three patients (3.0%) developed intra-abdominal abscess, and one patient (1%) developed intra-abdominal bleeding.<sup>12,15</sup> In Katsuno et al Wound infection was found in 6.4% of patients in the LA.<sup>13</sup> In Ansari et al, out of 103 patients who were successfully operated laparoscopically, 21 patients developed minor complications like fever in 11 (10.67%) patients, 5 (4.85%) patients had postoperative ileus that delayed their start of oral intake and 5 (4.85%) patients had port site infection. There were no cases of postoperative bowel obstruction and no mortality.<sup>14</sup>

These data show a significant reduction in post-operative hospital stay and conversion rate after LA for complicated appendicitis 2.00±0.59 days. Piskun et al hospital stays of patient underwent Laparoscopic appendectomy was 9.2±4.1 (days).<sup>10</sup> Yagmurlu et al founded length of hospital stay (h) 189±15 (7.8 days).<sup>12</sup> founded in patient underwent laparoscopic appendectomy that the hospital stay was 6.3±2.9 (days).<sup>15</sup>

**CONCLUSION**

This study has demonstrated that laparoscopic appendectomy is a safe approach for complicated appendicitis. It resulted in shorter hospital stay and lower conversion rate. It reduces the risk of postoperative infections.

*Funding: No funding sources*

*Conflict of interest: None declared*

*Ethical approval: The study was approved by the Institutional Ethics Committee of Assuit University*

**REFERENCES**

1. D'Agostino J. Common abdominal emergencies in children. *Emerg Med Clin.* 2002;20(1):139-53.
2. Barkhausen S1, Wullstein C, Gross E. Laproscopic versus conventional appendectomy - a comparison with reference to early postoperative complication. *Zentralbl Chir.* 1998;123:858-62.
3. Andersson RE, Hugander A, Thulin AJ. Diagnostic accuracy and perforation rate in appendicitis: association with age and sex of the patient and with appendicectomy rate. *Eur J Surg.* 1992;158(1):37-41.
4. Krukowski ZH, Irwin ST, Denholm S, Matheson NA. Preventing wound infection after appendicectomy: a review. *British journal of surgery.* 1988;75(10):1023-33.
5. Frazee RC, Roberts JW, Symmonds RE, Snyder SK, Hendricks JC, Smith RW, Custer 3rd MD, Harrison JB. A prospective randomized trial comparing open

- versus laparoscopic appendectomy. *Ann Surg.* 1994;219(6):725.
6. Guller U, Hervey S, Purves H, Muhlbaier LH, Peterson ED, Eubanks S, et al. Laparoscopic versus open appendectomy: outcomes comparison based on a large administrative database. *Ann Surg.* 2004;239(1):43.
  7. Ortega AE, Hunter JG, Peters JH, Swanstrom LL, Schirmer B, Laparoscopic Appendectomy Study Group. A prospective, randomized comparison of laparoscopic appendectomy with open appendectomy. *Am J Surg.* 1995;169(2):208-13.
  8. Hellberg A, Rudberg C, Kullman E, Enochsson L, Fenyő G, Graffner H, et al. Prospective randomized multicentre study of laparoscopic versus open appendectomy. *Bri J Surg.* 1999;86(1):48-53.
  9. Park JB, Sul JY. Laparoscopic appendectomy: a safe primary procedure for complicated appendicitis. *J Korean Surg Soc.* 2007;72(1):51.
  10. Piskun G, Kozik D, Rajpal S, Shaftan G, Fogler R. Comparison of laparoscopic, open, and converted appendectomy for perforated appendicitis. *Surg Endosc.* 2001;15(7):660-2.
  11. So JB, Chiong EC, Chiong E, Cheah WK, Lomanto D, Goh P, et al. Laparoscopic appendectomy for perforated appendicitis. *World J Surg.* 2002;26(12):1485-8.
  12. Heng-Fu Lin, Jiann-Ming Wu, Li-Ming Tseng, Kuo-Hsin Chen; Shih-Horng Huang; I-Rue Lai. Laparoscopic versus open appendectomy for perforated appendicitis. *J Gastrointestinal Surg.* 2006;10:906–10.
  13. Katsuno G, Katsuno G, Fukunaga M, Nagakari K, Yoshikawa S. Laparoscopic one-stage resection of right and left colon complicated diverticulitis equivalent to Hinchey stage I-II. *Surg Today.* 2011;41(5):647-54.
  14. Ansari IA, Gedam BS, Shah Y, Kale VB, Bansod PY. Laparoscopic appendectomy in acute appendicitis with or without complication. *Inter J Biomed Advan Res.* 2015;6(3):275-9.
  15. Yagmurlu A, Vernon A, Barnhart DC, Georgeson KE, Harmon CM. Laparoscopic appendectomy for perforated appendicitis: a comparison with open appendectomy. *Surg Endosc.* 2006;20(7):1051-4.

**Cite this article as:** Mahmoud SH, Ayoub MT, Kotb MB, Abdelghafor M. Evaluation the role of laparoscopic management of complicated appendicitis. *Int Surg J* 2020;7:636-9.