

Original Research Article

Foreign body in urinary bladder: our experience and review of literature

Mohd Hamid Shafique Ahmed¹, Prakash W. Pawar^{1*}, Ajit S. Sawant¹, Jitendra Sakharani¹, Amandeep Arora¹, Sunil R. Patil¹, Deepak Patel²

¹Department of Urology, Lokmanya Tilak Municipal Medical College and Sion Hospital, Mumbai, Maharashtra, India

²Department of Surgery, KRIPA Maternity and Surgical Nursing Home, Mumbai, Maharashtra, India

Received: 06 November 2019

Revised: 19 November 2019

Accepted: 22 November 2019

*Correspondence:

Dr. Prakash W. Pawar,

E-mail: praxpawar@gmail.com

Copyright: © the author(s), publisher and licensee Medip Academy. This is an open-access article distributed under the terms of the Creative Commons Attribution Non-Commercial License, which permits unrestricted non-commercial use, distribution, and reproduction in any medium, provided the original work is properly cited.

ABSTRACT

Background: The objective of the study was to study clinical presentation, mode of insertion, and management of intravesical foreign bodies in patients treated at our hospital.

Methods: This was a retrospective study conducted between January 2018 to June 2019. Six patients underwent treatment for urinary bladder foreign body at Lokmanya Tilak Municipal Medical College and Sion Hospital, Mumbai, Maharashtra, India. Medical records were analyzed retrospectively with regard to nature of foreign body, each patient's clinical presentation, the mode of insertion and how the foreign was managed.

Results: A total of six foreign bodies were retrieved from patients' urinary bladders. The patients range in age from 28 to 65 years (mean age was 45 years). The Clinical presentation includes Lower urinary tract symptoms. Four patients were male and two were female. Circumstance of insertion was iatrogenic in 5 patients and self-insertion in 1 patient. Five patients were treated endoscopically (cystoscopy retrieval with or without cystolithotripsy) and one patient with supra pubic cystostomy. Post-operative hospital stay was of 1 to 2 days. Mean follow up period was 3 months. Psychiatric referral and counseling were done in patients with history of self-insertion of foreign body in urinary bladder.

Conclusions: Foreign body in the urinary bladder remain a challenge to the urologist. Removal of the foreign body without injury to the urinary bladder or the urethra gives good outcome.

Keywords: Foreign body, Urinary bladder, Cystoscopy, Iatrogenic, Self insertion

INTRODUCTION

Foreign body (FB) in the urinary bladder is relatively rare and poses urological challenges in terms of diagnosis and treatment. Foreign bodies were inserted as a result of self-insertion, iatrogenic, migration from adjacent organ and penetrating ballistic trauma.¹ These objects include hairpin wires, fish hook, piece of Foleys catheter, intra uterine contraceptive device, Surgical gauze, broken part of endoscopic instrument, rubber bands, hair ball, metal rods, telephonic cables, orthopedic screws, household

batteries etc.²⁻⁵ Those that insert foreign bodies to have sexual gratification present late due to guilt feeling and embarrassment. Diagnosis is done by history and clinical examination. Presentation of patients with urinary bladder foreign body may be asymptomatic or complaint of dysuria, hematuria, frequency, poor stream, suprapubic pain and urinary retention and chronic pelvic pain. Complication may be associated with long standing urinary bladder foreign body as recurrent urinary tract infections, stone formation and urosepsis.^{3,4,6} Rarely some patient may develop complications such as perforation of

urinary bladder or hydronephrosis with renal function impairment.^{7,8} Radio opaque foreign body will be seen on plain X-ray while ultrasonography is useful in radiolucent foreign body. Computed tomography also has its use in diagnosis. Cystoscopy has both diagnostic and therapeutic value. Treatment includes removal of foreign body, prevention of complications and psychiatric evaluation in cases of self-insertion. Treatment in each case has to individualized based on the nature, location, size of foreign body and the age of the patient.^{3,6}

This study was performed to characterize the nature, clinical presentation, mode of insertion and management of intravesical foreign bodies in patient treated at our hospital. In this study we share our one and half year experience of foreign body in the urinary bladder.

METHODS

This is retrospective study carried out at Lokmanya Tilak Municipal Medical College and Sion Hospital, Mumbai, Maharashtra, India, between January 2018 to June 2019. Retrospectively the data of the patient who presented to outpatient department with foreign body in urinary bladder analyzed after applying following inclusion and exclusion criteria:

Inclusion criteria were patients of all age groups of both the sex with any co morbidities. There were no exclusion criteria (none of the patient with foreign body in urinary bladder was excluded from the study)

Medical records were analyzed with regard to nature of foreign body, each patient clinical presentation, the mode of insertion and how the foreign was managed. This study is approved by institutional ethics committee.

RESULTS

The demographic profile of patients, nature of foreign body, clinical presentation, the mode of insertion and method used to remove object and contributing factor if any is outlined in (Table 1).

A total of six foreign bodies were retrieved from patient’s urinary bladder. The patients range in age from 28 to 65 years (mean age is 45 years). The clinical presentation includes lower urinary tract symptoms i.e. frequency of urination, urgency, intermittency and dysuria etc. Four patients were male and two were female. Circumstance of insertion was iatrogenic in 5 patients and self-insertion in 1 patient. The foreign body included hem-o-Lok clips (Figure 1), rubber band (Figure 2), Foley’s catheter tip (Figure 3), trans vaginal tape (Figure 4), suture material (Figure 5) and Broken DJ stent (Figure 6). Except Hem-o-Lok clip all other patient has stone formed over the foreign body. Five patients were treated endoscopically (cystoscopy retrieval with or without cystolithotripsy) and One patient with suprapubic cystostomy. Postoperative hospital stay was of 1 to 2 days. Mean follow up period was 3 months. Psychiatric referral and counseling done in patients with history of self-insertion of foreign body.

Table 1: Summary of foreign bodies in urinary bladder.

Case no.	Age	Sex	Foreign body	Circumstance of entry	Treatment	Hospital stay (no. of days)
1	65	Male	Hem-o-Lok clip	Post radical prostatectomy	Cystoscopic removal	1
2	30	Male	Rubber band	Self inflicted	Cystoscopic removal	1
3	32	Male	Catheter tip	Iatrogenic	Cystoscopic removal	1
4	60	Female	Trans vaginal tape	Migration	Cystoscopic removal	1
5	55	Female	Silk suture material	Post hysterectomy	Cystoscopic removal	1
6	28	Male	Broken DJ stent	Retained DJ stent	Suprapubiccystostomy	2

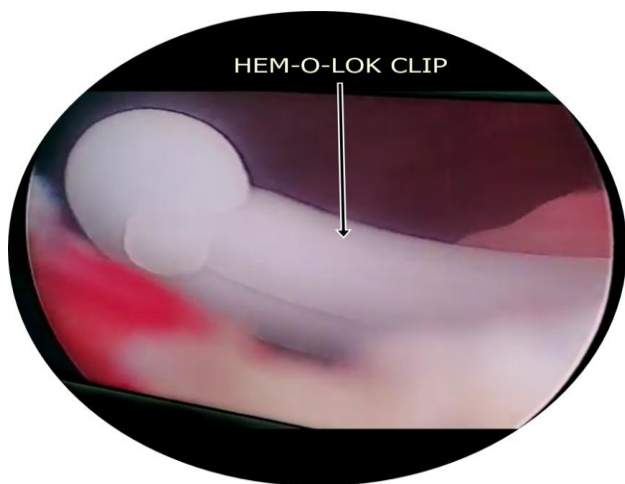


Figure 1: Cystoscopy image showing Hem-o-lok clip.

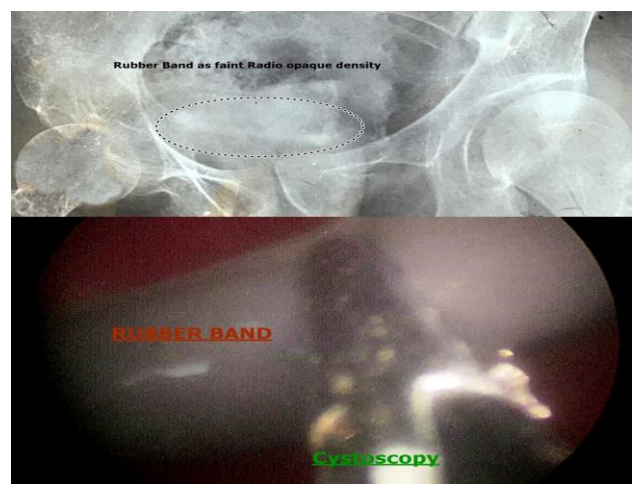


Figure 2: Self-inflicted rubber band

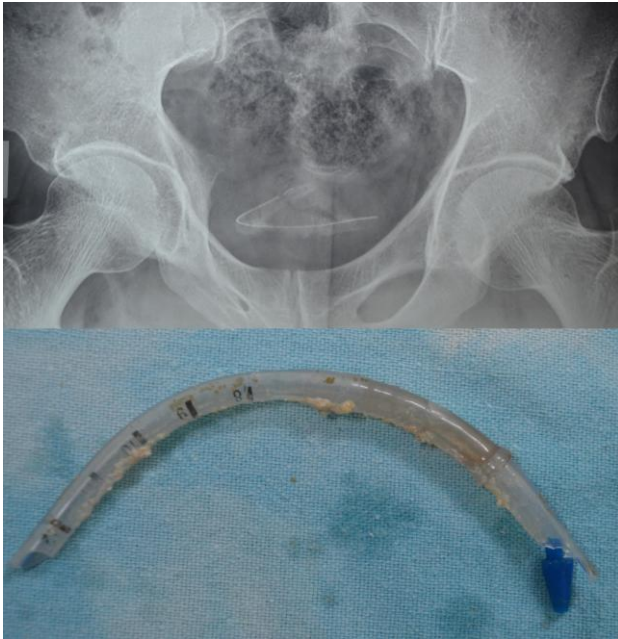


Figure 3: Part of Foley's catheter.

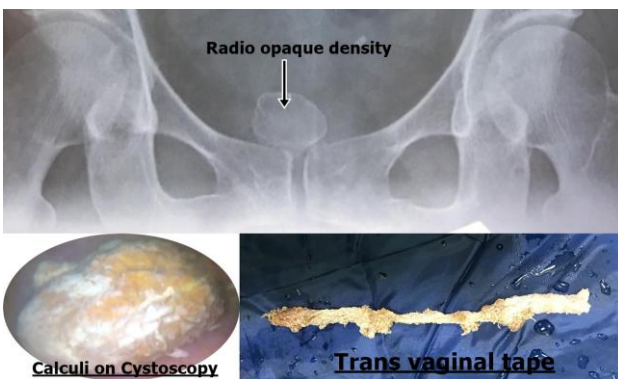


Figure 4: Transvaginal tape.

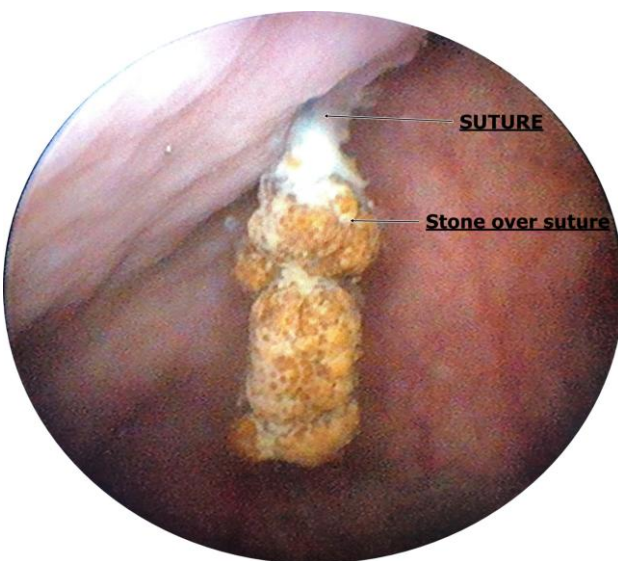

Figure 5: Cystoscopic of suture material with stone over it.

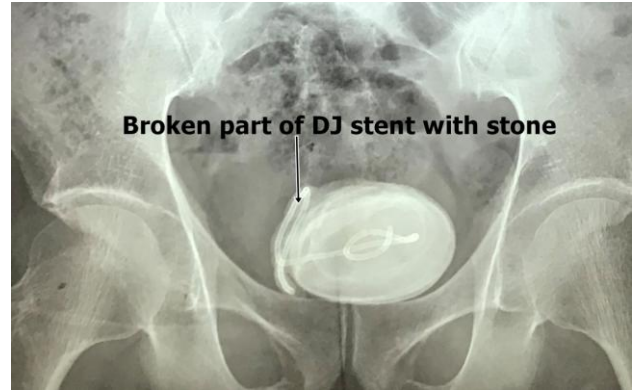


Figure 6: X-ray of broken DJ stent with stone over it.

DISCUSSION

The presence of urinary bladder foreign body has been interesting topic representing a challenge of diagnosis and management. Various treatment options are reported for the treatment of bladder foreign body are endoscopic, percutaneous, open and laparoscopic. However endoscopic retrieval is the preferred treatment among urologist. Method of choice for extraction varies according to the size and mobility of object inside the urinary bladder.⁹

Foreign bodies in the urinary bladder are rare as we encountered 6 cases over a period of one and half year, Odemen et al and Irekpita et al also noted rare occurrence.^{1,10} There were 4 male and 2 female patients showing male preponderance which is similar to other studies.^{2,3,11,12} Late presentation is common due to ignorance and poverty.

In this study of foreign body in urinary bladder one was self-inflicted and 5 patients has iatrogenic insertion. In index case no. 1 patient had postoperative laparoscopic radical prostatectomy Hem-o-Lok clip migration, which is rare event, literature search shows only few such reported case.^{13,14} In case no. 2 patient had self-inflicted insertion of rubber band in urethra for sexual gratification and accidental slippage into the bladder, self-insertion of foreign body is one of the leading causes for foreign body in the urinary bladder.¹⁵ As in case no. 4 trans vaginal tape migrating in urinary bladder presenting as foreign body is very rare event and English literature search reveals few such case report.¹⁶ Post hysterectomy suture material migration in urinary bladder presenting as bladder calculi is rare event but preventable by taking due care during procedure, in this index case holmium laser energy source used to cut the suture from urinary bladder followed by cystolithitriy. Catheter tip and broken double J stent is among the common cause of foreign body in urinary bladder.¹⁷

The treatment in patients with foreign body in urinary bladder should be aimed at removing the foreign object, avoiding complications. The method of removing the

foreign body should be selected based on size, nature and mobility of object.^{3,6} If surgeon feels the object can be removed without urethral damage endoscopic method should be attempted first.¹⁸ This could be either cystoscopic removal using grasping forceps or transurethral cystolitholapaxy using stone punch. Smaller guided object can easily be removed intact, but larger object require fragmentation. In some patients, the extraction of foreign body from the bladder may be difficult and open surgery is indicated. To minimize the risk of open surgery, urologists innovated other techniques for treatment. Delair et al utilized a small supra pubic cystostomy (3 cm in length) to extract a toy frog guided by endoscopic visualization.¹⁹ Other surgeons combined two techniques: percutaneous or laparoscopic technique with endoscopy to avoid open supra pubic cystostomy. Hutton and Huddart used percutaneous puncture for retrieval of an intravesical foreign body using direct transurethral visualization.²⁰ The role of laparoscopy in the treatment of bladder foreign body has also been discussed. Feliu et al reported laparoscopic management of calcified bladder foreign body due to displaced tack after laparoscopic incisional hernia repair. Tacks were removed laparoscopically together with partial cystectomy.²¹ Recently an encrusted polypropylene mesh could be extracted successfully from the bladder mucosa using single port laparoscopic surgery.²² Also, a novel radiological technique was described using fluoroscope under local anesthesia to guide a gooseneck snare through endoscopic sheath to retrieve an FB after pushing it into the bladder.²³ Open surgery is indicated in sharp or large sized FB or after failed endoscopy.^{24,25}

Psychiatric evaluation is recommended in patients with self-inflicted foreign body in the urethra or urinary bladder due to high incidence of psychiatric disease, mental retardation, and dementia. Doing so may reduce the risk of recurrence.²⁶⁻²⁸

The present study has its limitation of having a smaller number of patients. Larger, multi institutional study is required to standardized the treatment protocol, precaution to prevent urinary bladder foreign body and to prevent its recurrence.

CONCLUSION

Foreign bodies in the urinary bladder still remain a great challenge to the urologist, removal of the foreign body with injury to the urinary bladder or the urethra gives good outcome. Majority of foreign body can be treated by endoscopy; however open surgery is indicated in sharp or large sized foreign body or after failed endoscopy. Also open surgery is indicated if endoscopic equipments are not available or lack of surgeon's experience with endoscopic maneuvers. Psychiatric evaluation is recommended in patients with self-inflicted foreign body; doing so may reduce the risk of recurrence.

Funding: No funding sources

Conflict of interest: None declared

Ethical approval: The study was approved by the Institutional Ethics Committee

REFERENCES

- Odoemene CA, Onuh CA. Foreign Bodies In The Urinary Bladder-Case Series. *J West African Coll Surg.* 2017;7(3):124.
- Shimokihar K, Kawahara T, Hayashi Y, Tsutsumi S, Takamoto D, Mochizuki T, Uemura H. Foreign body in the bladder: A case report. *Int J Surg Case Rep.* 2017;32:22-4.
- Kesri G, Gupta P, Gupta HL, Sadasukhi TC, Dangayachi KK. An unusual self inflicted foreign body in the urinary bladder. *IJMPCR.* 2015;4:68-71.
- Soomro H, Jalbani IK, Faruqi N. Intravesical foreign body: tertiary care center experience from Pakistan. *J. Pak Med Asso.* 2016;66:131-3.
- Vezhaventhan G, Jeyaraman R. Unusual foreign body in the urinary bladder. A case report. *Internet J Urol.* 2006;4.
- Oguntayo OA, Zayyan M, Odogwu K, Koledade K, Mbibu H, Bello A. Foreign body (metallic flashlight cover) in the urinary bladder mimicking advanced cancer of the cervix: case report and review of the literature. *Afr J Urol.* 2009;15:111-3.
- Cho BS, Park KS, Kang MH, Han GS, Lee SY, Cha SH, et al. Unilateral hydronephrosis and hydroureter by foreign body in urinary bladder: a case report. *J Korean Med Sci.* 2012;27(6):704-6.
- Bantis A, Sountoulides P, Kalaitzis C, Giannakopoulos S, Agelonidou E, Foutziti S, Touloupidis S. Perforation of the urinary bladder caused by transurethral insertion of a pencil for the purpose of masturbation in a 29-year-old female. *Case Rep Med.* 2010;2010.
- vanOphoven A, deKernion JB. Clinical management of foreign bodies of the genitourinary tract. *J Urol.* 2000;164(2):274-87.
- Irekpita E, Imomoh P, Kesieme E, Onuorah V. Intravesical foreign bodies: A case report and a review of the literature. *Int Med Case Rep J.* 2011;4:35-9.
- Eckford SD, Persad RA, Brewster SF, Gingell JC. Intravesical foreign bodies; five year review. *Br J Urol.* 1992;69:41-5.
- Bakshi GK, Agarwal S, Shetty SV. An unusual foreign body in the bladder. *J Postgrad Med.* 2000;46:41-2.
- Chen YC, Chen HW, Lee CH, Huang SP. A rare delayed bladder migration of a Hem-o-lok clip 5 years after robotic-assisted radical prostatectomy. *Urologiainternationalis.* 2019;102(4):495-8.
- Tunnard GJ, Biyani CS. An unusual complication of a Hem-o-Lok Clip® following laparoscopic radical prostatectomy. *J Laparoendoscopic Advanced Surg Tech.* 2009;19(5):649-51.

15. Mahadevappa N, Kochhar G, Vilvopathy KS, Dharwadkar S, Kumar S. Self-inflicted foreign bodies in lower genitourinary tract in males: our experience and review of literature. *Urol Ann.* 2016;8(3):338.
16. Firoozi F, Ingber MS, Goldman HB. Pure transvaginal removal of eroded mesh and retained foreign body in the bladder. *Int Urogynecol J.* 2010;21(6):757-60.
17. Bansal A, Yadav P, Kumar M, Sankhwar S, Purkait B, Jhanwar A, Singh S. Foreign bodies in the urinary bladder and their management: a single-centre experience from North India. *Int Neurourol J.* 2016;20(3):260.
18. Rahman NU, Elliott SP, McAninch JW. Self-inflicted male urethral foreign body insertion: endoscopic management and complications. *BJU Int.* 2004;94:1051-3.
19. DeLair SM, Bernal RM, Keegan KA, Ellison LM. Ship in a bottle: rapid extraction of large intravesical foreign bodies. *Urol.* 2006;67(3):612-13.
20. Hutton KA, Huddart SN. Percutaneous retrieval of an intravesical foreign body using direct transurethral visualization: a technique applicable to small children. *BJU Int.* 1999;83(3):337-8.
21. Bukowski TP, Williams CR. Percutaneous intravesical retrieval of a misplaced urethral stent: new laparoscopic instrumentation. *J Urol.* 1997;157(6):2257.
22. Feliu X, Claveria R, Besora P, Luque D, Vinas X. A calcified foreign body in the bladder due to: an unusual complication after laparoscopic incisional hernia repair. *Surg Laparosc Endosc Percutan Tech.* 2011;21(1):28-30.
23. Ingber MS, Stein RJ, Rackley RR, Firoozi F, Irwin BH, Kaouk JH, Desai MM. Single-port transvesical excision of foreign body in the bladder. *Urology.* 2009;74(6):1347-50.
24. Seong BJ, Kim SJ, Kim HS, Kim DY, Chung JM, Choi S. Acute urinary retention due to urethral foreign bodies. *J Korean Continence Soc.* 2006;10:60-2.
25. Oksay T, Ozorak A, Ergun O, BurakHoscan M, Kosar A, Serel TA. Percutaneous Removal of a Very Unusual Foreign Body from the Bladder: Case Report and Literature Review. *JAEM.* 2013;12:231-3.
26. Costa G, Di Tonno F, Capodiecici S, Laurini L, Casagrande R, Lavelli D. Self-introduction of foreign bodies into the urethra: a multidisciplinary problem. *Int Urol Nephrol.* 1993;25:77-81.
27. Stravodimos KG, Koritsiadis G, Koutalellis G. Electrical wire as a foreign body in a male urethra: a case report. *J Med Case Rep.* 2009;3:49.
28. Sukkarieh T, Smaldone M, Shah B. Multiple foreign bodies in the anterior and posterior urethra. *Int Braz J Urol.* 2004;30:219-20.

Cite this article as: Ahmed MHS, Pawar PW, Sawant AS, Sakharani J, Arora A, Patil SR, et al. Foreign body in urinary bladder: our experience and review of literature. *Int Surg J* 2019;6:4327-31.