

Original Research Article

Sigmoid volvulus - an important cause of intestinal obstruction: how to deal with it?

Sujan Narayan Agrawal, Kamal Singh Kanwar

Department of Surgery, Late SBRKM Government Medical College, Jagdalpur, Chhattisgarh, India

Received: 16 November 2019

Revised: 20 December 2019

Accepted: 06 December 2020

*Correspondence:

Dr. Sujan Narayan Agrawal,
E-mail: drsujanagrawal@gmail.com

Copyright: © the author(s), publisher and licensee Medip Academy. This is an open-access article distributed under the terms of the Creative Commons Attribution Non-Commercial License, which permits unrestricted non-commercial use, distribution, and reproduction in any medium, provided the original work is properly cited.

ABSTRACT

Background: The objective of the study was to discuss the appropriate course of action in cases of sigmoid volvulus. It becomes important due to its high morbidity and mortality and its acute emergency presentation.

Methods: This is a retrospective study of sigmoid volvulus admitted in the department of surgery at Late SBRKM Government Medical College, Jagdalpur. The study period was from January 2017 to August 2019. A total of 27 cases were under study. On admission, they were examined, investigated and treated surgically and the outcome noted.

Results: Out of 27 patients 25 were male and 2 cases were female. The mean age group was 65 years. The comorbidities consisted of previous abdominal surgeries, diabetes mellitus, hypertension, and renal complications. The common factor was chronic constipation and purgative abuse. All underwent a definitive surgical procedure like sigmoidectomy and colorectal anastomosis or sigmoidectomy and colostomy. In the second group colostomy closure and end to end anastomosis carried on at a later date. We have lost 5 patients in the post-operative period.

Conclusions: The sigmoid volvulus presents with the features of intestinal obstruction. The real danger is the gangrene of the bowel, as a consequence of ischaemia. It requires an early surgical intervention for the maximum benefit of the patient.

Keywords: Gangrenes of bowel, Intestinal obstruction, Ischaemia, Sigmoid volvulus

INTRODUCTION

A sigmoid volvulus (SV) is said to occur when the bowel twists around its axis. The SV is the commonest volvulus because of its long mesentery, narrow base and relatively solid faecal content. The other volvulus is caecal volvulus, gastric volvulus, small intestinal volvulus, and volvulus neonatorum. In the sigmoid volvulus, the small intestine may get knotted around its base and then it becomes compound volvulus. The SV was first described by Von Rokitansky in 1836.^{1,2}

In this condition the sigmoid colon twists around its mesentery causing a closed-loop obstruction. It is a rare cause of intestinal obstruction in European countries but

fairly common in Asian countries, Africa, the Middle East, Turkey, etc. The prevalence in these countries may be due to the high fibre content in their diet.³⁻⁴ The twisting of the bowel causes a closed-loop obstruction of intestine and vascular occlusion. The loops of the intestine (sigmoid colon) undergo an enormous dilatation due to accumulated gases. The gases are produced due to bacterial fermentation and diffused air. The air mainly consists of carbon-di-oxide, nitrogen, and sulphur-di-oxide. Due to vascular occlusion, first, the venous return and then the arterial supply is impaired. This causes bowel ischemia and eventually gangrene. This may lead to perforation peritonitis. Due to all these, the life of the patient is in grave danger and they require emergency interference.

The objective of this study was to establish that the sigmoid volvulus is an important cause of intestinal obstruction and is a surgical emergency. The diagnosis is simple by good clinical examination and plane X-ray abdomen. Timely surgical intervention reduces the mortality and morbidity.

METHODS

In our institute 27 cases of volvulus are diagnosed and managed surgically. Our experience is discussed along with the literature review.

It is a retrospective study of 27 patients with acute sigmoid volvulus treated in the Department of Surgery, Late SBRKM Government Medical College, Jagdalpur. The study period is from January 2017 to August 2019. All patients underwent clinical examination and necessary investigations. We identified patients affected by the co-morbidities. The selection criteria are the patients presenting with features of intestinal obstruction like; Pain and distension of abdomen, constipation with or without nausea/vomiting. A total of 27 patients were studied. The patient's data included demographics, co-morbidities, clinical manifestations, radiological investigations and interventions. The clinical outcome recorded.

After establishing the diagnosis of sigmoid volvulus patients are prepared for emergency surgery. The patients underwent routine blood examinations like CBC, blood sugar estimation, kidney function tests, liver function tests, HIV, and HbsAg profile and plane X-ray abdomen. The plane X-ray abdomen showing dilated bowel loops (coffee Bean sign, Figure-1). The diagnosis is reached easily with a clinical presentation along with an X-ray abdomen. CT Abdomen is not routinely done. Colonoscopy/sigmoidoscopy is also not done because of their late presentation. All the cases underwent exploratory laparotomy. The following course of action taken: Sigmoidectomy and colo-rectal anastomosis as a one-stage procedure. In patients who were in poor general condition with co-morbidities and may not be able to sustain long surgical procedure/anaesthesia, they underwent Sigmoidectomy and end colostomy. These patients are taken for colo-rectal anastomosis after 6-8 weeks.

In the post-operative period, a total of six (22.22%) patients expired due to poor general conditions and co-morbidities. The hospital stay is 10±5 days.

RESULTS

Out of the 27 patients with acute sigmoid volvulus, 25 (92.59%) patients were male and 2 (7.41%) female. The age was between 50 to 80 years. The mean age of the patient under study was 65 years. Six patients had a history of previous abdominal surgery, there was a history of chronic constipation and purgative abuse in most of the patients (21 patients) and 5 patients were on psychotropic drugs.

The clinical manifestations included abdominal pain in all patients (100%) and 8 (29.63%) patients had vomiting along with pain abdomen. All gave a history of not passing motion and gas (obstipation). On examination marked abdominal distension was found in all the patients. The visible loop was seen in 8 patients. The abdomen was tympanic on percussion. The rectal digital exam revealed an empty rectum and no blood on the finger stall.

Table 1: The patient's demographic data.

Parameters	Number of patients
Number of patients	27
Male	25 (92.59%)
Female	02 (07.41%)
Age	50-80 years
Average age	65 years
Presenting complaints	Pain abdomen Vomiting Obstipation
Clinical examination	Distension of Abdomen Visible loops of intestine.
Co-morbidities	Previous abdominal surgery. Diabetes mellitus Hypertension Use of psychotropic drugs Deranged Renal function
Operative procedure	Sigmoidectomy with colo-rectal anastomosis Sigmoidectomy with end colostomy (Hartmann's procedure) Colostomy closure after 6 weeks
Hospital stay	10±7 days
Deaths	6 (22.22%) patients

The early surgical intervention is the main stay of treatment. With the delay in instituting the definitive treatment, mortality and morbidity increases considerably. Out of 27 patients six patients (22.22%) expired in the post-operative period due to complications.

DISCUSSION

Volvulus is one of the important causes of intestinal obstruction. It is said to occur when a loop of intestine along with its mesentery twists around itself (resulting in closed-loop intestinal obstruction). Regardless of the cause, Volvulus gives rise to symptoms due to two mechanisms i.e. mechanical obstruction and ischemia of bowel due to twisting of the mesentery.

The SV was first described by von Rokitansky in 1836.⁵ The 15% of large bowel obstructions are due to volvulus and the sigmoid colon is the commonest site. It occurs in ~70 to 80% of cases.⁶

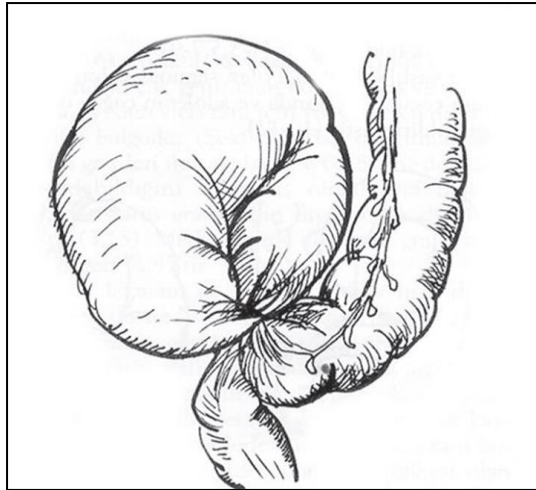


Figure 1: The schematic diagram of sigmoid volvulus.⁵

The volvulus neonatorum; volvulus of the small gut and gastric volvulus are known to occur but are a rare entity. Sigmoid volvulus is common in India and makes 7% of all intestinal obstruction. South Indians are more prone to suffer from this ailment due to their high roughage diet.⁷ In North America and Europe, it represents 3, 7-6% of all intestinal occlusions and it usually occurs in elderly patients with a greater incidence in the 8th decade.⁸ In other countries this pathology shows a higher incidence: 24% in East India, 40% in North India, 32% in Iran, 31% in Zimbabwe, 54% in Ethiopia, and 33% in Sudan.⁹⁻¹⁴ In the rest of the world the volvulus is not so common. The community-based incidence of SV in the USA is 1.67 per 100,000 persons per year.⁴ It generally affects adults in 4th to 8th decades of life.¹ It predominately occurs in the male population. It is associated with old age, chronic constipation, and purgative abuse, insane and institutionalized patients.¹⁵

The more incidence of sigmoid being twisted may be due to its anatomy i.e. long redundant mesentery with a narrow base, and relatively solid faecal mass. The rotation is almost always anticlockwise. It requires one and a half turns of twisting to cause a vascular obstruction and eventually gangrene. The bowel may perforate at the root or the summit of the sigmoid loop. The two important pathophysiological processes that occur in sigmoid volvulus are a luminal obstruction and vascular occlusion.¹ This mechanical occlusion and bacterial fermentation cause distension of twisted-loop and the proximal colon. It is the increased intracolonic pressure which further jeopardy the capillary perfusion. The mechanical occlusion and thrombosis of the vessels contribute to ischemia.¹⁶ Mucosal ischemic insult, bacterial propagation and toxemia result in colonic gangrene. Increased intra-abdominal pressure causes the abdominal compartmental syndrome.¹⁴ The hypertrophied colonic wall, thickened mesentery, prominent Vessels, splayed out taeniae, and abolished haustrations are the morphological changes seen in SV.¹⁷ These pathological changes cause enormous dilatation of colon. Occasionally

small bowel may come to the root of the twisted colon and get knotted giving rise to what is called ileosigmoid knotting. It is a compound volvulus.

Clinically the patient presents with pain abdomen, which is to start with, on the left side of the abdomen, and then it spreads to the whole of the abdomen. There is huge pneumatic distension of the abdomen, the very characteristic of sigmoid volvulus. It is because of the entrapped gases. The main component of this gas is CO₂, nitrogen (90%) and also hydrogen sulphide (10%). There is absolute constipation i.e. neither faeces nor flatus is passed. It is also termed as obstipation. The vomiting is a late feature and gives rise to dehydration and electrolyte disturbances. Retching and hiccough may occur.¹⁸

In the present study also all the patients presented with pain and distension of abdomen. The huge distension of abdomen, along with constipation is characteristic of sigmoid volvulus in our study and with other authors.¹⁸

The differential diagnosis of colonic volvulus comprises of the other causes of colonic distension. This encompasses all of the mechanical as well as the non-obstructive causes. Mechanical causes include obstruction due to neoplasms both colonic and extra-colonic. Benign causes are diverticulitis and inflammatory bowel diseases. The non-obstructive causes include colonic pseudo-obstruction (Ogilvie's syndrome) and paralytic ileus. In children, Hirschsprung's disease may be considered.¹⁹ The major diagnosis from which sigmoid volvulus must be distinguished is the colonic obstruction caused by neoplasm. The plane x-ray abdomen in sigmoid volvulus is very typical (coffee bean sign). In the presence of truly massive distension differentiation may be difficult. At the time of attempted sigmoidoscopic detorsion, the obstructing neoplasm will hopefully be visualized, and the true diagnosis will be apparent.

The diagnostic workup consists of a plane X-ray abdomen in our study also by other authors. The typical presentation of the sigmoid volvulus in-plane X-ray abdomen is "coffee bean sign". It is due to the huge dilatation and coiling of the sigmoid colon.²⁰ Lau et al reported that plain abdominal radiographs were diagnostic of sigmoid volvulus in 66% patients. Plain abdominal radiographs may also reveal other conditions that are included in the differential diagnosis of colonic volvulus, as well as complicating factors, such as pneumoperitonium or pneumatosis.²¹ In the case where the clinical examination and plain X-ray are not confirmatory in the diagnosis of sigmoid volvulus, a contrast CT scan is done, preferably with the enema of water-soluble dye. This contrast-enhanced CT demonstrates a smooth, tapered point of obstruction known as a "bird's beak" sign at the point of colonic torsion.²² In the review by Lau et al, the combination of plain abdominal radiographs and contrast enema images was diagnostic for sigmoid volvulus in 90% of patients.

The water-soluble contrast medium is preferable to barium contrast because the latter could cause chemical peritonitis in the setting of a perforated colon.

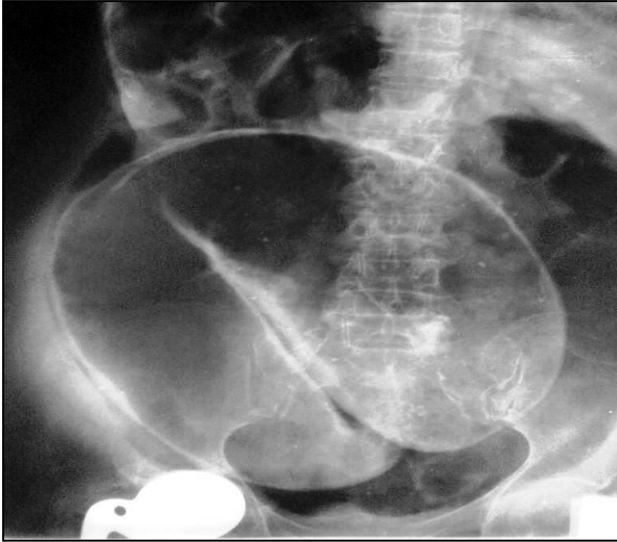


Figure 2: The coffee bean sign.²³

The treatment option consists of attempts of detorsion and sigmoidoscopy or operative interference. The patients of sigmoid volvulus are dehydrated and brought to the hospital in a decompensate state. So, before doing any procedure they should be adequately hydrated, and appropriate analgesics and antibiotics are instituted, wherever indicated blood transfusion is considered. The mainstay of emergency treatment is detorsion and decompression. Detorsion of sigmoid volvulus has been described using several techniques, including rigid proctoscopy, flexible sigmoidoscopy or colonoscopy, the blind passage of a rectal tube, and use of a column of barium during Barium enema examination etc.²⁴ Successful decompression using one of these techniques is generally reported in the range of 70%-80%.²⁵ A significant concern is that the sigmoid may already be gangrenous. Several authors in Asia and Africa have noted an incidence of gangrene approaching 50%, as well as a significant incidence of double volvulus (ileosigmoid knotting). So, their recommendation is to go for emergency laparotomy without attempts to detorsion and derotation.^{25,26} If ischemic mucosa is visualized, attempts at detorsion should be immediately abandoned and operative intervention should be undertaken emergently. For this reason, it is strongly recommended to use those techniques only, where, the mucosa can be visualized before detorsion. For the same reason, the blind passage of the rectal tube should be avoided, as it may result in a high incidence of perforation and peritonitis. The non-viability of the bowel should at once be suspected in the presence of signs of compromised bowel and/or systemic sepsis like fever, dehydration, and shock.²⁷ In such cases exploratory laparotomy should be performed without any delay. The gangrenous bowel should be excised, without detorsion and minimal manipulation. It is to prevent the

release of endotoxins and bacteria in general circulation.²⁸

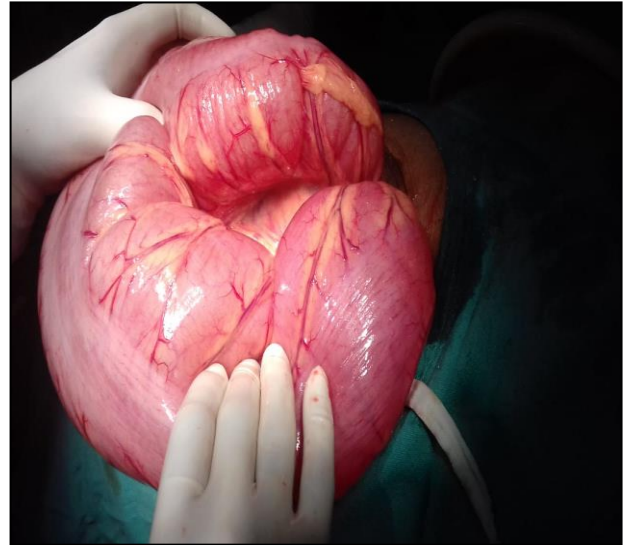


Figure 3: The sigmoid volvulus, showing the dilated and twisted sigmoid colon.

After removal of the gangrenous bowel, the next decision is either primary colorectal anastomosis or Hartmann procedure i.e., resection of the recto-sigmoid colon with the closure of anorectal stump and formation of an end colostomy. The second stage operation consists of end-to-end anastomosis at a later date.

The overall mortality and morbidity remain the same in various approaches.²⁹ End colostomy creation is the most appropriate choice in haemodynamically unstable patients and with co-morbidities. The emergency surgery also includes various non-definitive procedures like detorsion, sigmoidopexy, mesosigmoidoplasty but sigmoid resection with primary anastomosis or resection with a stoma is the most commonly recommended procedure because of the high recurrence rate of non-definitive procedures, although they carry 8% to 33% mortality rates.³⁰ In unstable patients, after the resection of the gangrenous segment, Hartman's or Mikulicz procedures may be life-saving. Still other alternatives are tube sigmoidostomy, extraperitonealization of the sigmoid colon, and percutaneous endoscopic colostomy.³¹ The laparoscopic techniques are generally reserved for elective surgeries.³² Although there has been considerable controversy about the ideal definitive procedure, sigmoid resection and anastomosis are generally recommended for good-risk patients. These procedures also have a low mortality rate of 0% to 15%.³³

Our study is compared with that of other authors. There is a clear male predominance, age group above 50 years and mortality is from 8 to 15%. In our study the mortality is slightly more because all the patients underwent emergency surgical procedure only.

The SV carries a grave prognosis, but good understanding of pathophysiology, early intervention, and pre-operative stabilization of the patients has contributed to improved survival. In good institutions, the overall mortality has dropped down to below 10%.⁴ The presence of toxic and oligemic shock, bowel gangrene, colonic

perforation, major co-morbidity, advanced age, and emergency surgery increases the mortality rate.³ The overall morbidity is 6% to 24%, and wound infection, incisional dehiscence, intra-abdominal abscess, anastomotic leak, and the stomal complications are the main problems.²⁹

Table 2: The outcome of SV as cited by various authors.

S. no.	Author	No of patients	Male sex (%)	Age (mean) in years	Emergency operation (%)	Mortality (%)
1	Khanna ²⁶	111	2.5:1 (M:F ratio)	51.1	41.44	6.3
2	Atamanalp ²⁷	952	82.4	58.6	47.6	8.1
3	Oren ³⁰	827	83.2	57.9	47.5	15.8
4	Present study	27	92.59	65	100	22.22

CONCLUSION

The sigmoid volvulus is an acute surgical emergency. It calls for urgent surgical intervention. The other modalities of management have limited value. The pathophysiology is a consequence of two important mechanisms i.e., closed loop obstruction and bowel ischemia. The plane X-ray abdomen is a sensitive investigation; more sophisticated investigations can be carried out in selected patients only. In the postoperative period, the complications consist of wound infection, wound dehiscence, intra-abdominal abscess, anastomotic leak, and stoma related problem.

The contribution of the present study is to stress upon the early surgical intervention rather than trying for non-surgical options. As the surgical intervention is delayed there is steep rise in mortality and morbidity. It is also essential to correct the hemodynamic instability before surgery. Plane X-ray abdomen is a primary modality of investigation. Timely surgical intervention is rewarding and gives gratifying results.

Funding: No funding sources

Conflict of interest: None declared

Ethical approval: Not required

REFERENCES

1. Raveenthiran V, Madiba TE, Atamanalp SS, De U. Volvulus of the sigmoid colon. *Colorec Dis.* 2010;12(7):1-7.
2. Arnold GJ, Nance FC. Volvulus of the sigmoid colon. *Anna Surg.* 1973;177(5):527-37.
3. Madiba TE, Thomson SR, Corr P. Volvulus of the sigmoid colon. *Gastroenterol Forum.* 1997;8:28-33.
4. Ballantyne GH, Brandner MD, Beart Jr RW, Ilstrup DM. Volvulus of the colon. Incidence and mortality. *Ann Surg.* 1985 Jul;202(1):83.
5. Atamanalp SS. Sigmoid volvulus. *Eurasian J Medi.* 2010;42(3):142.
6. Holder WD. Intestinal obstruction. *Gastroenterol Clin North Am.* 1988;17(2):317-340.
7. Sriram Bhat M. Sigmoid volvulus (volvulus of Pelvic colon). Sriram Bhat M, eds. *SRB's Manual of Surgery*, 4th ed. New Delhi, Jaypee Brothers medical publishers (P) Ltd; 2013: 997-1000.
8. Cirocchi R, Farinella E, La Mura F, Morelli U, Trastulli S, Milani D, et al. The sigmoid volvulus: surgical timing and mortality for different clinical types. *World J Emerg Surg.* 2010;5(1):1.
9. Sinha RS. A clinical appraisal of volvulus of the pelvic colon. With special reference to aetiology and treatment. *Br J Surg.* 1969;56(11):838-40.
10. Agrawal RL, Misra MK. Volvulus of the small intestine in Northern India. *Am J Surg.* 1970;120(3):366-70.
11. Saidi F. The high incidence of intestinal volvulus in Iran. *Gut.* 1969;10(10):838-41.
12. Waithe A. Intestinal obstruction in Rhodesian african. *East Afr Med J.* 1961;38:525-35.
13. Shepherd JJ. The epidemiology and clinical presentation of sigmoid volvulus. *Br J Surg.* 1969;56(5):353-9.
14. Taha SE, Suleiman SI. Volvulus of the sigmoid colon in the Gezira. *Br J Surg.* 1980;67(6):433-5.
15. Friedman JD, Odland MD, Bubrick MP. Experience with colonic volvulus. *Dis Colon Rect.* 1989;32(5):409-16.
16. Gibney EJ. Volvulus of the sigmoid colon. *Surg Gynecol Obstet.* 1991;173(3):243-55.
17. Madiba TE, Ramdial PK, Dada MA, Mokoena TR. Histological evidence of hypertrophy and ischaemia in sigmoid volvulus among Africans. *East Afr Med J.* 1999;76(7):381-4.
18. Grossmann EM, Longo WE, Stratton MD, Virgo KS, Johnson FE. Sigmoid volvulus in department of veterans affairs medical centers. *Dis Colon Rect.* 2000;43(3):414-8.
19. Tsushima GK, Fieshner PR. Colonic volvulus: imaging, diagnosis, and differential diagnosis. *Seminars Colon Rectal Surg.* 1999;10(3):139-44.
20. Burrell HC, Baker DM, Wardrop P, Evans AJ. Significant plain film findings in sigmoid volvulus. *Clini Radiol.* 1994;49(5):317-9.

21. Lau KC, Miller BJ, Schache DJ, Cohen JR. A study of large-bowel volvulus in urban Australia. *Canad J Surg.* 2006;49(3):203.
22. Ericksen AS, Krasna MJ, Mast BA, Noshier JL, Brolin RE. Use of gastrointestinal contrast studies in obstruction of the small and large bowel. *Dis Colon Rect.* 1990;33(1):56-64.
23. Coffee Bean Sign (Sigmoid Colon). Available at: <https://radiopaedia.org/articles/coffee-bean-sign-sigmoid-colon>. Accessed on 14 November 2019.
24. Brother TE, Strodel WE, Eckhauser FE. Endoscopy in colonic volvulus. *Ann Surg.* 1987;206(1):1-4.
25. Mangiante EC, Croce MA, Fabian TC, Britt LG. Sigmoid volvulus. A four-decade experience. *Am Surg.* 1989;55(1):41-4.
26. Khanna AK, Kumar P, Khanna R. Sigmoid volvulus. *Dis Colon Rect.* 1999;42(8):1081-4.
27. Atamanalp SS. Treatment of sigmoid volvulus: a single-center experience of 952 patients over 46.5 years. *Techn Coloproctol.* 2013;17(5):561-9.
28. Madiba TE, Thomson SR. The management of sigmoid volvulus. *J Royal College Surg Edinburgh.* 2000;45(2).
29. Coban S, Yilmaz M, Terzi A, Yildiz F, Ozgor D, Ara C, et al. Resection and primary anastomosis with or without modified blow-hole colostomy for sigmoid volvulus. *World J Gastroenterol: WJG.* 2008;14(36):5590.
30. Ören D, Atamanalp SS, Aydinli B, Yildirgan Mİ, Başoğlu M, Polat KY, et al. An algorithm for the management of sigmoid colon volvulus and the safety of primary resection: experience with 827 cases. *Dis Colon Rectum.* 2007;50(4):489-97.
31. Bhatnagar BN, Sharma CL. Nonresective alternative for the cure of nongangrenous sigmoid volvulus. *Dis Colon Rectum.* 1998;41(3):381-8.
32. Fleshman JL. Laparoscopic management of colonic volvulus. *Semin Colon Rectal Surg.* 1999;10:154-7.
33. Atamanalp SS, Ören D, Aydinli B, ÖZTÜRK G, Polat KY, Başoğlu M, et al. Elective treatment of detorsioned sigmoid volvulus. *Turkish J Medi Scie.* 2008 May 28;38(3):227-34.

Cite this article as: Agrawal SN, Kanwar KS. Sigmoid volvulus - an important cause of intestinal obstruction: how to deal with it? *Int Surg J* 2020;7:465-70.