

Original Research Article

Manual anal dilatation for the treatment of chronic anal fissures: our experience

Mohammed Kashif Habeb^{1*}, Mohammed Wasif Habeb²

¹Department of General Surgery, M.V.J. Medical College and Research Hospital, Bengaluru, Karnataka, India

²Department of General Surgery, M.S. Ramaiah Medical College and Hospital, Bengaluru, Karnataka, India

Received: 08 November 2019

Accepted: 15 November 2019

*Correspondence:

Dr. Mohammed Kashif Habeb,

E-mail: kashifhabeb@rocketmail.com

Copyright: © the author(s), publisher and licensee Medip Academy. This is an open-access article distributed under the terms of the Creative Commons Attribution Non-Commercial License, which permits unrestricted non-commercial use, distribution, and reproduction in any medium, provided the original work is properly cited.

ABSTRACT

Background: In this study we aim to present our experience in managing chronic anal fissures by manual anal dilatation in order to clarify whether this method is still viable in a modern surgical setup.

Methods: A total of 55 patients who underwent manual anal dilatation for chronic anal fissures from March 2016 till March 2017 were studied prospectively.

Results: 43 of the 55 patients were male and 12 were female (male: female=3.58: 1), aged between 20 to 60 years. The fissure was posterior at 6 o'clock position in 44 patients (80%) and anterior at 12 o'clock position in 8 patients (14.5%). Mean duration of hospital stay was 1.5 days. At the end of 6 weeks post op, only 37 patients (67.3%) were symptom free with the remaining 18 patients (32.7%) having complications. Among the complications, the commonest was ulcer persistence in 12 patients (21.8%). 3 patients had incontinence for flatus (5.5%), 2 had recurrence of ulcer (3.6%) and 1 had incontinence for faeces (1.8%). Mortality was 0%.

Conclusions: Anal fissure is a common benign ano-rectal condition. Once chronicity is established, it is difficult to treat and almost always warrants surgical management. Although manual anal dilatation is a simple and easy procedure, it is associated with significant rates of complication. For long term definitive treatment, manual anal dilatation should be abandoned completely in favour of other surgical techniques like lateral subcutaneous sphincterotomy.

Keywords: Chronic anal fissure, Fissure-in-ano, Manual anal dilatation, Anal stretch, Lord's anal dilatation

INTRODUCTION

Anal fissure is a common benign ano-rectal condition associated with significant morbidity. It presents as a linear ulcer in the lower anal canal, which in 85% to 90% of cases is in the midline posteriorly, in 10-15% is in midline anteriorly and lateral positions being least frequently encountered.¹ When examined under anaesthesia, it appears as a longitudinal tear in the anal canal mucosa and ano-derm below the dentate line. When traction is applied on the sides of the anal canal, the fissure appears to be triangular in shape, with its apex near the dentate line and base towards the anal verge.

Aetiologically anal fissures can either be primary (idiopathic) or secondary. The primary variant is the more common presentation. Secondary fissures arise in the presence of primary pathological conditions like Crohn's disease, ulcerative colitis, other granulomatous diseases, cancers and human immunodeficiency virus.^{1,2} The presence of lesions in atypical positions and/or multiple lesions point towards a secondary aetiology.

The first effective method found to be beneficial for treating anal fissures was manual anal dilatation. The first recorded instance of this technique was by Récamier.^{3,4} Thereafter there have been on and off periods of its

popularity. Lord performed this procedure on a large number of patients. He put forward this technique primarily for the treatment of second and third degree haemorrhoids and it was also used as a more aggressive means of treating chronic anal fissures.⁵ Watts et al showed favourable results in their case series, leading to its renewed popularity.⁶ Anal dilatation is still practiced in some hospitals. There are quite a few reasons why this operation is still being used, the foremost of these being the simplicity and the relatively short learning curve.

There have been various studies done in the past with varying conclusions.^{6,7} In this study we aim to present our experiences in managing chronic anal fissures by manual anal dilatation in order to clarify the role of this method in a modern surgical setup.

METHODS

This prospective study was conducted in the Surgical Department of Dr. Munir Bangi Hospital, Bijapur, Karnataka.

A total of 55 patients with chronic anal fissure who underwent manual anal dilatation for a period of 12 months between March 2016 and March 2017 were included in this study. Out of these 43 were male and 12 were female patients. All clinically diagnosed patients of chronic anal fissure between 20 and 60 years of age, of either sex were included.

Ethical clearance for the study was taken from the hospital board. All the patients were individually explained about the study and consented.

A detailed history was taken which included duration of pain along with other associated symptoms like constipation, bleeding per rectum, discharge and soiling, sentinel pile and previous treatment received. Anal examination was performed and all data about the anal fissure recorded. Criteria as set by The Standard Task Force, American Society of Colon and Rectal Surgeons to identify chronic anal fissures were used.⁸ Fissures failing to heal within six weeks despite straightforward dietary measures, fissures with indurated margins and lack of granulation tissue with secondary features like sentinel skin tag, hypertrophied anal papilla were termed as chronic anal fissures.

Manual uncontrolled anal dilation was performed on all of the patients under general or spinal anaesthesia. The patients were placed in lithotomy position. Clinical examination and digital rectal examination were performed again before proceeding with the surgery. A fully lubricated index finger of each hand was placed in the anal canal after one and other. Then exerting gentle but continuous outward pressure and with gradual relaxation of the internal sphincter, the middle finger of each hand was also placed in the anal canal. During this procedure the hands repeatedly moved all around in order

to relax all the segments of the lower part of the internal sphincter. The procedure was stopped when the internal anal sphincter was so much relaxed that the anal canal was accepting four fingers (two fingers of each hand) at a time without much force.

Post operatively the patients were kept nil orally till their full recovery from the anaesthesia. Effective postoperative analgesia was ensured. Warm water Sitz baths three to four times daily were started from the next morning. After their discharge from hospital patients were followed up on weekly basis for 6 weeks. They were also advised to have high intake of vegetables, high fibre diet and 10 ml of olive oil daily. During every visit any change in symptoms and signs of patients were recorded.

RESULTS

Out of the 55 patients, 43 (78.2%) were male and 12 (21.8%) were female (Figure 1), male to female ratio was 3.58: 1, with age range between 20 to 60 years. The fissure was posteriorly located at 6 o'clock position in 44 (80%) patients and anteriorly located at 12 o'clock in 8 (14.5%) patients (Figure 2). The presenting complaints in these patients were painful defaecation and constipation in all 55 patients, bleeding per rectum in 49, discharge per rectum in 25, sentinel piles or skin tags in 30 and pruritus ani in 13 patients (Figure 3).

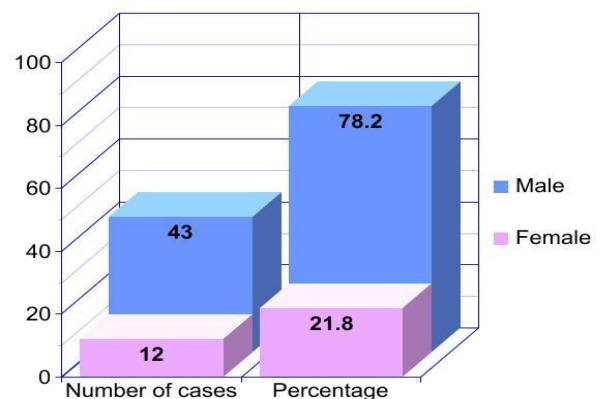


Figure 1: Sex distribution.

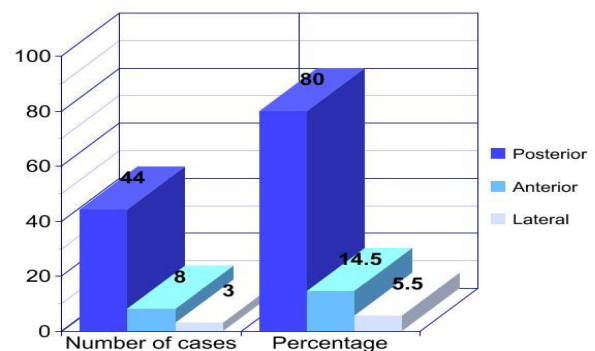


Figure 2: Position of fissure.

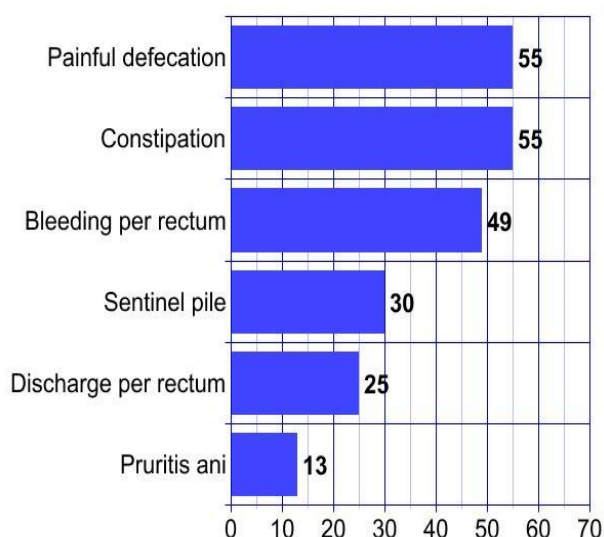


Figure 3: Symptoms at presentation.

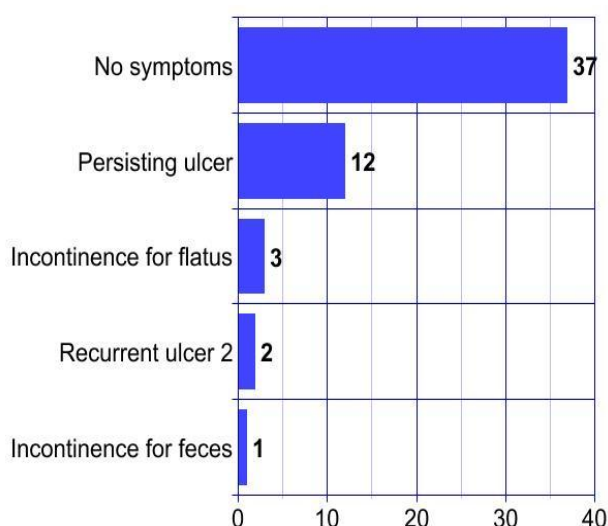


Figure 4: Post-operative complications.

Analysis of the result of the operation (anal dilatation) was based on the symptomatic improvement and the healing of the fissure (epithelialization of the ulcer). These were carried out on a weekly basis for duration of six weeks; the mean stay in the hospital following anal dilatation was 1.5 days, the duration of the regression of the symptoms ranged from post-operative day 1 to post-operative day 28.

The duration of healing of the ulcer ranged from post-operative day 2 to 6th post-operative week, the mortality during the period of the study was nil (0%). By the end of the 6th week we note that only 37 patients (67.3%) had no symptoms with complete healing of the ulcer, in the remaining 18 (32.7%) patients, 1 (1.8%) was having some degree of incontinence for stool and flatus, 3 (5.5%) patients had incontinence for flatus only, 12 (21.8%) patients had persisting ulcer and 2 (3.6%)

patients developed signs and symptoms of recurrent anal fissure after healing in the 4th post-operative week (Figure 4).

DISCUSSION

Amongst benign ano-rectal diseases, anal fissure is one of the more commonly encountered conditions. In most acute cases, complete healing could be achieved by conservative or medical treatment.^{9,10} The treatment of chronic cases though, is still a very contentious topic.¹¹ In the vast majority of chronic cases though, surgical intervention is invariably warranted due to its immediate benefit by relief of symptoms and better healing rates.¹¹ These cases are associated with significant morbidity and are difficult to manage. The objective of surgical treatment is to decrease lower anal tone as a consequence of which there will be better healing.

Surgical intervention could be in the form of manual dilatation (uncontrolled and controlled) or sphincterotomy.

Manual anal dilatation gained renewed popularity in the 1960s after it showed promising results in a number of studies.⁶ A randomised controlled trial done by Marby et al showed that manual anal dilatation gave better results than lateral subcutaneous sphincterotomy (LSS).¹² Yet again in a comparative study done in 1989 by Giebel et al., anal dilatation was stated to be superior to LSS.¹³ Numerous studies were done showing consistent success rates in the range of 87% to 100%, but with inconsistent recurrence rates ranging from 0-56%.¹⁴

In the present series we found that anal dilation resulted in complete healing in only 67.3% of the patients, this is much lower than what previous studies have shown.^{12,15-17} The rates of complications are consistent with those cited in previous series.^{4,18,19} The discrepancy noted in literature could be due to high inter operator variability. Another point of interest to be noted is that in our series the male to female ratio was found to be much higher than what is cited in literature.^{17,19} Further demographic studies need to be undertaken to find out if this is significant.

There is no single reliable way to standardize uncontrolled manual anal dilatation and both the external and internal anal sphincter can be disrupted and damaged in an irregular manner. Endosonographic studies done by Speakman et al and by Nielsen et al have shown that in most of the patients there would be irregular disruption of the anal sphincter.^{20, 21}

Nowadays the most widely accepted surgical modality for treating chronic anal fissures is lateral internal sphincterotomy or fissurectomy.²² LSS was first introduced by Notaras et al, since then numerous studies have shown it to be superior to uncontrolled anal

dilatation having lesser rates of post-operative incontinence and recurrence.^{4,15,23}

CONCLUSION

Manual anal dilatation is without doubt a simple and easy procedure, and can give immediate relieve to patients suffering from chronic anal fissures. But the high rates of complications associated with this procedure increase the morbidity of this chronic malady further and in the long run increase patient re-attendance rates, discomfort, economic burden and most of all affect the patient psycho-socially. Taking into consideration the various studies done before and the findings of this series, manual anal dilatation should be completely abandoned in favour of other surgical modalities like LSS. Regular surgical audits should be undertaken in departments to ensure that practices match internationally accepted standards.

Funding: No funding sources

Conflict of interest: None declared

Ethical approval: The study was approved by the Institutional Ethics Committee

REFERENCES

- Schubert MC, Sridhar S, Schade RR, Wexner SD. What every gastroenterologist needs to know about common anorectal disorders. *World J Gastroenterol*. 2009;15:3201-9.
- Jahnnny B, Ashurst JV. *Source Stat Pearls*. Treasure Island (FL): Stat Pearls Publishing; 2019.
- Bhardwaj R, Parker M.C. Modern perspectives in the treatment of chronic anal fissures. *Ann R Coll Surg Engl*. 2007;89(5):472-8.
- Saad AM, Omer A. Surgical treatment of chronic fissure-in-ano: a prospective randomised study. *East Afr Med J*. 1992;69(11):613-5.
- Lord PH. A new regime for the treatment of haemorrhoids. *Proc R Soc Med*. 1968;61(9):935-6.
- Siddiqui J, Fowler GE, Zahid A, Brown K, Young CJ. Treatment of anal fissure: a survey of surgical practice in Australia and New Zealand. *Colorectal Dis*. 2019;21(2):226-33.
- MacDonald A, Smith A, McNeill AD, Finlay IG. Manual dilatation of the anus. *Br J Surg*. 1992;79:1381-2.
- Perry WB, Dykes SL, Buie WD, Rafferty JF, Standards Practice Task Force of the American Society of Colon and Rectal Surgeons. Practice parameters for the management of anal fissures (3rd revision). *Dis Colon Rectum*. 2010;53:1110-5.
- Canero A, Consalvo V, Giglio F, D'Auria F, Rescigno C, Vincenzo S. Conservative Management of Chronic Anal Fissure. Results of a Case Series at 2-years Follow-up and Proposition of a New Classification. *Surg Technol Int*. 2018;33:105-9.
- Jensen SL. Treatment of first episodes of acute anal fissure: prospective randomised study of lignocaine ointment versus hydrocortisone ointment or warm sitz baths plus bran. *Br Med J (Clin Res Ed)*. 1986;292:1167-9.
- Steele SR, Madoff RD. Systematic review: the treatment of anal fissure. *Alimentar Pharmacol Therapeutic*. 2006;24(2):247-57.
- Marby M, Alexander-Williams J, Buchmann P, Arabi Y, Kappas A, Minervini S, et al. A randomized controlled trial to compare anal dilatation with lateral subcutaneous sphincterotomy for anal fissure. *Dis Colon Rectum*. 1979;22:308-11.
- Giebel GD, Horch R. Treatment of anal fissure: a comparison of three different forms of therapy. *Nippon Geka Hokan*. 1989;58:126-33.
- Madoff RD, Fleshman JW. AGA technical review on the diagnosis and care of patients with anal fissure. *Gastroenterol*. 2003;124(1):235-45.
- Jensen SL, Lund F, Nielsen OV, Tange G. Lateral subcutaneous sphincterotomy versus anal dilatation in the treatment of fissure in ano in outpatients: a prospective randomised study. *BMJ (Clin Res Ed)*. 1984;289:528-30.
- Hawley PR. The treatment of chronic fissure-in-ano: a trial of methods. *Br J Surg*. 1969;56:915.
- Isbister WH, Prasad J. Fissure-in-Ano. *Aust N Z J Surg*. 1995;65(2):107-8.
- Graham Stewart CW, Greenwood RK, Llyod-Dawis RW. A review of 50 patients with fissure in ano. *Surg Gynecol Obstet*. 1961;113:445-8.
- Watts JM, Bennett RC, Goligher JC. Stretching of anal sphincters in treatment of fissure-in-ano. *Br Med J*. 1964;2:342-3.
- Speakman CT, Burnett SJ, Kamm MA, Bartram CI. Sphincter injury after anal dilatation demonstrated by anal endosonography. *Br J Surg*. 1991;78:1429-30.
- Nielsen MB, Rasmussen OO, Pedersen JF, Christiansen J. Risk of sphincter damage and anal incontinence after anal dilatation for fissure-in-ano. An endosonographic study. *Dis Colon Rectum*. 1993;36:677-80.
- Ebinger SM, Hardt J, Warschkow R, Schmied BM, Herold A, Post S, et al. Operative and medical treatment of chronic anal fissures-a review and network meta-analysis of randomized controlled trials. *J Gastroenterol*. 2017;52(6):663-76.
- Notaras MJ. Lateral subcutaneous sphincterotomy for anal fissure. A new technique. *Proc R Soc Med*. 1969;62:713.

Cite this article as: Habeeb MK, Habeeb MW. Manual anal dilatation for the treatment of chronic anal fissures: our experience. *Int Surg J* 2019;6:4299-302.