

## Original Research Article

# Postoperative posterior fossa pseudomeningocele: risk factors and management strategies

D. Sharithra<sup>1</sup>, Sathish Anand<sup>2\*</sup>, Thanga Thirupathi Rajan<sup>2</sup>, Aravind Kumar<sup>2</sup>

<sup>2</sup>Department of Neurosurgery, <sup>1,2</sup>Saveetha Medical College, Chennai, Tamil Nadu, India

**Received:** 02 November 2019

**Revised:** 16 December 2019

**Accepted:** 17 December 2019

### \*Correspondence:

Dr. Sathish Anand,

E-mail: [sharithraraj@gmail.com](mailto:sharithraraj@gmail.com)

**Copyright:** © the author(s), publisher and licensee Medip Academy. This is an open-access article distributed under the terms of the Creative Commons Attribution Non-Commercial License, which permits unrestricted non-commercial use, distribution, and reproduction in any medium, provided the original work is properly cited.

### ABSTRACT

**Background:** Pseudomeningocele is a considerable morbidity after posterior fossa surgery. Its incidence and optimal management strategies are quite unclear. Hence the objective of this study is to define the risk factors and evaluate the management strategies and to study the incidence and morbidity of postoperative posterior fossa pseudomeningocele.

**Methods:** A retrospective study of 33 patients undergone posterior fossa surgery for variety of diseases in the department of neurosurgery, Saveetha Medical College and Hospital from January 2015 to December 2018 with emphasis on incidence of pseudomeningocele, its morbidity and treatment strategies.

**Results:** Out of 33 posterior fossa surgeries performed, 9 developed pseudomeningocele. Hence the incidence of pseudomeningocele in hospital is 27.27%. Out of 9 patients who developed pseudomeningocele, 6 patients were symptomatic, and aspiration was done to 5 patients and one patient underwent resurgery. That one patient underwent subgaleal-peritoneal shunt, excision of recurrent tumor was performed after which the symptoms subsided.

**Conclusions:** Pseudomeningocele is a well-known complication of posterior fossa surgery. The risk factors for pseudomeningocele formation after posterior fossa surgery has been evaluated. Age, sex and type of surgery are found to be a risk factors in our study. Conservative management is effective in most cases to reduce the symptoms. Surgical intervention is advocated, only when conservative treatment fails. Preventive measures like careful perioperative planning, strict adherence to aseptic techniques, usage of autologous pericranium with dural sealant augmentation, polyethylene glycol hydrogel dural sealant can be adopted.

**Keywords:** Posterior fossa surgery, Pseudomeningocele, Risk factors, Management

### INTRODUCTION

Pseudomeningocele is a well-known complication after posterior fossa surgery. Posterior fossa surgery refers to surgery in the infratentorial compartment of the calvarium, housing the cerebellum and brain stem. Posterior fossa surgeries are done in variety of pathologies like cerebellopontine tumor, microvascular decompression, Arnold chiari malformation, medulloblastoma etc.<sup>1</sup> Pseudomeningocele is the abnormal collection of CSF at the operative site following the cranial or spinal surgery. It may be due to the improper closure of dura or when CSF fills the

potential space created during the surgery. Pseudomeningocele can cause postural headache, blurry vision, dizziness, diplopia, meningitis. The incidence of pseudomeningocele formation after posterior fossa surgery ranges from 4 to 23% in literature.<sup>2</sup> A small portion of pseudomeningocele become persistent or recurrent in nature and pose the risk of wound dehiscence, CSF fistula formation, intracranial hypotension, meningitis and rarely death.

Management guidelines are lacking and different suggested treatments varying from observation to immediate surgical intervention are encountered. The

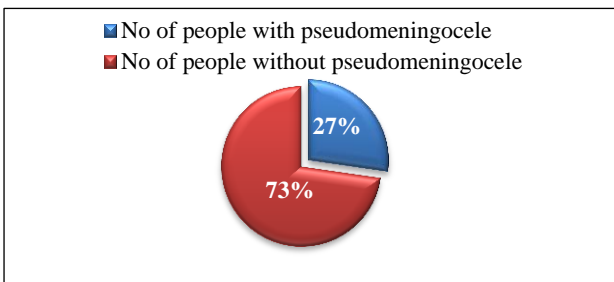
usual treatment algorithm usually consists of non-operative measures including pressure dressing, bed rest lumbar drainage.<sup>3</sup> If these conservative measures fail surgical intervention may be required like development of posterior fossa syndrome after lumbar drainage or migrating pseudomeningocele.<sup>4,5</sup> Hence the purpose of the study is to study the incidence and morbidity and to define the risk factors and evaluate the managerial strategies of postoperative posterior fossa pseudomeningocele.

**METHODS**

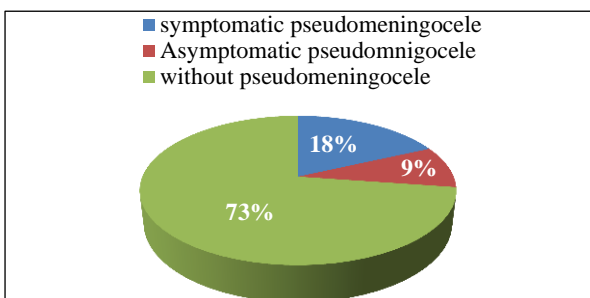
This is a retrospective, single centre study of 33 patients undergone posterior fossa surgery in the department of Neurosurgery, Saveetha Medical College and Hospital from 2015-2018. Data was collected from the medical records section of the hospital. Patients of both sexes and all age groups operated for posterior fossa pathologies were included in the study. Other complications were not considered in this study. Incidence, patients' symptomatology and clinical course and management options have been analyzed.

**RESULTS**

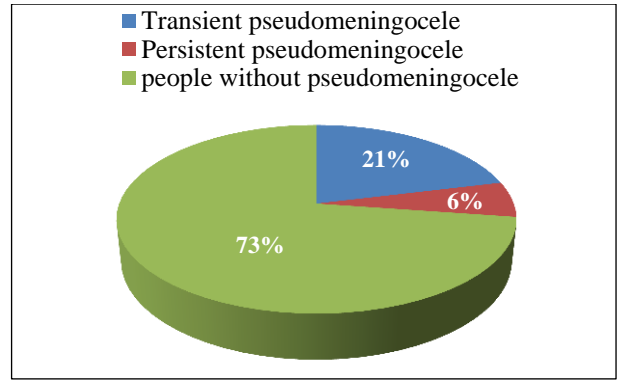
Out of 33 posterior fossa surgeries performed, 9 developed pseudomeningocele. Hence the incidence of pseudomeningocele in hospital is 27.27% (Figure 1). Out of 9 patients who developed pseudomeningocele 6 patients were symptomatic and 3 were asymptomatic (Figure 2). Out of the 6 symptomatic patients' aspiration was done to 5 patients and one patient underwent resurgery (Figure 5).



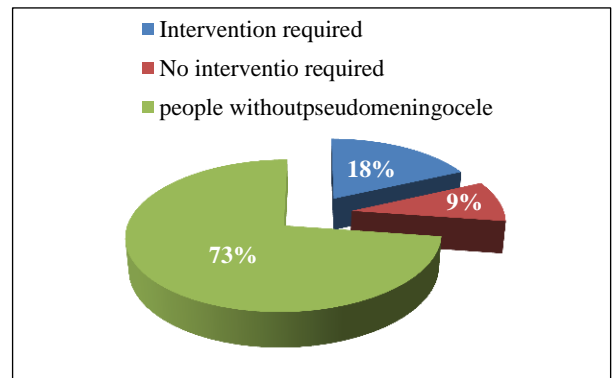
**Figure 1: Prevalence of pseudomeningocele.**



**Figure 2: Percentage of symptomatic and asymptomatic.**



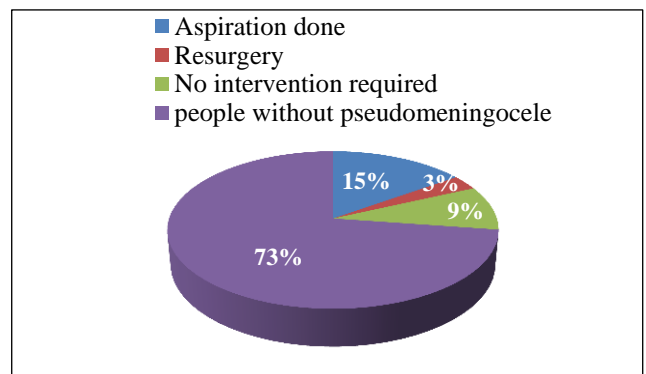
**Figure 3: Percentage of persistent and transient.**



**Figure 4: Percentage of intervention required.**

Subgaleal peritoneal shunt, excision of recurrent tumor was performed after which the symptoms subsided. Also, out of the 9 patients 7 patients were transient and 2 were persistent (Figure 3).

Out of 9 patients with pseudomeningocele, 5 (55.5 %) are male and 4 (44.4%) are female. p=0.943. Not significant. 6 out of 9 (66.6%) are within 3<sup>rd</sup> to 4<sup>th</sup> decade of life, one in 1<sup>st</sup> decade and 2 in 5<sup>th</sup> decade. Incidence in midline approach was 44.4% than retrosigmoid approach, which is 55.5%. 4 out of 9 patients who developed pseudomeningocele were initially diagnosed with CP angle tumor.



**Figure 5: Percentage of aspiration and resurgery.**

## DISCUSSION

Posterior fossa surgery traditionally implies craniectomy of suboccipital bone, which is permanent bone removal, without any type of bone replacement. Pseudomeningocele is a frequent complication of posterior fossa surgery. Pseudomeningocele may cause cosmetic deformities, positional headache, chronic meningitis, impingement on vital structures with neurological deficits and rare complications such as spontaneous intracerebral migration of a pseudomeningocele and posterior fossa cyst formation with brain stem compression.

A study conducted by Menger and Connor on pseudomeningocele formation following chiari decompression states that age and use of sealant were independent risk factors for complication. Pseudomeningocele formation among patients with sealant usage were 6.67 times those for patients without sealant. Also, there is 6% increase in odds for pseudomeningocele formation with every year increase in patient's age.<sup>6</sup>

The study on complications of posterior fossa surgery by Dubey et al, shows the incidence of pseudomeningocele to be 13%.<sup>7</sup> This study has the incidence of pseudomeningocele as 27.27%. This relative more incidence than other studies may be due to non-usage of sealant and/ or dural graft. The possible reason would be logistical and economical constraints in rural peripheral centre.

From this study it is observed that relative occurrence pseudomeningocele in relation to age and sex is not significant. In a study by Smith et al, on incidence, management, and outcome of symptomatic postoperative posterior fossa pseudomeningocele, the overall rate of symptomatic postoperative pseudo-meningocele was 14.1%. The highest rate was for midline posterior fossa surgery (16.5%) and lowest rate was for rectosigmoid surgery (11.9%).<sup>8</sup> Management of postoperative pseudomeningocele following posterior crainal fossa surgery study by Altaf et al, states that out of 137 patients' posterior midline suboccipital approach was performed in 57% cases and suboccipital retrosigmoid approach in 43% cases. Among these the incidence of pseudomeningocele complication is 5.8% (n=8).<sup>4</sup>

In this study the complication of pseudomeningocele is more common in midline posterior fossa surgery (55%) than suboccipital retrosigmoid approach (44%), which is also not significant as seen other studies.

An international survey was conducted on Management of postoperative pseudomeningoceles by Tu et al, and opinions from neurosurgeons throughout the world were sought for the management of pseudomeningocele and was concluded that initial observation is appropriate for cranial pseudo-meningoceles. Operative revision should

be received for failure of conservative treatment. Non operative measures like pressure dressing, bedrest, and CSF lumbar drainage manages pesudomeningocele in majority of the cases.<sup>9</sup>

Study on CSF leak and pseudomeningocele formation after posterior fossa tumor resection by Steinbok et al, shows the incidence of pseudomeningocele as 30% and they concluded that use of tissue glue, dural grafts and external ventricular drainage was not associated with a reduced rate of clinically or radiologically diagnosed pseudomeningocele formation.<sup>9,10</sup> There are also studies like study on augmented autologous pericranium duraplasty in posterior fossa surgeries by Lam et al, suggesting that autologous pericranium with dural sealant augmentation is an effective way to repair durotomy in posterior fossa surgeries with reduced complications.<sup>11</sup> Also study on Polyethylene glycol hydrogel dural sealant may reduce incisional cerebrospinal fluid leak after posterior fossa surgery by Than et al states that application of polyethylene glycol dural sealant to the closed dural edges may be effective at reducing incisional CSF leak after posterior fossa surgery.<sup>12</sup>

The study on postoperative cerebellar cyst with pseudomeningocele after tumor removal at craniovertebral junction by Watanabe et al states that watertight dural closure is important for prevention of formation of cyst with pseudomeningocele.<sup>13</sup>

## CONCLUSION

Pseudomeningocele is a common complication of posterior fossa surgery. Age, sex, approach of surgery, pathology of the disease is found to be non-significant factors for the development of pseudoemingocele. Conservative treatment is the management of choice in most cases to reduce the symptoms. Surgical intervention is only advocated where conservative treatment fails. Preventive measures like careful perioperative planning, strict adherence to aseptic techniques, usage of autologous pericranium with dural sealant augmentation, polyethylene glycol hydrogel dural sealant can be adopted.

*Funding: No funding sources*

*Conflict of interest: None declared*

*Ethical approval: The study was approved by the Institutional Ethics Committee*

## REFERENCES

1. Watanabe Y, Higuchi Y, Sunaoka H, Yakufujiang M, Ikegami S, Iwadate Y. Postoperative Cerebellar Cyst with Pseudomeningocele After Tumor Removal at the Craniovertebral Junction. *World Neurosurg*. 2019;130:71-6.
2. Altaf I, Shabbir A, Vohra AH, Shams S. Management of Postoperative Pseudomeningocele

- following Posterior Cranial Fossa Surgery. *Pakistan J Neurol Surg.* 2017;21(1):9-12.
3. Mehendale NH, Samy RN, Roland PS. Management of pseudomeningocele following neurotologic procedures. *Otolaryngology-Head and Neck Surgery.* 2004;131(3):253-62.
  4. Manley GT, Dillon W. Acute posterior fossa syndrome following lumbar drainage for treatment of suboccipital pseudomeningocele: Report of three cases. *J Neurosurg.* 2000;92(3):469-74.
  5. Kapanigowda MK, Nagadi A, Patwari S, Raghu V, Chadaga H. Migrating pseudomeningocele: A rare complication of posterior fossa surgery. *Neurol Ind.* 2019;67(2):532.
  6. Menger R, Connor Jr DE, Hefner M, Caldito G, Nanda A. Pseudomeningocele formation following chiari decompression: 19-year retrospective review of predisposing and prognostic factors. *Surg Neuro Inter.* 2015;6.
  7. Dubey A, Sung WS, Shaya M, Patwardhan R, Willis B, Smith D, et al. Complications of posterior cranial fossa surgery-an institutional experience of 500 patients. *Surg Neurol.* 2009;72(4):369-75.
  8. Smith GA, Strohl MP, Manjila S, Miller JP. Incidence, management, and outcome of symptomatic postoperative posterior fossa pseudomeningocele: A retrospective single-institution experience. *Operat Neurosurg.* 2016;12(3):298-304.
  9. Tu A, Tamburrini G, Steinbok P. Management of postoperative pseudomeningoceles: an international survey study. *Child's Nervous Sys.* 2014;30(11):1791-801.
  10. McCluggage SG, Watanabe K, Shoja MM, Loukas M, Tubbs RS, Oakes WJ. The history of the surgical repair of spina bifida. *Child's Nervous Sys.* 2012;28(10):1693-700.
  11. Lam FC, Kasper E. Augmented autologous pericranium duraplasty in 100 posterior fossa surgeries-a retrospective case series. *Operat Neurosurg.* 2012;71(2):302-7.
  12. Than KD, Baird CJ, Olivi A. Polyethylene glycol hydrogel dural sealant may reduce incisional cerebrospinal fluid leak after posterior fossa surgery. *Operat Neurosurg.* 2008;63(1):182-7.
  13. Santamarta D, Blazquez JA. Analysis of Cerebrospinal Fluid Related Complications Following Surgery of Posterior Fossa Tumors. *Neurocirugia.* 2003;14(2):117-26.

**Cite this article as:** Sharithra D, Sathish, Rajan TT, Kumar A. Postoperative posterior fossa pseudomeningocele: risk factors and management strategies. *Int Surg J* 2020;7:201-4.