

## Research Article

# Early mobilization after flexor tendon repair of injuries in hand: a prospective study

Loya Lava Kumar S\*

Department of Orthopedics, MR Medical College, Kalaburagi, North Karnataka, India

**Received:** 13 January 2016

**Accepted:** 29 February 2016

### \*Correspondence:

Dr. Loya Lava kumar S,

E-mail: [lavakumar.loya@gmail.com](mailto:lavakumar.loya@gmail.com)

**Copyright:** © the author(s), publisher and licensee Medip Academy. This is an open-access article distributed under the terms of the Creative Commons Attribution Non-Commercial License, which permits unrestricted non-commercial use, distribution, and reproduction in any medium, provided the original work is properly cited.

## ABSTRACT

**Background:** One of the greatest challenges is the restoration of the digital function after a flexor tendon injury. Whereas an early mobilization leads to an improved tendon healing with an increased tensile strength, decreased adhesion formation, early return of function and less stiffness and deformity. This study was conducted to assess the efficacy of an early mobilization in the flexor injury patients in the different zones of the hand.

**Methods:** 43 patients between the ages 10-70 years with flexor tendon injuries in the all zones of the hand admitted to our hospital were included into the study. Modified Kessler's technique was used to repair the tendons and early mobilization of the digits was commenced on the 4th day postoperatively. The range of movement was monitored and the flexion lag and extension lags were noted.

**Results:** The total number of injured digits were 58, out of which, 32 (58%) were in zone 2, 14 in zone 3 (25%), 8 in zone 5 (15%) and 4 in zone 1 (2%). Most of the excellent results were seen in the ring and the little fingers, where the flexion lag was <1cm and extension lag <150. The poor results were seen mainly in the index fingers where there were 2 cases of the flexion lag being more than 3cm.

**Conclusions:** Modified Kessler technique is very useful in providing tensile strength and allowing early gentle active and passive movement of the fingers. This reduces the tendon rupture and the chance of forming adhesion.

**Keywords:** Flexor tendon repair, Early mobilization, Modified Kessler's technique

## INTRODUCTION

One of the most active parts of our body is the hand and its normal function is essential for the daily function of our life. The normal integrity of the bones, tendons and neurovascular system are highly essential for the proper functioning of the hand, and any injury to these can cause a total deterioration of the hand function.<sup>1</sup>

Hand injuries are very common, which account for about one-fifth of the patients in the emergency department, and of them 1-2% have tendon lacerations.<sup>2,3</sup>

One of the greatest challenges is the restoration of the digital function after a flexor tendon injury. Some of the major hindrances for attaining good results after a flexor tendon repair are scarring, adhesion formation and

subsequent stiffness. The flexor lacerations in the finger also showed poor performance after primary repair and the digital sheath was referred to as 'no man's land'.

The primary surgical repair along with the restoration of the length and the strength of the injured tendon is highly essential to give the best possible outcome. The outcome also is known to depend on the age of the patient, nerve injury, injury level and type, type of repair and post repair therapy.<sup>4-9</sup>

The post-operative rehabilitation of the tendon injuries have resulted in many mobilization protocols, all having merits as well as demerits. The ultimate goal of all is a strong and flexible tendon. Thus, there has been tremendous progress not only in the primary care, repair technique, suture technique, understanding of the

biomechanics and the post-operative protocol, but also in mobilization protocols which have ranged from immobilization to early or delayed mobilization<sup>4-8,10-15</sup>.

It has been seen that post-operative immobilization leads to increased disability, weak tensile strength, decreased functional capacity, stiffness and deformity, whereas an early mobilization leads to an improved tendon healing with an increased tensile strength, decreased adhesion formation, early return of function and less stiffness and deformity. However, there are demerits as well, one of them being rupture of the tendons.<sup>16</sup>

We had therefore conducted a prospective study to assess the efficacy of an early mobilization in the flexor injury patients in the different zones of the hand.

## METHODS

This prospective study was conducted by the department of orthopedics at MR Medical College over a period of two years. 43 patients between the ages 10-70 years with flexor tendon injuries in the all zones of the hand admitted to our hospital were included into the study. Fractures which were uncomplicated and nerve injuries were included in the study, while extensor tendon injuries were excluded from the study.

The damaged tendons were repaired by modified Kessler' method by using double stranded core suture 4/0 nylon and a 6/0 nylon for a circumferential suture. Tendon sheath was repaired where it was possible. The wrist was maintained at 40° flexion and metacarpals at 60° by a dorsal plaster slab for 2 days, along with a compression dressing at the site of surgery. This was removed on the third day of surgery and if healing well, a light dressing was done. The plaster slab was removed and a thermoplastic dorsal splint was put up, and the wrist was maintained at 40° flexion and metacarpals at 70°. This was not extended up to the fingers, so that they could move freely.

The mobilization of the fingers were then commenced, which included a gentle flexion of the phalangeal joints to 20° and then full extension followed by relaxation. This cycle was performed 5 times in 2 sessions on the first day with a slow increase in cycles and the range of flexion and extension in the following days.

This was followed by flexion and extension of the wrist without resistance, after the removal of the splint, consequently followed by balling of the fist. This was done, till the patient achieved a grip.

In the 4<sup>th</sup> week, after the removal of the dorsal splint, a neutral splint was added, which helped in progressive and resisted mobilization. This was followed by electrical stimulation only after the flexor muscles had healed substantially. A slow gradation of the electrical stimulation in the patients was commenced cautiously

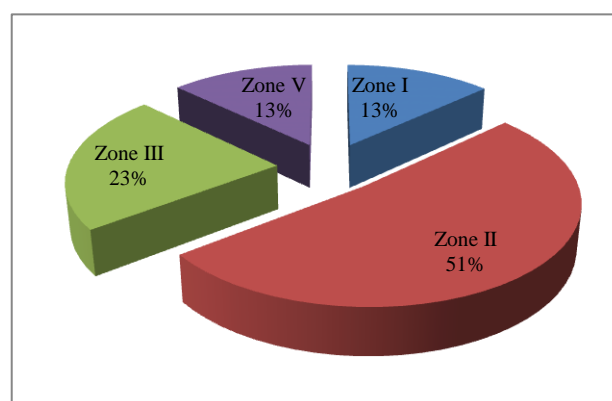
after about 4<sup>th</sup> week post-surgery. This was followed by resistive mobilization so as to build the muscle power. If flexion tenderness or stiffness was observed passive stretching or splinting was applied.

The flexion lag was measured as the pulp-to-palm distance in centimeters, whereas the extension lag was measured as the amount of extension remaining in degree, comparing to normal digits.

The activity and the extent of mobilization was measured by the Total Active Motion score (TAM). The Total active flexion was measured as the sum of TAM of metacarpophalangeal joint, proximal interphalangeal joint, distal interphalangeal joint minus the total extension deficit of all the joints. It was graded excellent if the score was 100% of normal, good if it was 75%-99%, fair if it was 50-74% and poor if the scores were below 50% of the normal.

## RESULTS

Of the 43 patients, 29 (67.4%) of them had injuries in the left hand and 14 (22.6%) in the right hand, 37 were males and 6 were females. The total number of injured digits were 58, out of which, 32 (58%) were in zone 2, 14 in zone 3 (25%), 8 in zone 5 (15%) and 4 in zone 1 (2%) (Figure 1).



**Figure 1: Number of injuries in the different zones in hand.**

**Table 1: Flexion lag of the injured digits.**

Digits	No. of digits injured	Up to 1 cm	1-2 cm	2-3 cm	3 cm
Thumb	6	3	1	1	1
Index Finger	11	4	4	1	2
Middle Finger	14	8	5	1	0
Ring Finger	18	12	5	0	1
Little finger	9	4	2	2	1

Most of the excellent results were seen in the ring and the little fingers, where the flexion was <1cm and extension lag <15°. The poor results were seen mainly in the index

fingers where there were 2 cases of the flexion lag being more than 3 cm (Table 1 and 2).

**Table 2: Extension lag of the injured fingers.**

Digits	No. of digits	<15°	16-30°	31-45°	>45°
Thumb	6	3	1	2	0
Index finger	11	7	3	1	0
Middle finger	14	10	4	0	0
Ring finger	18	11	7	0	0
Little finger	9	7	2	0	0

The total active motion scores were excellent in 8.6% of the cases and good in 72.4% of the patients. Only 3.4% of the patients showed poor scores and both these patients showed adhesions (Table 3).

**Table 3: Total active motion scores.**

	Score
Excellent	5 (8.6%)
Good	42 (72.4%)
Fair	9 (15.5%)
Poor	2 (3.4%)

## DISCUSSION

Flexor tendon injuries are one of the common hand injuries which occur in young male patients mainly of the working class. Our study had observed a very high dominance of males over females with 37 out of the 43 patients being males (86%). This prevalence of males versus female patients was also observed by Saini et al, in their study.<sup>16</sup>

There are many postoperative study protocols which range from strict immobilization to early protected mobilization of fingers. The best clinical results were observed with Kleinert's dynamic traction and active extension- passive flexion type of mobilization. However, poor gliding was observed between superficially and profundus tendons especially in zone II which leads to adhesions. This cannot be overcome by passive gliding alone. This could be due to the buckling up of tendons inside the flexor sheath or due to post injury oedema and exudative fluid reactions.<sup>17-20</sup>

But many authors were dissatisfied with the active extension- passive flexion type of regimen and there were experimental and clinical evidence of early active flexion mobilization as beneficial to tendon repair. Becker et al suggested dynamic splintage with passive flexion and active extension was unable to produce enough movement at the suture site. Manske et al suggested sufficient tendon extension to prevent the formation of adhesions was accomplished by active muscle contractions.<sup>21,22</sup>

Our study showed a good to excellent results in 81% of the cases and poor results only in 3.4% of the cases. In both these cases, formations of adhesions were observed. Ring and little fingers showed active movement earliest. This was corroborated by a study by Saini et al. 70% excellence in a study by Cullen et al and Chow et al a,d 100% by Silfverskiöld were also reported.<sup>16,23-25</sup>

We found no cases of tendon rupture in our study. We had use a double stranded suture for the tendon repair. This double stranded suture is said not only to give strength to the tendon but also prevents the gliding of the tendon in edematous repair zones and flexor sheath. Thurman et al in their study, compared the strength on 2, 4, and 6 strand techniques, and observed that 2 or 4 strand technique with modified Kessler repair and epitendinous suture provided adequate strength for the tendon and prevented ruptures. Similar results were stated in other studies.<sup>16,26-29</sup>

We had used in our study, the dorsal splint at the beginning of our rehabilitation procedure to provide the full unrestricted extension in the joints, which is of great importance as it reduced the possibility of extension stiffness. This was confirmed by other studies.<sup>30,31</sup>

## CONCLUSION

We conclude that the modified Kessler technique is very useful in provide in tensile strength and allow early gentle active and passive movement of the fingers. This reduces the tendon rupture and the chance of forming adhesion. Thus, good and capable repair of the tendon and early mobilization of the joints are very important in tendon repair.

*Funding: No funding sources*

*Conflict of interest: None declared*

*Ethical approval: The study was approved by the institutional ethics committee*

## REFERENCES

1. Nasab SAM, Saeidian NSSR, Emami H. Functional outcome of flexor tendon repair of the hand at zone 5 and post-operative early mobilization of the fingers. Pak J Med Sci. 2013;29(1):43-6.
2. Dias JJ, Elias MG. Hand injury costs. Injury. 2006;37(11):1071-7.
3. Frazier WH, Miller M, Fox RS, Brand D, Finseth F. Hand injuries: incidence and epidemiology in an emergency service. Journal of the American College of Emergency Physicians. 1978;7(7):265-8.
4. Lexer E. Die verwerthung der freien sehnentransplantation. Archiv Klin Chir. 1912;98:818-25.
5. Harmer TW. Tendon suture. Boston Med Surg J. 1917;177:808-10.
6. Kirchmayr L. Zur Technik der Sehnennaht. Zentralbl Chir. 1917;40:906-7.

7. Lahey FH. A tendon suture which permits immediate motion. *Boston Med Surg J.* 1923;22:851-2.
8. Bunnell S. Repair of tendons in the fingers and description of two new instruments. *Surg Gynaecol Obstet.* 1918;126:103-10.
9. Strickland JW. Flexor tendon injuries: Foundations of treatment. *J Am Acad Orthop Surg.* 1995;3:44-54.
10. Hatano I, Suga T, Diao E, Peimer CA, Howard C. Adhesions from flexor tendon surgery: an animal study comparing surgical techniques. *J Hand Surg Am.* 2000;25:252-9.
11. Kain CC, Russell JE, Rouse AM, Manske PR. Regional differences in matrix formation in the healing flexor tendon. *Clin Orthop Relat Res.* 1988;229:308-12.
12. Klein MB, Yalamanchi N, Pham H, Longaker MT, Chang J. Flexor tendon healing in vitro: effects of TGF-beta on tendon cell collagen production. *J Hand Surg Am.* 2002;27:615-20.
13. Zhao C, Amadio PC, Momose T, Couvreur P, Zobitz ME, An KN. The effect of suture technique on adhesion formation after flexor tendon repair for partial lacerations in a canine model. *J Trauma.* 2001;51:917-21.
14. Ketchum LD. Suture materials and suture techniques used in tendon repair. *Hand Clin.* 1985;1:43-53.
15. Hunter JM, Schneider LH, Mackin EJ, editors. *Tendon surgery in the hand.* St Louis: Mosby; 1987.
16. Saini N, Kundnani V, Patni P, Gupta SP. Outcome of early active mobilization after flexor tendons repair in zones II-V in hand. *Indian J Orthop.* 2010;44(3):314-21.
17. Bircan C, El O, Akalin E, Bacakoglu AK, Gulbahar S, Sahin E, et al. Functional outcome in patients with zone V flexor tendon injuries. *Arch Orthop Trauma Surg.* 2005;125(6):405-9.
18. Hagberg L, Selvik G. Tendon excursion and dehiscence during early controlled mobilization after flexor tendon repair in zone II: an x-ray stereophotogrammetric analysis. *J Hand Surg Am.* 1991;16:669-80.
19. Silfverskiöld KL, May EJ, Tornvall AH. Flexor digitorum profundus tendon excursions during controlled motion after flexor tendon repair in zone II: a prospective clinical study. *J Hand Surg Am.* 1992;17:122-31.
20. Horii E, Lin GT, Cooney WP, Linscheid RL, An KN. Comparative flexor tendon excursion after passive mobilization: an in vitro study. *J Hand Surg Am.* 1992;17:559-66.
21. Becker H. Primary repair of flexor tendon in the hand without immobilization preliminary report. *Hand.* 1978;10(1):37-47.
22. Manske PR. Flexor tendon healing. *J Hand Surg.* 1988;13:237-45.
23. Cullen KW, Tolhurst P, Lang D, Page RE. Flexor tendon repair in zone II followed by controlled active mobilization. *J Hand Surg Br.* 1989;14:392-5.
24. Chow SP, Stephens MM, Ngai WK, So YC, Pun WK, Chu M, et al. A splint for controlled active motion after flexor tendon repair: Design, mechanical testing, and preliminary clinical results. *J Hand Surg Am.* 1990;15:645-51.
25. Silfverskiöld KL, May EJ, Tornvall AH. Tendon excursion after flexor tendon repair in zone II: result with a new controlled motion program. *J Hand Surg Am.* 1993;18:403-10.
26. Thurman RT, Trumble TE, Hanel DP, Trencor AF, Kiser PK. 2, 4, 6 strand zone II flexor tendon repair: An in situ biomechanical comparison using a cadaver model. *J Hand Surg Am.* 1998;23:261-5.
27. Aoki M, Manske PR, Pruitt DL, Kubota H, Larson BJ. Work of flexion after flexor tendon repair according to the placement of sutures. *Clin Orthop Relat Res.* 1995;320:205-10.
28. Pruitt DL, Manske PR, Fink B. Cyclic stress analysis of flexor tendon repair. *J Hand Surg Am.* 1991;16:701-7.
29. Mashadi ZB, Amis AA. Variation of holding strength of synthetic absorbable flexor tendon sutures with time. *J Hand Surg Br.* 1992;17:278-81.
30. Gelberman RH, Nunley JA, Osterman AL, Breen TF, Dimick MP, Woo SI-Y. Influences of the protected passive mobilization interval of flexor tendon healing : a prospective randomized clinical study. *Clin Orthop.* 1991;264:189-96.
31. Silfverskiöld KL, May EJ. Flexor tendon repair in zone II with a new suture technique and an early mobilization program combining passive and active flexion. *J Hand Surg.* 1994;19:53-60.

**Cite this article as:** Kumar LLS. Early mobilization after flexor tendon repair of injuries in hand: a prospective study. *Int Surg J* 2016;3:649-52.