

## Case Report

# Non-Hodgkin's lymphoma of T lymphoblastic type of mediastinum and breast, mimicking thymoma

Divakar Bhat, Bhagyashree Jagadeeshwara\*

Department of Cardiothoracic and Vascular Surgery, Mallya Hospital, Bangalore, Karnataka, India

**Received:** 23 October 2019

**Accepted:** 03 December 2019

### \*Correspondence:

Dr. Bhagyashree Jagadeeshwara,  
E-mail: [bhagyashree01@gmail.com](mailto:bhagyashree01@gmail.com)

**Copyright:** © the author(s), publisher and licensee Medip Academy. This is an open-access article distributed under the terms of the Creative Commons Attribution Non-Commercial License, which permits unrestricted non-commercial use, distribution, and reproduction in any medium, provided the original work is properly cited.

### ABSTRACT

T cell lymphoblastic lymphoma (T-LBL) is a common variant of Non-Hodgkin's tumor of mediastinum which presents late due to aggressive spread. Immunohistochemical studies are conclusive in their diagnosis. We present a rare case of mediastinal tumor with left breast mass which mimicked thymoma on computed tomography guided biopsy but was diagnosed T-LBL on immunohistochemistry after surgical excision.

**Keywords:** T-cell lymphoblastic lymphoma, Thymic tumors, Non-Hodgkin's lymphoma of mediastinum

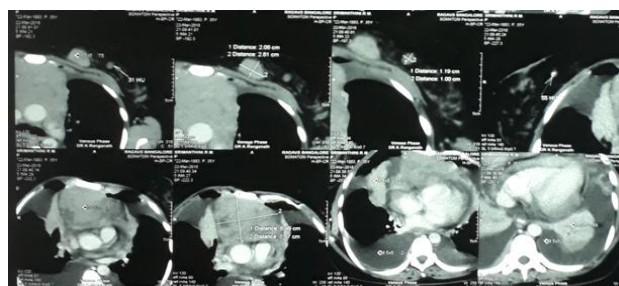
### INTRODUCTION

Lymphoblastic lymphoma (LBL) compromise 2% of all types of non-Hodgkin's lymphoma (NHL). The T-cell phenotype accounts for 80-90% of cases, which arises from immature T-cells.<sup>1</sup> T cell lymphoblastic lymphoma (T-LBL) presents with primary involvement of thymus, nodal or extra nodal. It is aggressive and progresses rapidly, presenting as stage IV disease in more than 70%. Immunohistochemistry (IHC) studies of the tissue is diagnostic in these cases. Chemotherapy is the main treatment in T-LBL type of NHL.

### CASE REPORT

A 34-year-old female suspected to have tubercular effusion (which was not subsiding with intercostal tube drainage of more than one week) was referred for further management. Patient was diagnosed with fibrocystic disease of left breast lump prior to these episodes of massive pleural effusion. Patient had developed low pitch of voice with dysphagia over one week. Blood investigations were normal. CT thorax revealed large lobular heterogeneous patchily enhancing soft tissue

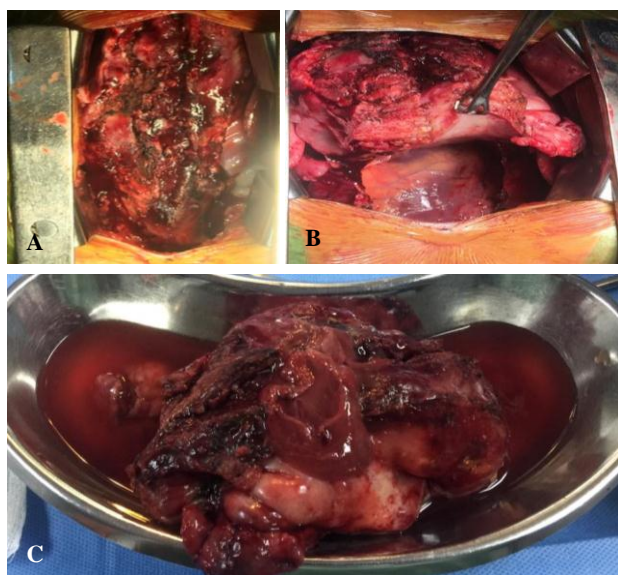
attenuated mass across the anterior mediastinal/pre vascular space with associated pericardial invasion, bilateral pleural effusion and bilateral mammary medial quadrant lobulations (Figure 1).



**Figure 1: CT thorax revealed large lobular heterogeneous patchily enhancing soft tissue attenuated mass across the anterior mediastinal/pre vascular space with associated pericardial invasion, bilateral pleural effusion and bilateral mammary medial quadrant lobulations.**

CT guided biopsy suggestive of type B1 thymoma. Hence patient posted for resection. On operating table dirty

greyish mass, rubbery in consistency was found adherent to under surface of sternum, also invaded the anterior pericardium and bilateral pleura. Small multiple similar consistency, dirty greyish nodules seen over the lower lobe lungs and diaphragm. The mass in the left breast was of soft to firm consistency, whitish, 4×3 cms. (Figure 2) tumor debulking done along with anterior pericardium and sent for HPE, which gave definitive diagnosis of NHL lymphoblastic lymphoma T-cell type (both the mediastinal and breast mass). Patient was given COP regime and endoxan. Patient worsened further. PET scan done revealed disease spread to bilateral pleura, D10, D11, D12, left breast and axillary lymphnode. Patient succumbed to disease after 1 month from surgery.



**Figure 2 (A-C): Intraoperative picture of tumor adherent to anterior surface the pericardium and resected specimen.**

## DISCUSSION

In NHL, 2% are of lymphoblastic type with the T-cell phenotype accounting for 80-90% of cases, which arises from immature T-cells.<sup>1</sup> It primarily involves of thymus, nodal or extra nodal. It is aggressive and progresses rapidly, presenting as stage IV disease in more than 70%. It predominates in young adults and adolescents with median age of diagnosis of 20 years and slight male predominance.<sup>2</sup> T-LBL of mediastinum is rapidly growing with respiratory impairment and pleural effusion being common presentation.<sup>3</sup> The 5 year survival is 45-55% in adults.<sup>3</sup> Poor prognosis when age >30-40 yrs, increased levels of LDH (more than 1.5 times normal), involvement of brain, spinal cord, bone marrow and extranodal, stage IV and presence of constitutional symptoms and anemia.<sup>4</sup> Diagnosis is mainly by biopsy with IHC studies. Treatment mainly involves chemotherapy, the various regimes are CHOP (cyclophosphamide, doxorubicin, vincristine and prednisolone) and hyper-CVAD (fractionated cyclophosphamide, vincristine, adriamycin and

dexamethasone).<sup>5-11</sup> Despite the initial remission rates of 40-60%, there is relapse. In our case, the T cell lymphoblastic lymphoma had involved breast, which is almost not seen in T-LBL. Literature search did not yield any such case report with T cell lymphoblastic lymphoma spread to breast.

## CONCLUSION

T-LBL of NHL is a common tumor seen arising in the thymus and extra nodal tissue. They present in late stage (stage IV) which gives poor prognosis. The other tumors like thymoma may mimic causing dilemma in treatment or failure of treatment. Immunohistochemistry studies are definitive in diagnosis. Our case was of aggressive lymphoblastic lymphoma of thymus, which was mimicking thymoma, (as given by CT biopsy) which has a better prognosis with surgical excision and radiotherapy. The lesion had spread to breast which is a very rare occurrence. T-lymphoblastic lymphoma has to be treated with chemotherapy and surgery to be avoided. Pitfall in differentiating thymic lymphoma and Thymomas occurs due to presence of reactive T-lymphocytosis in both conditions and also due to almost identical immunotype and morphology of lymphocytes. The main distinguishing feature is mainly in infiltrative nature of T-LBL, no or few keratin positive cells with clonal TCR rearrangement histologically.

*Funding: No funding sources*

*Conflict of interest: None declared*

*Ethical approval: Not required*

## REFERENCES

1. The Non-Hodgkin's Lymphoma Classification Project. A clinical evaluation of the International Lymphoma Study Group classification of non-Hodgkin's lymphomas. *Blood*. 1997;89:3909-18.
2. Nathwani BN, Diamond LW, Winberg CD, Kim H, Bearman RM, Glick JH, et al. Lymphoblastic lymphoma: A clinicopathologic study of 95 patients. *Cancer*. 1987;48:2347-57.
3. Mazza P, Bestini M, Macchi S, Lauria F, Pileri S, Rivano MT, et al. Lymphoblastic lymphoma in adolescents and adults. Clinical, pathological and prognostic evaluation. *Eur J Cancer Clin Oncol*. 1986;22:1503-10.
4. Morel P, Lepage E, Brice P, Dupriez b, D'Agay mf, Fenaux P, et al. Prognosis and treatment of lymphoblastic lymphoma in adults: a report on 80 patients. *J Clin Oncol*. 1992;10:1978-85.
5. Mora J, Filippa DA, Qin J, Wollner N. Lymphoblastic lymphoma of childhood and the LSA2L2 protocol: the 30-year experience at Memorial-Sloan-Ketterin Cancer Center. *Cancer*. 2003;98:1283-91.
6. Slater DE, Mertelsmann R, Koriner B, Higgins C, McKenzie S, Schauer P, et al. Lymphoblastic lymphoma in adults. *J Clin Oncol*. 1986;4:57-67.

7. Coleman CN, Picozzi VJ, Cox RS, McWhirter K, Weiss LM, Cohen JR, et al. Treatment of lymphoblastic lymphoma in adults. *J Clin Oncol.* 1986;4:1627-37.
8. Levine AM, Forman SJ, Meyer PR, Koehler SC, Liebman H, Paganini-Hill A, et al. Successful therapy of convoluted T-lymphoblastic lymphoma in adult. *Blood.* 1983;61:92-8.
9. Bernasconi C, Brusamolino E, Lazzarino M, Morra E, Pagnucco G, Orlandi E. Lymphoblastic lymphoma in adult patients; Clinicopathological features and response to intensive multi agent chemotherapy analogous to that used in acute lymphoblastic leukaemia. *Ann Oncol.* 1990;1:141-6.
10. Hoelzer D, Gokbuget N, Digel W, Faak T, Kneba M, Reutzel R, et al. Outcome of adult patients with T-lymphoblastic lymphoma treated according to protocols for acute lymphoblastic leukemia. *Blood.* 2002;99:4379-85.
11. Thomas DA, O'Brien S, Cortes J, Giles FJ, Faderl S, Verstovsek S, et al. Outcome with the hyper-CVAD regimens in lymphoblastic lymphoma. *Blood.* 2004;104:1624-30.

**Cite this article as:** Bhat D, Jagadeeshwara B. Non-Hodgkin's lymphoma of T lymphoblastic type of mediastinum and breast, mimicking thymoma. *Int Surg J* 2020;7:292-4.