

Original Research Article

Role of colour Doppler in evaluation of venous abnormalities of lower limb

Dinika Sharma*, John D'Souza, Priscilla Joshi

Department of Radiology, Bharati Vidyapeeth University (Deemed to be university), Pune, Maharashtra, India

Received: 22 October 2019

Accepted: 03 December 2019

*Correspondence:

Dr. Dinika Sharma,

E-mail: dinikasharma@gmail.com

Copyright: © the author(s), publisher and licensee Medip Academy. This is an open-access article distributed under the terms of the Creative Commons Attribution Non-Commercial License, which permits unrestricted non-commercial use, distribution, and reproduction in any medium, provided the original work is properly cited.

ABSTRACT

Background: Venous abnormalities of lower limb are a fairly common cause of morbidity. Although clinical diagnosis is the cornerstone of the diagnosis of lower limb venous disease, colour Doppler ultrasound has become the investigation of choice to confirm the diagnosis. This study evaluated the role of colour Doppler ultrasound in various venous pathologies of the lower limb and the sonographic findings were correlated with surgical and clinical findings.

Methods: 100 patients of all age groups of either sex presenting with clinically suspected entities affecting venous system of the lower limb were selected for this study.

Results: Our study showed a definite male preponderance (65%) with an incidence of 41% in the age group of 21-40 years. Isolated varicose veins had an incidence of 58% followed by isolated deep vein thrombosis (DVT) (29%), varicose veins with thrombophlebitis (5%), DVT with thrombophlebitis (5%), DVT with varicose veins (2%) and hematoma (1%). The findings correlated with surgery and gave a sensitivity of 100%.

Conclusions: Colour Doppler ultrasound is unique due to its feasibility, accessibility and cost effectiveness. Its dynamism is also exploited by various maneuvers done by the patients, radiologist and the machine parameters to bring about changes in blood flow to reach the exact diagnosis.

Keywords: Colour Doppler ultrasound, Varicose veins, DVT, lower limb, Ultrasonography

INTRODUCTION

The spectrum of venous abnormalities of the lower limb ranges from the common varicose veins at one end to the more morbid deep venous thrombosis at the other with congenital conditions like the Klippel Trenaunay syndrome, hemangiomas and tumors like leiomyosarcoma being relatively rare.¹

Although clinical diagnosis is the cornerstone of the diagnosis of lower limb venous disease. Colour Doppler ultrasound has become the investigation of choice to confirm the diagnosis.² Its easy availability, cost effectiveness and precision in achieving a diagnosis make it a versatile tool in the armamentarium available for the

clinician to use.³ The various manoeuvres like Valsalva, distal compression is simple yet effective in enhancing the diagnostic ability by changing the flow dynamics. This study described the various lower limb venous abnormalities using colour Doppler ultrasound and compared the findings with surgical findings.

METHODS

This was a prospective cross sectional study, performed over a period of 2 years (from August 2017 to August 2019) in Department of Radiology, Bharati Hospital, Pune, Maharashtra on 100 consecutive patients (35 women, 65 men, mean age 46.5 years, age range: 17 to

81 years) who presented with clinically suspected entities affecting venous system of the lower limb.

A written informed consent was taken from the patient. The patients underwent Colour Doppler ultrasound.

Sonographic technique

A Philips Affiniti 50 and 70 ultrasound machines (Philips, Amsterdam, Netherlands) with (5-12) MHz linear array transducer and curvilinear probes were used. The colour Doppler ultrasound assessment was performed with various manoeuvres like Valsalva, distal compression which were effective in enhancing the diagnostic ability by changing the flow dynamics.

The Doppler findings were correlated with the surgical findings. The patients were then followed up over a span of one year.

Statistical analysis

The data was tabulated in a Microsoft Excel sheet. The sensitivity, specificity, positive predictive value, negative predictive value and diagnostic accuracy were determined using statistical formulae. Ethical clearance was given by the ethical committee, Bharati Vidyapeeth University (deemed to be University), Pune, Maharashtra.

RESULTS

Our study showed a definite male preponderance (65%) with highest prevalence of venous abnormalities in the age group of 21-40 years (41 patients). The various pathologies seen in 100 cases were isolated varicose veins (58%), isolated DVT (29%), both varicose veins and thrombophlebitis 5%, DVT with thrombophlebitis 5% and DVT with varicose veins 2%. These findings were correlated with operative findings and gave a sensitivity of 100%.

Table 1: Demographics of the study.

Variables	Total number of cases (n=100)
Mean age	46.5 years
Sex	Males: 65%, females: 35%
Most common symptom	Pain with prominent veins: 44%
Most common diagnosis	Isolated varicose veins: 58%, Isolated DVT: 29%
Most common vein involved in DVT	Superficial femoral vein: 31 patients
USG correlation with postoperative findings	Sensitivity: 100%

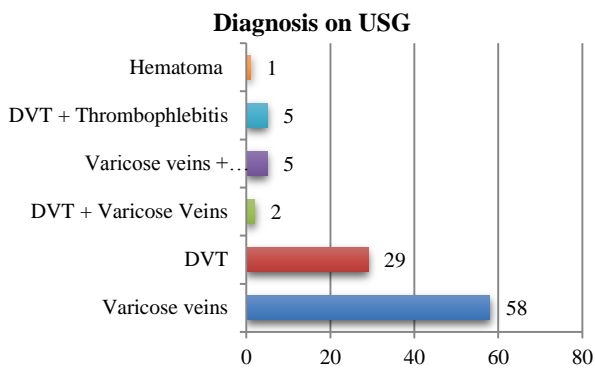


Figure 1: Distribution of various pathologies diagnosed on ultrasonography.

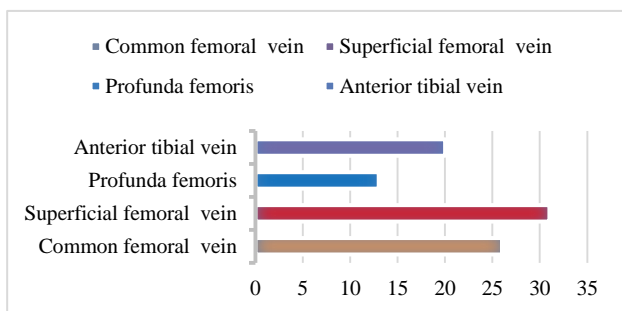


Figure 2: Veins involved in DVT.

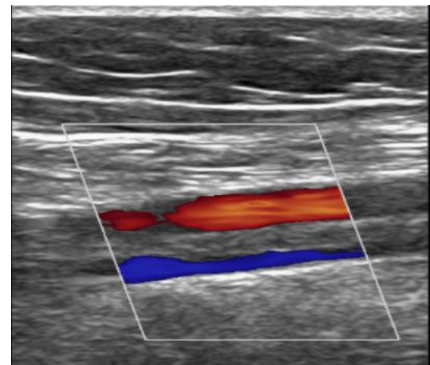


Figure 3: On colour Doppler partial thrombus in SFV (blue) normal SFA (red).

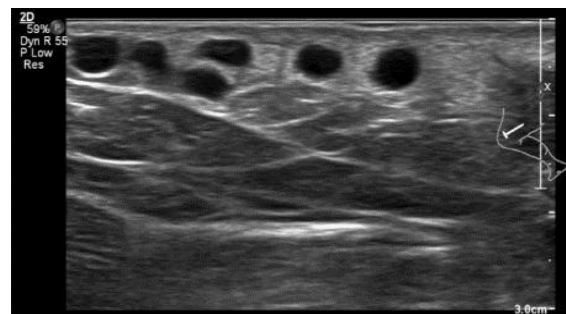


Figure 4: Varicosities along GSV in the medial aspect of thigh.

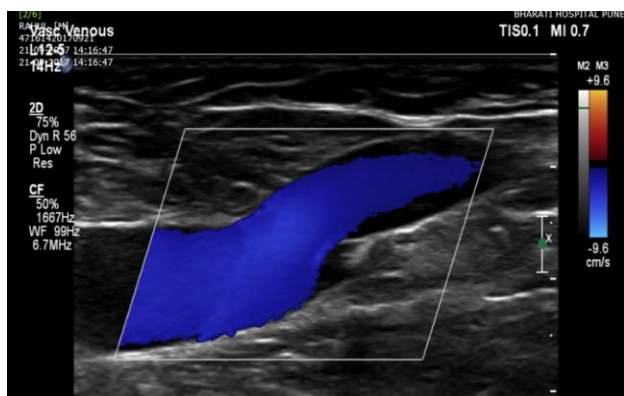

Figure 5A: SFJ on colour Doppler at rest.

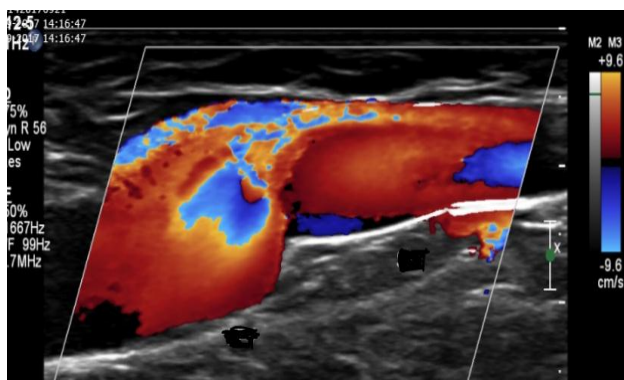


Figure 5B: SFJ on colour Doppler showing reflux on Valsalva.

DISCUSSION

Colour Doppler ultrasound helps to evaluate the myriad of conditions affecting the venous system of the lower limb. Common abnormalities involving the veins of lower limb are varicose veins, venous thrombosis, leg edema due to venous insufficiency, leg ulceration. The present study was performed to assess the role of colour Doppler ultrasound in evaluation of various conditions affecting the venous system of lower limbs. It included detection of DVT, extent of involvement, identification of varicose veins, junctional and perforator competence for effective management and intervention. The patients were then followed up over a span of one year. The Doppler findings were correlated with the surgical findings with a sensitivity of 100%.

Age group

A total of 100 patients of all ages were included in our study. The age group of 21-40 years (41 patients) was found to be the most common in our study. 33 patients were aged between 41-60 years and 23 between 61-80 years (Table 1). This correlates with the study carried out by Mirji et al in 2011 (n=32) who had 20 patients in the age group of 21-40 (62.5%).⁴ In our study 58% patients were above the age of 41 years. Belcaro et al in a study conducted in 2002 concluded that the prevalence of

chronic venous insufficiency increases with age.⁵ This is most likely to be due to loss of elasticity in vessels with increasing age.

Sex distribution

There was a definite male preponderance (65%) in our study (Table 1). This is in congruence with the research carried out by Azhar et al who reported 82% male patients and 18% female patients in their study.⁶ Male predominance in Indian population has been attributed to work habits especially prolonged standing in those involved in agriculture and in industrial work. A lesser female predilection in Indian demographics can be attributed to a lesser number of women seeking medical advice and a more sedentary lifestyle.

Clinical manifestation

Patients reported to the hospital with varied symptoms (Table 1). The most common symptom was pain with prominent veins seen in 44 patients, followed by pain and swelling in 37 patients, prominent veins with swelling in 12 patients, ulcer, eczema and pigmentation in 4 patients and eczema and pigmentation in 3 patients. This correlates with study done by Mirji et al where most patients (37.5 %) presented with pain and prominent veins followed by prominent veins and swelling in (31.25%).⁴

Venous pathologies

Isolated varicose veins (58%) accounted for maximum cases in our study followed by isolated DVT (29%). 5% patients had varicose veins and thrombophlebitis, another 5% had DVT with thrombophlebitis. 2% patients had both DVT and varicose veins. (Figure and Table 1). This is in harmony with study done by Azhar et al who out of 43 patients with chronic venous insufficiency reported 36 patients (83.7%) with varicose veins and the rest 7 had DVT.⁶

Predisposing factors

All patients with DVT and varicose veins were asked about their occupational, medical, surgical and family history to retrospectively elicit any predisposing factor.

In the 65 patients with varicose veins, 42 patients (64.6%) had an occupation involving prolonged standing, 8 patients (12.3%) had a family history of varicose veins. This correlates with study of Mirji et al where 81 % patients with varicose veins had an occupation involving prolonged standing and 25% patients had family history of varicose veins.⁴ Prolonged standing leads to venous stasis which in turn results in dilated tortuous veins. Hereditary involvement in varicose has also been suggested to be an additional causative factor for varicose veins.

In 36 patients with DVT, 19 (52.7 %) had a history of prolonged hospital stay (immobilization) and 9 (25%) had history of trauma while 4 had history of surgery.

Limb involvement

In our study left sided limb involvement was seen in 54% patients while right sided affection was seen in 35% patients. 11 % patients had bilateral limb involvement. This is in correlation with the study done by Irodi et al who reported 59 patients to have pathology on the left side while 41 on the right.⁷ Left sided predilection is attributed to the crossing over of the left common iliac vein by right common iliac artery leading to venous stasis.

Varicose vein distribution

Among the 65 patients with varicose veins, 31 (47.6%) patients had varicosities of great saphenous vein (GSV) alone, 30 patients had varicosities of both GSV and SSV (46.1%) and only 4 (0.6%) patients had varicosities involving Small saphenous vein (SSV) alone. (Figure 4) This corresponds with the study done by Azhar et al.⁶ In their study 58.5 % patients had GSV varicosities, 39 % varicosities involved the GSV and SSV and 2.1% had varicosities involving only SSV.

Junction incompetence

41 patients in our study had incompetent junctions-saphenofemoral, saphenopopliteal or both. Saphenofemoral junction (SFJ) was incompetent in 25 patients, Saphenopopliteal junction (SPJ) in 4 patients while 12 patients reported incompetence of SFJ and SPJ combined. (Figures 5 A and B). A similar study done by Bashir et al in which 41.7% patients had an incompetent SFJ and 11.12% patients had incompetent SPJ.⁸

Perforator incompetence and level

Of the 65 patients with varicose veins, 54 patients had perforator incompetence with most of them being multilevel. The most commonly involved incompetent perforator was located below knee medial mid 1/3rd (39 cases, 72%) and below knee medial lower 1/3rd (34 cases, 62.9%). Anterior incompetent perforator was least common (1 case, 1.8%). This is in conjunction with study done by Azhar et al where 69.5% cases had an incompetent perforator at below knee medial mid 1/3rd level and 67.4% patients had an incompetent perforator at below knee medial lower 1/3rd level.⁶

Thrombus distribution

Of the 36 patients with DVT, 31 patients had superficial femoral vein involvement followed by popliteal vein (27 patients) and common femoral vein (26 patients) (Figures 2 and 3).

This correlates with the study done by Hill et al who reported iliofemoral involvement in 16%, common femoral vein in 13%, superficial femoral vein in 19%, popliteal vein in 18%.⁹ Azhar et al also had similar findings with where among 43 patients suffering from chronic venous insufficiency (CVI), 8 of them had deep venous thrombosis with all of them having above knee thrombosis, and none of them having below knee thrombus.⁶

Recognition of thrombus in proximal limb is critical as it has more chances of causing pulmonary embolism. On the other hand, distal limb (calf) thrombosis has a better rate of recovery.

10 patients had superficial thrombosis involving the GSV out of which 5 patients had extension of thrombus into the deep system. In a study carried out by Blumenberg 38.8% cases had superficial vein thrombosis with 8.6% extending into the deep system.¹⁰

Follow up

Of the 65 patients with varicose veins 24 were operated. The Doppler findings correlated with surgical findings in all the cases. There was no recurrence in the immediate post-operative phase. Thus the sensitivity of Doppler in venous mapping was 100%. This corresponds with a similar study carried out by Dixon who reported a 98% sensitivity of index doppler examination and venous mapping prior to surgery in his study.¹¹ 7 patients with DVT underwent thrombectomy while 29 patients were treated with anticoagulants. The patients were followed up over a span of 1 year. A repeat colour Doppler ultrasonography was performed. 27 patients had partial recanalization.

Role of Doppler ultrasound

Colour Doppler ultrasound provides a better understanding of the venous anatomy of the lower limb and reaching the accurate diagnosis among the spectrum of venous abnormalities. Veins can be mapped along their entire course. It depicts the nature and level of incompetence and the prevalence of varicose veins. This aids the surgeon by pointing at the exact site of reflux, improving the success rate of surgery. It also helps in ruling out DVT.

CONCLUSION

Colour Doppler ultrasound is a safe, quick, cost-effective, universally available accurate and non-invasive modality for assessing the diseases affecting the venous system of lower limbs. Significant sensitivity and accuracy of this modality aids in evaluating the exact nature of venous pathology in a patient. Colour Doppler ultrasound depicts the type and level of incompetence, venous reflux, presence of varicose veins and superficial thrombosis. It helps in ruling out DVT which has significant morbidity

and can lead to life threatening complications like pulmonary embolism. Accurate venous mapping prior to the operative intervention aids the surgeon, increasing their success rate and providing a better quality of life to the patient. Thus, colour Doppler ultrasound is an indispensable tool in evaluation of the spectrum of venous abnormalities affecting the lower limb.

ACKNOWLEDGEMENTS

I extend my thanks to the teaching and non-teaching staff of our Department for their help and support in making this study possible. My heartfelt thanks to my parents, family and friends, for their unconditional love, sacrifice, inspiration and the support that keeps me going on the path of success.

Funding: No funding sources

Conflict of interest: None declared

Ethical approval: The study was approved by the Institutional Ethics Committee

REFERENCES

1. Kurz X, Kahn SR, Abenhaim L, Clement D. Chronic venous disorders of the leg: Epidemiology, outcomes, diagnosis and management: Summary of an evidence-based report on the VEINES task force. *Int Angiol.* 1999;18(2):83.
2. Cavezzi A, Labropoulos N, Partsch H, Ricci S, Caggiati A, Myers K, et al. Duplex ultrasound investigation of the veins in chronic venous disease of the lower limbs—UIP consensus document. Part II. Anatomy. *Europe J Vascul Endovasc Surg.* 2006;31(3):288-99.
3. Coleridge-Smith P, Labropoulos N, Partsch H, Myers K, Nicolaidis A, Cavezzi A. Duplex ultrasound investigation of the veins in chronic venous disease of the lower limbs—UIP consensus document. Part I. Basic principles. *Europ J Vascul Endovasc Surg.* 2006;31(1):83-92.
4. Mirji P, Emmi S, Joshi C. Study of clinical features and management of varicose veins of lower limb. *J Clin Diagn Res.* 2011;5(7):1416-20.
5. Cesarone MR, Belcaro G, Nicolaidis AN, Geroulakos G, Griffin M, Incandela L, et al. Real epidemiology of varicose veins and chronic venous diseases: the San Valentino Vascular Screening Project. *Angiology.* 2002;53(2):119-30.
6. Azhar MA. Role of Colour flow duplex sonography in evaluation of chronic venous insufficiency in lower limbs. *Radiology.* 2017;2(3):80-4.
7. Irodi A, Keshava SN, Agarwal S, Korah IP, Sadhu D. Ultrasound Doppler evaluation of the pattern of involvement of varicose veins in Indian patients. *Indian J Surg.* 2011;73(2):125-30.
8. Bashir J, Das K, Ahuja P, Arain MS. Clinical features and risk factors of varicose veins at Liaquat University Hospital Hyderabad. *Pak J Surg.* 2013;29(2):127-30.
9. Hill SL, Holtzman GI, Martin D, Evans P, Toler W, Goad K. The origin of lower extremity deep vein thrombi in acute venous thrombosis. *Am J Surg.* 1997;173(6):485-90.
10. Blumenberg RM, Barton E, Gelfand ML, Skudder P, Brennan J. Occult deep venous thrombosis complicating superficial thrombophlebitis. *J Vascul Surg.* 1998;27(2):338-43.
11. Dixon PM. Duplex ultrasound in the pre-operative assessment of varicose veins. *Austral Radiol.* 1996;40(4):416-21.

Cite this article as: Sharma D, Souza JD, Joshi P. Role of colour Doppler in evaluation of venous abnormalities of lower limb. *Int Surg J* 2020;7:163-7.