

Original Research Article

Laparoscopic total extraperitoneal mesh hernioplasty is a novel approach for inguinal hernia: our experience over 7 years

Dheer Singh Kalwaniya, Ranjith Mahadevan, Satya V. Arya, Jaspreet Singh Bajwa*,
Gowtham K. Gowda, Akshay Narayan, Vignesh M.

Department of General Surgery, Safdarjung Hospital, New Delhi, India

Received: 04 October 2019

Revised: 18 October 2019

Accepted: 19 October 2019

*Correspondence:

Dr. Jaspreet Singh Bajwa,

E-mail: jpsbajwa25@gmail.com

Copyright: © the author(s), publisher and licensee Medip Academy. This is an open-access article distributed under the terms of the Creative Commons Attribution Non-Commercial License, which permits unrestricted non-commercial use, distribution, and reproduction in any medium, provided the original work is properly cited.

ABSTRACT

Background: Inguinal hernia surgery is the most common performed surgery all over the world. Among them laparoscopic totally extra-peritoneal (TEP) mesh repair fulfils all the requirements with better clinical outcomes than other procedures.

Methods: Data was collected from the inpatient and out-patient records of 60 patients who underwent laparoscopic TEP for unilateral or bilateral inguinal hernia in a single unit in the Department of General Surgery during May 2012-June 2019 including the two years of follow-up. 3D mesh was used for application and was fixed with tackers. Then patients were followed up in outpatient department after 1 week, 2 week, and 3 months, 6 months and yearly up to two years. In every visit post-operative pain (assessed by visual analogue scale), local wound complication (hematoma, seroma, wound infection) and recurrence were noted. The data was collected and evaluated and the results shown.

Results: All patients were men, with average age of 36.5 years (range 32-58). On categorization 53 (88.3%) of them had unilateral inguinal hernia and 7 (11.6%) of them had bilateral inguinal hernia. Intra operatively 12 (20%) of them had direct inguinal hernia and 48 (80%) of them had indirect inguinal hernia. Haematoma was seen in 1 patients, surgical emphysema in 3, seroma in 5 and recurrence in 2 patients.

Conclusions: Laparoscopic TEP mesh repair was effective and safe tool for hernia repair, in terms of lesser postoperative painless number of hospital days, early recovery and lesser wound complications. However recurrence rates are comparable with other methods of hernia repair.

Keywords: TEP repair, Inguinal hernia (direct and indirect), Haematoma

INTRODUCTION

Inguinal hernia surgery is the most common performed surgery all over the world, requires thorough anatomical and physiological knowledge of groin region. In the present era of advanced medical care, everyone prefer the procedures which are minimally invasive, less painful, resulting better clinical outcome with good cosmesis. There is humpty number of surgeries in use, it reflects the complexity of inguinal hernia repair. Among them

laparoscopic TEP mesh repair fulfils all the requirements with better clinical outcomes than other procedures. Laparoscopic hernia repair was first reported by Ralp Ger and colleagues in 1982. Since then it has undergone revolutionary advances in technique of repair, types of meshes and various methods of mesh fixation.^{1,2} The basic pathophysiology of the posterior endoscopic approach is the use of large prosthetic mesh to cover the Fruchaud's myopectineal orifice in order to treat both direct and indirect as well as femoral hernia. In total

extraperitoneal (TEP), risk of bowel and vascular injury and post-operative adhesions are avoided since it is extra-peritoneal and it had lesser complications and early post-operative recovery.^{2,3} This study conducted in our hospital was to look for the efficacy and associated complications related with the procedure.

METHODS

Data was collected from the inpatient and out-patient records of 60 patients who underwent laparoscopic TEP for unilateral or bilateral inguinal hernia in a single unit in the Department of General Surgery, Safdarjung Hospital, New Delhi (India) during May 2012-June 2019 including the two years of follow-up. All the patients had clinically diagnosed inguinal hernia and were admitted day before surgery. After anesthetic clearance patients were operated by standard technique of TEP using 3D mesh in accordance with recommended guidelines.

Inclusion criteria

All patients with unilateral or bilateral uncomplicated reducible inguinal hernia.

Exclusion criteria

Irreducible hernia, complicated inguinal hernia, any previous history of infra umbilical surgery, chronic obstructive pulmonary disease, uncontrolled diabetes mellitus and ischemic heart disease were excluded.

Surgical procedure

Patient laid supine on operation theatre table after general anaesthesia. Operative parts were painted and draped. Through the infra-umbilical access, anterior rectus sheath opened and rectus muscle retracted then Hasson's cannula inserted into retro-rectal space, retro-rectal space was dissected by telescope till pubic symphysis in the midline (Figure 1). Two 5 mm port was inserted under vision then dissection was extended up to anterior-inferior iliac spine of the affected side, after identification of the type of hernia, by using non toothed grasper hernia contents were reduced and hernial sac was dissected and ligated if needed. 3D mesh was placed in the pre-peritoneal space and fixed by absorbable vicryl tackers (Figure 2 and 3), after achieving complete hemostasis, sheath closed by vycryl-1 and skin closed by using nylon 3-0 and aseptic dressing applied.

Post operatively patients were shifted to general ward. Post-operative parenteral analgesics given. Early mobilization and enteral feeding was encouraged and discharged as soon as possible. Then patients were followed up in outpatient department after 1 week, 2 week, and 3 months, 6 months and yearly up to two years.

In every visit following parameters were noted.

- Post-operative pain [assessed by visual analogue scale (VAS)].
- Local wound complication (hematoma, seroma, wound infection).
- Recurrence.

All the data was collected and was tabulated using SPSS 17 software and the results are shown.

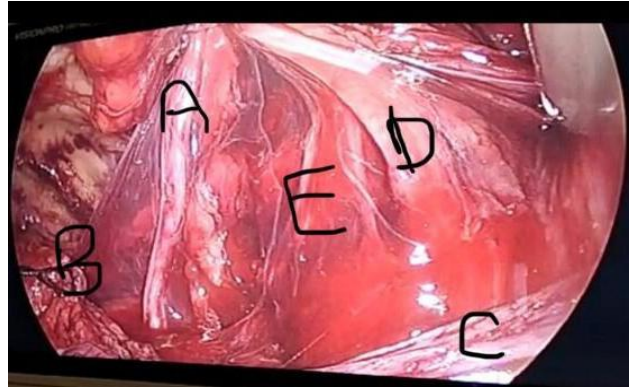


Figure 1: Post dissection view of TEP (A): Vas deferens; (B): Ligated sac; (C): Reflected peritoneal fold; (D): Cord structures with testicular vessels and (E): External iliac vessels.

Triangle of doom is formed by (A): Lateral boundary, (D): Lateral boundary and (C): Inferior boundary. Contents are formed by E.

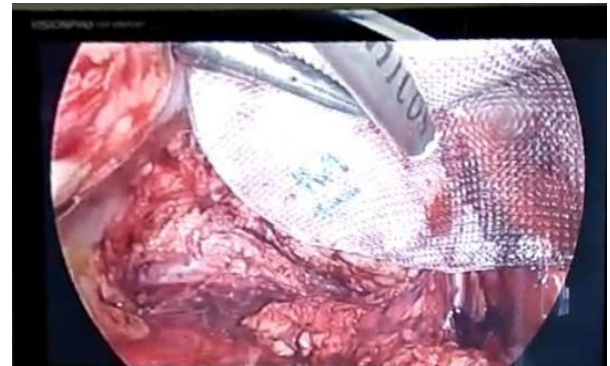

Figure 2: Mesh placement (3D mesh) with medial fixation over pubic tubercle.



Figure 3: Post mesh fixation view (both medial and lateral fixation done).

Data analyzed was expressed in average, percentage, mean±SD (range).

RESULTS

A total of 60 patients operated during 2012-2019, all patients were men, with average age of 36.5 years (range 32-58).

On categorization 53 (88.3%) of them had unilateral inguinal hernia and 7 (11.6%) of them had bilateral inguinal hernia. Intra operatively 12 (20%) of them had direct inguinal hernia and 48 (80%) of them had indirect inguinal hernia.

The study shows that out of 60 patients, only two had recurrence and rest patients had complications which were managed conservatively.

Table 1: Basic patient characteristics.

Patient characteristics	N (%)
Age	36.5 years (Range 32-58)
Side of hernia	
Unilateral	53 (88.3)
Bilateral	7 (11.6)
Type of hernia	
Direct	12 (20)
Indirect	48 (80)
Femoral	0

Table 2: Intra-op and post-op complications.

Complications	No.	%
Intra-operative complications (vascular injury, visceral injury nerve injury)	None	-
Post-operative pain		
VAS<3	56	94
VAS>3	4	6
Surgical emphysema	3	5
No. of days of hospital stay	2-4 days	2.4 days (average)
Seroma	5	8.3
Hematoma	1	1.6
Surgical site infection	0	-
Recurrence	2	3.3

DISCUSSION

Laparoscopic hernia repair by TEP approach had several advantages than open surgery as shown by various prospective randomized controlled trials. The major advantages include less post-operative pain, early recovery, and better cosmetic results. It is technically demanding procedure with long learning curve.

In our study, we didn't encounter any intra-operative complications, however some authors experienced intra-operative bladder injury (0-2%) especially in previous suprapubic surgery, and bowel injury (0-0.3%) cases.² These injuries can be avoided by better surgical expertise and sound anatomical knowledge of inguinal region.

In the subgroup analysis of pain, majority of the patients (94%) experienced <3 VAS score, however 4 patients (6%) developed severe post-operative pain VAS>3 which is attributed to increase use of tackers for mesh fixation. With the advent of 3D mesh, now a days with minimal mesh fixation post-operative pain was significantly reduced. These results are correlating with the studies conducted by Neumayer et al and Carter et al.^{3,4}

In our study we experienced, post-operative surgical emphysema in three patients (5%) which was managed conservatively. Similar cases were reported who developed surgical emphysema with hypercarbia during

TEP by Singh et al.⁵ It can be avoided by using sharp trocars to minimize false passages and Co₂ insufflation pressure should be kept low as is possible without compromising the ease of operation.

On evaluation of the post-operative hospital stay, average hospital stay was 2.4 days (range 2-4 days). The shorter hospital stay was found to be because of less post-operative pain and early ambulation. In the study conducted by Choi et al, mean hospital stay was 1.6 days.⁶ Mean hospital stay was higher in our study this is due to the fact that discharges decided not only by the patients physical condition but surgeon's preference psychological benefits and traditional beliefs.

Table 3: Recurrence rates of various studies.

Studies	Recurrence rate (%)
Shaikh et al ⁸	1.4
Wright et al ⁹	2
Pattar et al ¹⁰	2.4
Neumayer et al ³	10.1
Leim et al ¹¹	3
Aeberhard et al ¹²	1.6

In our study, only 5 patients (8.3%) developed seroma, which was managed conservatively. Only one patient developed hematoma. None of our patients developed

surgical site infection. These results are comparable with previous documented studies.

The best outcome factor for any hernia repair is recurrence. In our study, we experienced only 2 (3.33%) recurrence which's was comparable with other studies. Recurrence percentage of various studies is tabulated below.⁷

CONCLUSION

Laparoscopic TEP mesh repair was effective and safe tool for hernia repair, in terms of lesser postoperative painless number of hospital days, early recovery, and lesser wound complications. However recurrence rates are comparable with other methods of hernia repair. But it needs long learning curve to get expertise and excel in the field of hernia repair. Single site incision for bilateral inguinal hernia is a big factor for favorable outcomes in terms of pain and cosmesis.

Funding: No funding sources

Conflict of interest: None declared

Ethical approval: The study was approved by the Institutional Ethics Committee

REFERENCES

1. Ger R. The Management of certain abdominal hernia by intra-abdominal closure of neck. Ann R Coll Surg Engl. 1982;64:342-4.
2. Tamme C, Scheidbach H, Hampe C. Totally extraperitoneal endoscopic inguinal hernia repair (TEP). Surg Endosc. 2003;17:190-5.
3. Neumayer L, Giobbie-Hurder A, Jonasson O, Fitzgibbons R, Dunlop D, Gibbs J, et al. Open mesh versus laparoscopic mesh repair of inguinal hernia. New England J Med. 2004;350(18):1819-27.
4. Carter J, Duh QY. Laparoscopic repair of inguinal hernias. World J Surg. 2011;35:1519-25.
5. Singh K, Singhal A, Saggar V, Sharma B, Sarangi R. Subcutaneous carbon dioxide emphysema following endoscopic extraperitoneal hernia repair: possible mechanisms. J Laparoendoscopic Advan Surg Techniques. 2004;14(5):317-20.
6. Choi YY, Han SW, Bae SH, Kim SY, Hur KY, Kang GH. Comparison of the outcomes between laparoscopic totally extra peritoneal repair and prolene hernia system for inguinal hernia; review of one surgeon's experience. J Korean Surg Soc. 2012;82(1):40-4.
7. Chauhan HR, Chheda H. A study of laparoscopic total extraperitoneal endoscopic hernioplasty in cases of inguinal hernia-an experience of a tertiary care centre. Int Surg J. 2016;3:643-8.
8. Shaikh AG, Soomoro MI, Shaik MS, Memon AA. Outcome of totally extra-peritoneal laparoscopic hernioplasty at a tertiary care hospital Larkana J Pak Med Assoc. 2013;63(7):850-3.
9. Wright D, Paterson C, Scott N, Hair A, Patrick J, O'dwyer PJ. Five year follow up of patients undergoing laparoscopic or open groin hernia repair. Ann Surg. 2000;235(3):333-7.
10. Pattar, Kattapura JD, Duffield S, Robert GM. Laparoscopic totally extra peritoneal inguinal hernia repair: a personal experience and learning curve. Indian J Surg. 2007;69(3):90-4.
11. Leim MSL, Graaf YVD, Steensel CJV, Boelhouwer RU, Clevers GJ, Meijer WS, et al. Comparison of conventional anterior surgery and laparoscopic surgery for inguinal hernia repair. N Engl J Med. 1997;336:1541-7.
12. Aeberhard P, Klaiber C, Meyenberg A, Osterwalder A, Tschudi J. Prospective audit of laparoscopic totally extra peritoneal inguinal hernia repair: a multicenter study of the Swiss Association for laparoscopic and thoracoscopic surgery (SALTC). Surg Endosc. 1993;13(11):1115-20.

Cite this article as: Kalwaniya DS, Mahadevan R, Arya SV, Bajwa JS, Gowda GK, Narayan A, et al. Laparoscopic total extraperitoneal mesh hernioplasty is a novel approach for inguinal hernia: our experience over 7 years. Int Surg J 2019;6:3982-5.